

Penile prosthesis implant for primary erectile dysfunction in patient with Klippel-Trenaunay syndrome complicated by consumptive coagulopathy

A case report

Carlo Bettocchi, MD*, Marco Spilotros, MD, Giuseppe Lucarelli, MD, PhD, Emanuele Utano, MD, Francesco Sebastiani, MD, Lukas Bittner, MD, Pasquale Ditunno, MD, Michele Battaglia, MD

Abstract

Rationale: Klippel-Trenaunay syndrome (KTS) is a congenital disorder characterized by cutaneous port wine capillary malformations, varicose veins with hemihypertrophy of soft tissue and bone.

Pelvic and retroperitoneal vascular malformations have been described up to the 30% of patients with KTS while hemangiomas of the urinary tract have been reported in 6%

Patient concerns: A 30-year-old man with KTS was referred to our center for primary erectile dysfunction (ED) associated with varicosities of unusual distribution and asymmetry of the lower limbs. Furthermore, he suffered from hypertension and autosomal dominant polycystic kidney disease.

During penile prosthesis implantation, a significant intraoperative bleeding (1 liter) due to large scrotal venous malformations and profuse bleeding from both corpora was recorded. One month later, the day after the first prosthesis training session, the patient returned with swelling in the penoscrotal region. A large inguino-scrotal hematoma was drained. There was a complete bilateral dehiscence of corpora cavernosa with a spread venous bleeding in the scrotum.

Diagnoses: CT scan showed hypertrophy of the right hypogastric artery with severe vascular malformations: the right pudendal artery was massively dilated with early visualization of venous drainage without evidence of arteriovenous fistulae; regular bulbocavernosus capillary blush; right upper gluteus artery hypertrophic and dilated. Multiple twisting and aneurysms of the right internal pudenda artery were bleeding from multiple points. Cystoscopy showed a fistula between the proximal urethra and the penoscrotal dartos. Coagulation tests revealed the presence of factor XIII deficiency

Interventions: The patient underwent several procedures including percutaneous scleroembolization of the internal pudendal arteries, removal of the penile implant, recombinant factor XIII (FXIII) administration, and cord blood platelet gel application.

Outcomes: The patient was discharged after almost 3 months in hospital, hemodynamically stable.

Lessons: Experience regarding management of ED in KTS patient is limited and in case of concomitant factor XIII deficiency, the clinical scenario can be life-threatening. A multidisciplinary approach including a urologist, an interventional radiologist and a hematologist in our experience represented the key approach in case of severe bleeding following surgery for ED.

Abbreviations: CBPG = cord blood platelet gel, ED = erectile dysfunction, FXIII = factor XIII, KTS = Klippel-Trenaunay syndrome.

Keywords: Klippel-Trenaunay syndrome, erectile dysfunction, penile prosthesis, consumptive coagulopathy

Editor: N/A.

Informed written consent was obtained from the patient for publication of this case report and accompanying images.

The authors have no conflicts of interest to disclose.

Department of Emergency and Organ Transplantation, Urology, Andrology and Kidney Transplantation Unit, University of Bari, Bari, Italy.

* Correspondence: Carlo Bettocchi, Department of Emergency and Organ Transplantation, Urology, Andrology and Kidney Transplantation Unit, Piazza G. Cesare 11, 70124 Bari, Italy (e-mail: carlo.bettocchi@uniba.it).

Copyright © 2019 the Author(s). Published by Wolters Kluwer Health, Inc. This is an open access article distributed under the terms of the Creative Commons Attribution-Non Commercial-No Derivatives License 4.0 (CCBY-NC-ND), where it is permissible to download and share the work provided it is properly cited. The work cannot be changed in any way or used commercially without permission from the journal.

Medicine (2019) 98:32(e16741)

Received: 29 March 2019 / Received in final form: 1 June 2019 / Accepted: 15 July 2019

<http://dx.doi.org/10.1097/MD.00000000000016741>

1. Introduction

Erectile dysfunction (ED) secondary to an abnormal veno-occlusive mechanism is the most common cause of ED. Venogenic ED is represented by the loss of an adequate venous blood storage in the penis during erection secondary to venous leakage^[1]. Klippel-Trenaunay syndrome (KTS) is a congenital disorder characterized by cutaneous port wine capillary malformations, varicose veins with hemihypertrophy of soft tissue and bone. It is a rare vascular condition with an incidence of 1 in 30,000: the 75% of patients develop symptoms before 10 years of age^[2,3]. Abnormalities of mesodermal tissue are considered to be responsible of altered angiogenesis during embryologic development with different clinical scenarios: 63% of patients affected will present with all the features while the 37% will develop only 2 aspects of the disease^[4]. From a urological point of view, pelvic and retroperitoneal vascular

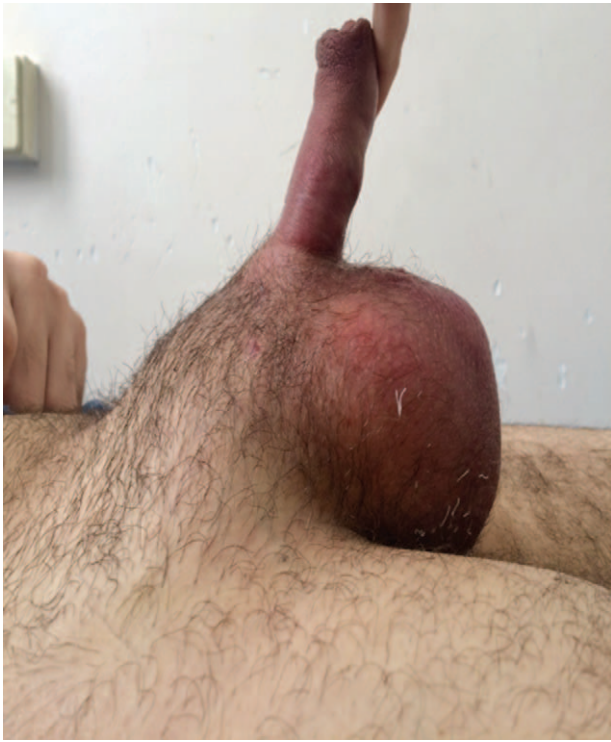

Figure 1. Large inguino-scrotal hematoma.

malformations have been described up to the 30% of patients with KTS while hemangiomas of the urinary tract have been reported in 6%^[2]. In patients with KTS and genito-urinary bleeding from a vascular abnormality, a conservative management is initially recommended while in case of intractable bleeding open surgical resection with partial or complete excision of the involved organ is advocated^[3].

2. Case report

A 30-year-old man was referred to our hospital for primary ED associated with varicosities of unusual distribution and asymmetry of the lower limbs. He was affected by Klippel-Trenaunay syndrome. Furthermore, he suffered from hypertension and autosomal dominant polycystic kidney disease. After an assessment of the first level coagulation blood tests (prothrombin time [PT]: 1.13 sec; international normalized ratio [PT-INR]: 1.21; activated partial thromboplastin time [APTT]: 1.10 sec; thrombin time [TT]: 1.01 sec), there were no contraindications for surgery as per hematologist suggestion.

The patient developed mild postoperative peno-scrotal hematoma. A CT scan of abdomen and pelvis did not show active bleeding. We opted for a conservative management with blood transfusions (4U) and compressive medication. It was successful, and the patient was discharged 8 days after surgery in good condition (last blood exams: RBC $3.25 \times 10^6/\mu\text{L}$; WBC $6.06 \times 10^3/\mu\text{L}$; Hb 9.9 g/dL-in growing -; PLT $186 \times 10^3/\mu\text{L}$; HCT 28.5%).

One month later, the day after the first prosthesis training session, the patient returned with swelling in the penoscrotal region (Fig. 1). He was admitted to hospital for further monitoring. Blood exams showed anemia (Hb: 8.5 g/dL).

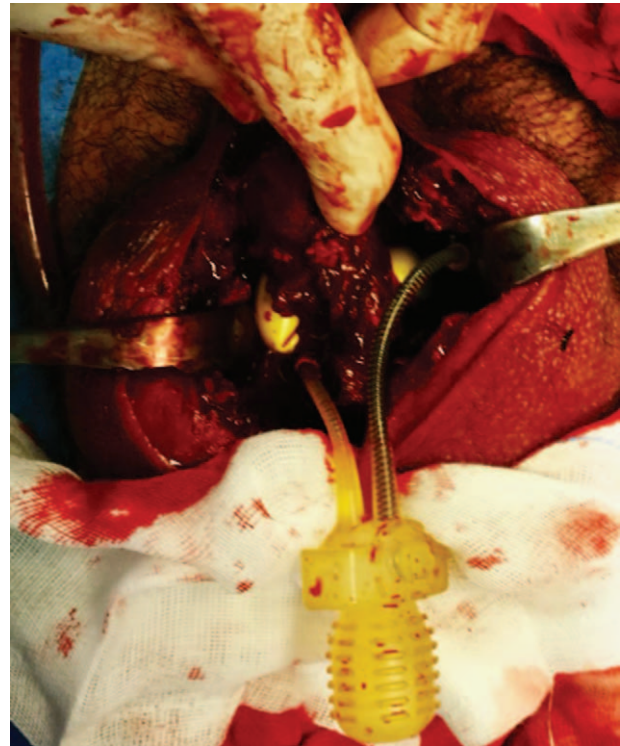


Figure 2. Complete bilateral dehiscence of the sutures of the corpora cavernosa.

Conservative management with compressive medication was the initial treatment; however, painful swelling returned on the 5th-day post-admission, so revision surgery was deemed necessary. A large inguino-scrotal hematoma was drained. There was a complete bilateral dehiscence of corpora cavernosa with a spread venous bleeding in the scrotum (Fig. 2). A meticulous hemostasis of the whole area was performed without active bleeding documented at the end of the procedure. Both cylinders were repositioned and the corpora cavernosa were closed with heterologous graft to reduce the pressure into the corporas and the risk of further erosion (Fig. 3). There was no evidence of infection at this stage. On the first postoperative day, a CT scan was performed due to the recurrence of inguino-scrotal pain and swelling with profuse bleeding around the exit of the scrotal drain. Imaging showed hypertrophy of the right hypogastric artery with severe vascular malformations: the right pudendal artery was massively dilated with early visualization of venous drainage without evidence of arteriovenous fistulae; regular bulbocavernous capillary blush; right upper gluteus artery hypertrophic and dilated. Multiple twisting and aneurysms of the right internal pudenda artery were bleeding from multiple points. The patient received a blood transfusion (2U) due to anemia (Hb 7.5 g/dL) and underwent to percutaneous scleroembolization of the right internal pudendal artery to stop the bleeding. Seven hours later, massive bleeding persisted from both drains (200 mL) and surgical wound (Hb 8.0 g/dL after transfusion and scleroembolization). Further emergency revision was required at this stage.

The penile implant and the corporal graft were removed. More than 2.5 hours were necessary to achieve a complete hemostasis of the surgical site. Corporotomies were sutured with Prolene 3/0 stitches and sealed with a hemostatic matrix (TachoSil: Human

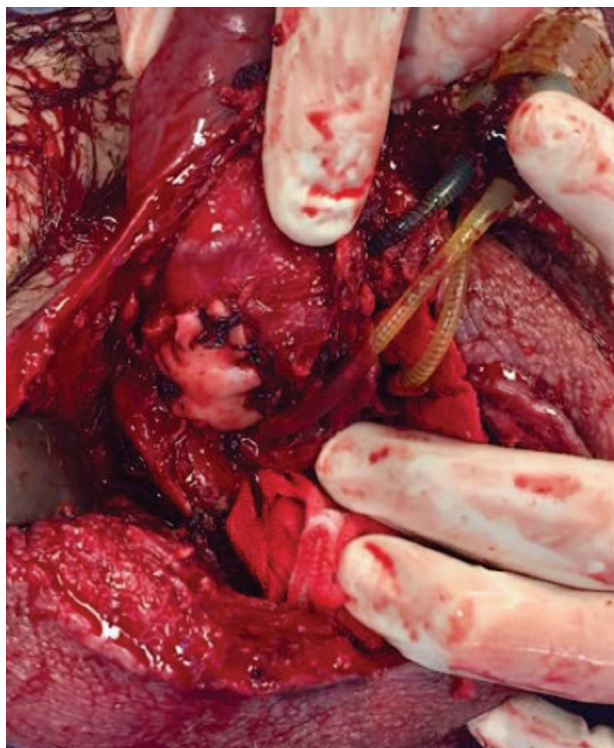


Figure 3. Closure of the corpora cavernosa with heterologous graft.

Fibrinogen+ Thrombin). The scrotal incision was sutured with Vicryl 3/0. After 2 days wound bleeding apparently stopped, so both drains were removed and Hb remained stable (9.5 g/dL). The following day, hemoglobin level continued to drop without any signs of bleeding, so second level coagulation blood tests were required despite the fact that the first level was normal (PT, APTT, and TT): factor XIII (FXIII), vWF, clotting time, specific inhibitors for suspected acquired coagulopathy. Bleeding from the wound and urethra started again 3 days after the removal of penile implant and scleroembolization of the right pudendal artery. Continuous bladder irrigation was required and urethral and cystoscopic inspection was performed. We observed a fistula between the proximal urethra and the penoscrotal dartos (Fig. 4); neither a urethral stenosis nor a bladder lesion were evident (only slight bleeding from the bladder neck due to catheterisation).

Anemia and bleeding began to worsen despite the administration of fresh frozen plasma and blood transfusions. After a couple of days, coagulation tests revealed the presence of factor XIII deficiency (= 17%), also known as the “fibrin-stabilizing factor,” which plays a crucial role in clotting cascade and wound healing so we administrated human-FXIII^[5].

Despite this treatment, the patient showed little improvement and persistent anemia (Hb 7.0 g/dL) due to recurrent scrotal and urethral bleeding; the wound dressing had to be rewrapped once every 2 hours, and the patient required blood transfusions. Another contrast-enhanced CT scan was necessary to exclude a new source of bleeding. The scan indicated a dysplastic left internal pudendal artery and hypervascularization of the bulbocavernous scrotal area on both sides through abnormal collateral circulations. A percutaneous scleroembolization of the left internal pudendal artery was performed to reduce the blood supply to the scrotal area and related bleeding.

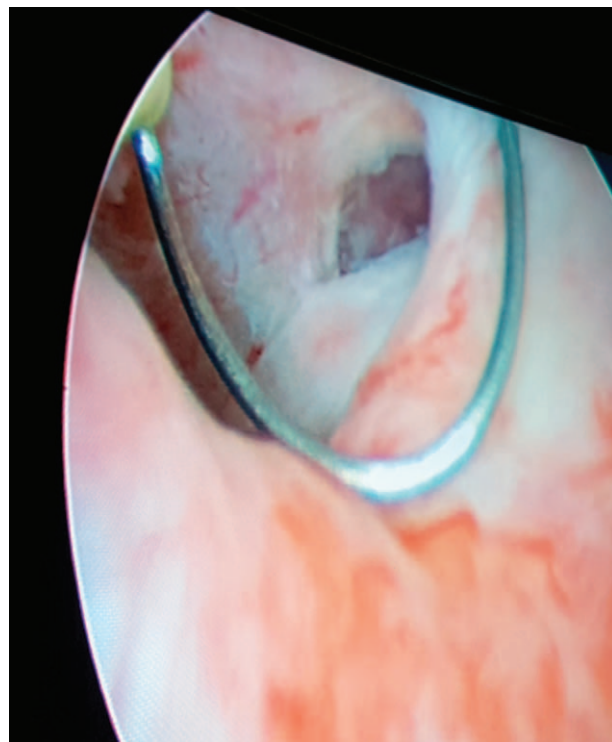


Figure 4. Fistula between the proximal urethra and the penoscrotal dartos.

Since all the attempts to stop the bleeding were unsuccessful, a new experimental approach was proposed. We applied the cord blood platelet gel (CBPG) to the scrotal wound and also endoscopically in the urethra to close the bleeding fistula. CBPG has been widely used in the treatment of diabetic ulcers with excellent results^[6].

This approach improved the situation: the bleeding stopped, urine became clear less than 24 hours after the endoscopic procedure, and hemoglobin increased. The patient was sent home 2 weeks later, after almost 3 months in hospital. He was discharged with a Foley catheter 18 Ch/3 ways and the catheter has not been removed yet. He is currently awaiting a urethroplasty to correct the urethral fistula.

The patient has provided informed consent for publication of the case.

3. Discussion

The implantation of penile prosthesis is the third-line therapy for ED and treatment of choice in cases of severe ED^[7]. This surgery is a valid therapeutic alternative, emphasized by the high rate of patients and partner's satisfaction emerged in literature^[8]. The implantation is a safe procedure with low complication rate, especially in high volume centers. Despite that, it is necessary to identify potential risks^[9].

ED in men with Klippel-Trenaunay syndrome may be due to venous drainage anomalies caused by vascular malformations of the lower abdomen and external genitalia, as well as an abnormality of the veno-occlusive mechanism of the erection^[10]. Congenital FXIII deficiency is a rare hereditary bleeding disorder estimated to affect between 1 in 1 million and 1 in 5 million live births, and it occurs more frequently in consanguineous families

^[5]. It has already been described association of FXIII deficiency and Klippel-Trenaunay Syndrome at least in 1 case^[11].

Combination of KTS and FXIII deficiency can be a serious condition leading to intraoperative and postoperative bleeding that could be difficult to manage. Treatment in patients with KTS complaining of ED is based initially on oral and intracorporeal injectable agents. If these trials failed, MRI of the perineum and pelvis, followed by cavernosography to assess pelvic and perineal vascular anomalies and venous leakage should be considered. If a limited number of veins are discovered, surgical ligation of the abnormal penile veins is an option^[3]. If venous ligation fails or is not feasible, a 3-piece inflatable penile prosthesis implant should be considered when penis growth and length are not compatible with satisfactory penetration. There is a limited experience on ED treatment in patients with KTS syndrome. Husmann et al^[3] demonstrated a venous leakage phenomenon in all their patients with KTS and ED. The authors reported no response to pharmacological agents and significant blood loss with multiple postoperative complications followed by a temporary benefit in the single patient who underwent to venous ligation. A satisfactory outcome following venous ligation has been reported by Agrawal et al^[10], who reported return of spontaneous erections in 3 patients with KTS but in this series it is not clarified the amount of venous leakage and a clear comparison with Husmann's experience cannot be made. A complete radiographic evaluation in men with KTS who have ED is recommended if venous ligation is considered in order to exclude a large venous leakage potentially unresponsive to this approach.

In terms of prevention of complications, the preoperative study in our patient was misleading because of the absence of consanguinity and previous bleeding tendency and for the absence of abnormalities in the first level coagulation screen. Genetic tests performed at a later stage showed the absence of a congenital deficiency, but it is possible that the FXIII deficiency was postoperatively acquired: around 45% of KTS cases could be complicated by consumption coagulopathy such as Kasabach-Merritt syndrome. Large arterio-venous malformations can sequester the platelets, preventing proper hemostasis, especially in the surgical area^[12,13].

In our patients further investigation disclosed that KTS caused spontaneous venous thrombosis and it has been already documented in previous series up to 50% of KTS patients^[14,15]. Our first approach has been conservative but when significant bleeding was observed we opted for a scleroembolization of the left internal iliac artery that unfortunately did not provide a successful outcome and for this reason revision surgery was deemed necessary multiple time. As shown in previous case reports if intractable bleeding develops open surgical resection is the best choice over less invasive approaches due to the increased risk of exsanguination^[16].

Concomitant FXIII deficiency is an extremely rare condition that causes significant abnormalities in coagulation process due to an abnormal fibrin stabilization involved in clot preservation. Congenital FXIII deficiency has been reported in patients with KTS. In our patient we demonstrated the absence of abnormalities in the first level coagulation screen that could point to a congenital condition; furthermore, genetic tests performed during hospitalization excluded such a situation. For this reason, supported by our hematology team, we concluded that the FXIII deficiency observed at a later stage in our patient could be related to a consumption coagulopathy related to the consistent bleeding.

FXIII has also a role in wound repair and healing. Combination of KTS and FXIII deficiency represent an explanation for the clinical scenario observed in our patient.

Replacement therapy for FXIII deficiency can be provided through fresh frozen plasma (preferably virus-inactivated) in doses of 10 mL/kg at 4 to 6 week intervals, cryoprecipitate provided in doses of 1 bag per 10 to 20 kg of bodyweight every 3 to 4 weeks, and pasteurized FXIII concentrates (about 240 units/vial). Virus-inactivated fresh-frozen plasma (FFP) and particularly pasteurized concentrates are the most preferred among these agents. The first FXIII from a human source that was used in replacement therapy was produced from placenta (Fibrogammin HS); however, this product was later replaced by plasma extracted FXIII concentrates [Fibrogammin P (CSL Behring, Marburg, Germany) and FXIII-BLP (Bio-Product Laboratory, Elstree, United Kingdom)]. In addition, recombinant FXIII (Novo Nordisk, Bagsvaerd, Denmark) is currently available for use in the treatment of similar cases^[17].

4. Conclusions

Experience regarding management of ED in KTS patient is limited and in case of concomitant factor XIII deficiency the clinical scenario can be life-threatening as demonstrated by this case report. A multidisciplinary approach including a urologist, an interventional radiologist and a hematologist in our experience represented the key approach in case of severe bleeding following surgery for ED.

Author contributions

Conceptualization: Carlo Bettocchi.

Data curation: Marco Spilotros, Emanuele Utano, Francesco Sebastiani, Lukas Bittner, Pasquale Ditunno, Michele Battaglia.

Investigation: Carlo Bettocchi, Marco Spilotros, Giuseppe Lucarelli, Francesco Sebastiani, Lukas Bittner, Pasquale Ditunno, Michele Battaglia.

Methodology: Marco Spilotros, Emanuele Utano, Francesco Sebastiani.

Resources: Emanuele Utano.

Supervision: Carlo Bettocchi, Michele Battaglia.

Writing – original draft: Carlo Bettocchi, Marco Spilotros.

Writing – review & editing: Giuseppe Lucarelli, Pasquale Ditunno.

References

- [1] Shafik A, Shafik I, El Sibai O, et al. On the pathogenesis of penile venous leakage: role of the tunica albuginea. *BMC Urol* 2007;7:1–7.
- [2] Furness PDIII, Barqawi AZ, Bisignani G, et al. Klippel-Trenaunay syndrome: 2 case reports and a review of genitourinary manifestations. *J Urol* 2001;166:1418–20.
- [3] Husmann DA, Rathburn SR, Driscoll DJ. Klippel-Trenaunay syndrome: incidence and treatment of genitourinary sequelae. *J Urol* 2007;177:1244–9.
- [4] Kocaman O, Alponat A, Aygun C, et al. Lower gastrointestinal bleeding, hematuria and splenic hemangiomas in Klippel-Trenaunay syndrome: a case report and literature review. *Turk J Gastroenterol* 2009;20:62–6.
- [5] Solomon C, Korte W, Fries D, et al. Safety of factor XIII Concentrate: analysis of more than 20 years of pharmacovigilance data. *Transfus Med Hemother* 2016;43:365–73.
- [6] Tadini G, Guez S, Pezzani L, et al. Preliminary evaluation of cord blood platelet gel for the treatment of skin lesions in children with dystrophic epidermolysis bullosa. *Blood Transfus* 2015;13:153–8.

- [7] Bettocchi C, Palumbo F, Spilotros M, et al. Penile prostheses. *Ther Adv Urol* 2010;2:35–40.
- [8] Bettocchi C, Palumbo F, Spilotros M, et al. Patient and partner satisfaction after AMS inflatable penile prosthesis implant. *J Sex Med* 2010;7:304–9.
- [9] Bettocchi C, Ditunno P, Palumbo F, et al. Penile prosthesis: what should we do about complications? *Adv Urol* 2008;573560:1–5.
- [10] Agrawal V, Minhas S, Ralph DJ. Venogenic erectile dysfunction in Klippel-Trenaunay syndrome. *BJU Int* 2006;97:327–8.
- [11] Endo Y, Takahashi K, Mamiya S, et al. Factor XIII deficiency associated with Klippel-Weber disease, platelet dysfunction and cryofibrinogenemia. *Acta haematologica* 1983;69:398–403. 6.
- [12] Endo Y, Takahashi K, Mamiya S, et al. Factor XIII deficiency associated with KTS. *Acta haematologica* 1983;69: 398-403.
- [13] Bhat L, Bisht S, Khanijo K, et al. Klippel Trenaunay Weber syndrome with Kasabach Merritt coagulopathy and hydronephrosis. *Indian Pediatrics* 2015.
- [14] Jacob AG, Driscoll DJ, Shaughnessy WJ, et al. Klippel-Trenaunay syndrome: spectrum and management. *Mayo Clin Proc* 1998;73:28–36.
- [15] Baskerville PA, Ackroyd JS, Browse NL. The etiology of Klippel-Trenaunay syndrome. *Ann Surg* 1985;202:624–7.
- [16] Furness PD3rd, Barqawi AZ, Bisignani G, et al. Klippel-Trenaunay syndrome: 2 case reports and a review of the literature. *J Urol* 2001;166:1418.
- [17] Naderi M, Dorgalaleh A, Tabibian Sh, et al. Current understanding in diagnosis and management of factor XIII deficiency. *Iran J Ped Hematol Oncol* 2013;3:164–72.