

# A national survey on prevalence of possible echocardiographic red flags of amyloid cardiomyopathy in consecutive patients undergoing routine echocardiography: study design and patients characterization — the first insight from the AC-TIVE Study

Marco Merlo <sup>1\*†</sup>, Aldostefano Porcari <sup>1†</sup>, Linda Pagura<sup>1</sup>, Matteo Cameli <sup>2</sup>, Giuseppe Vergaro<sup>3</sup>, Beatrice Musumeci <sup>4</sup>, Elena Biagini <sup>5</sup>, Marco Canepa <sup>6</sup>, Lia Crotti <sup>7,8</sup>, Massimo Imazio <sup>9</sup>, Cinzia Forleo<sup>10</sup>, Francesco Cappelli <sup>11</sup>, Stefano Favale<sup>10</sup>, Gianluca Di Bella<sup>12</sup>, Franca Dore<sup>13</sup>, Carlo Mario Lombardi<sup>14</sup>, Rita Pavasini<sup>15</sup>, Valeria Rella<sup>7</sup>, Giuseppe Palmiero<sup>16</sup>, Martina Caiazza<sup>16</sup>, Miriam Albanese<sup>10</sup>, Andrea Igoren Guaricci<sup>10</sup>, Giovanna Branzi<sup>7</sup>, Angelo Giuseppe Caponetti<sup>5</sup>, Giulia Saturi<sup>5</sup>, Giovanni La Malfa<sup>6</sup>, Andrea Carlo Merlo<sup>6</sup>, Alessandro Andreis<sup>9</sup>, Francesco Bruno <sup>9</sup>, Francesca Longo<sup>1</sup>, Enrico Sfriso<sup>1</sup>, Luca Di Lenno<sup>15</sup>, Giuseppe De Carli<sup>2</sup>, Elisa Giacomini<sup>2</sup>, Valentina Spini<sup>3</sup>, Antonino Milidoni<sup>14</sup>, Giuseppe Limongelli <sup>16</sup>, Camillo Autore<sup>4</sup>, Iacopo Olivetto <sup>11</sup>, Luigi Badano<sup>7,8</sup>, Gianfranco Parati <sup>7,8</sup>, Stefano Perlini <sup>17,18</sup>, Marco Metra <sup>14</sup>, Michele Emdin <sup>3</sup>, Claudio Rapezzi <sup>19,20‡</sup>, and Gianfranco Sinagra <sup>1‡</sup>

<sup>1</sup>Cardiovascular Department, Center for Diagnosis and Treatment of Cardiomyopathies, Azienda Sanitaria Universitaria Giuliano-Isontina (ASUGI) and University of Trieste, Via Valdoni 1, 34149 Trieste, Italy; <sup>2</sup>Division of Cardiology, Department of Medical Biotechnologies, University of Siena, Viale Mario Bracci 16, 53100, Siena, Italy; <sup>3</sup>Division of Cardiology and Cardiovascular Medicine, Fondazione Toscana Gabriele Monasterio and Istituto di Scienze della Vita, Scuola Superiore Sant'Anna, Via Giuseppe Moruzzi 1, 56124, Pisa, Italy; <sup>4</sup>Department of Clinical and Molecular Medicine, Faculty of Medicine and Psychology, Sapienza University, Via di Grottarossa 1035-39, 00189, Rome, Italy; <sup>5</sup>Department of Experimental, Diagnostic and Specialty Medicine, Cardiology Unit, IRCCS, University Sant'Orsola Hospital, University of Bologna, Via Massarenti 9, 40138, Bologna, Italy; <sup>6</sup>Department of Internal Medicine, Cardiovascular Unit, University of Genova, Viale Benedetto XV 10, 16132, Genova, Italy; <sup>7</sup>Department of Cardiovascular, Neural and Metabolic Sciences, Cardiomyopathy Unit, Istituto Auxologico Italiano, Piazzale Brescia, 20, 20149, Milan, Italy; <sup>8</sup>Department of Medicine and Surgery, University of Milan, Bicocca, Piazza dell'Ateneo Nuovo 1, 20126, Milan, Italy; <sup>9</sup>Division of Cardiology, Azienda Ospedaliero Universitaria Città della Salute e della Scienza di Torino, University of Turin, Corso Bramante 88, 10126, Turin, Italy; <sup>10</sup>Department of Emergency and Organ Transplantation, Cardiology Unit, University of Bari Aldo Moro, Piazza Giulio Cesare 11, 70124, Bari, Italy; <sup>11</sup>Cardiomyopathy Unit, Careggi University Hospital, University of Florence, Largo Brambilla 3, 50134, Florence, Italy; <sup>12</sup>Department of Cardiology, University of Messina, Via Consolare Valeria 1, 98125, Messina, Italy; <sup>13</sup>Department of Nuclear Medicine, Azienda Sanitaria Universitaria Giuliano-Isontina (ASUGI) and University of Trieste, Strada di Fiume 447, 34129, Trieste, Italy; <sup>14</sup>Cardiology, Department of Medical and Surgical Specialties, Radiological Sciences and Public Health, University of Brescia, Piazzale Spedali Civili 1, 25123, Brescia, Italy; <sup>15</sup>Cardiology Unit, Azienda Ospedaliero Universitaria di Ferrara, Cona, Via Aldo Moro 8, 44124, Ferrara, Italy; <sup>16</sup>Department of Translational Medical Sciences, Inherited and Rare Heart Disease, Vanvitelli Cardiology, University of Campania Luigi Vanvitelli, Piazza Luigi Miraglia 2, 80138, Napoli, Italy; <sup>17</sup>Emergency Department and Amyloid Research and Treatment Center, IRCCS Policlinico San Matteo Foundation, Viale Camillo Golgi 19, 27100, Pavia, Italy; <sup>18</sup>Department of Internal Medicine, University of Pavia, Via Aselli 43/45, 27100, Pavia, Italy; <sup>19</sup>Cardiovascular Center, University of Ferrara, Via Savonarola 9, 44121, Ferrara, Italy; and <sup>20</sup>Maria Cecilia Hospital, GVM Care & Research, Via Corriera, 1, 48033, Cotignola, Italy

Received 28 May 2021; revised 1 July 2021; editorial decision 15 July 2021;

\* Corresponding author. Tel: +39 040 399 4477, Fax: +39 040 399 4878, Email: [marco.merlo79@gmail.com](mailto:marco.merlo79@gmail.com)

<sup>†</sup>The first two authors contributed equally as first authors.

<sup>‡</sup>The last two authors shared the senior authorship.

Published on behalf of the European Society of Cardiology. All rights reserved. © The Author(s) 2021. For permissions, please email: [journals.permissions@oup.com](mailto:journals.permissions@oup.com).

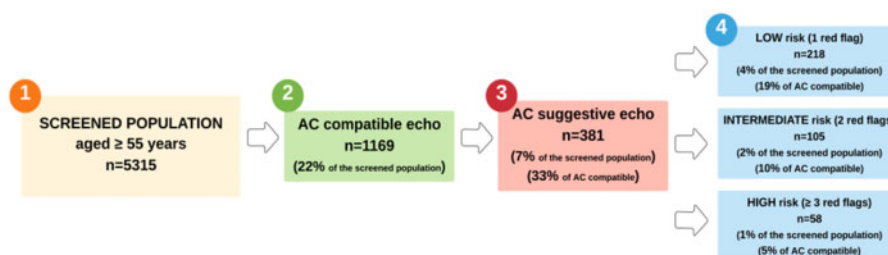
## Keywords

Cardiac amyloidosis • Echocardiography • Epidemiology • Prevalence • Red-flags

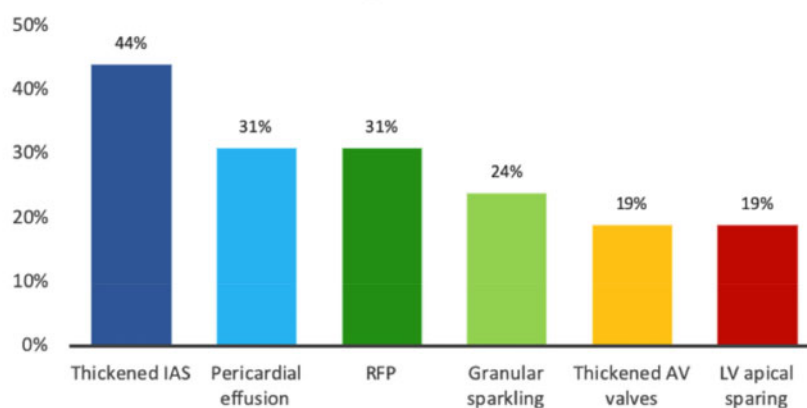
Raising the suspicion of amyloid cardiomyopathy (AC) is essential to orient additional tests and to achieve an early diagnosis before the development of clinically overt disease.<sup>1,2</sup> Notably, echocardiography is the technique with the greatest potential to raise the suspicion of AC by detecting specific signs ('red-flags') of cardiac infiltration.<sup>3</sup> However, the epidemiology of the echocardiographic red-flags of AC

in the general population of patients referred to echocardiography without clinical suspicion of AC and their diagnostic accuracy remain unknown.<sup>4,5</sup>

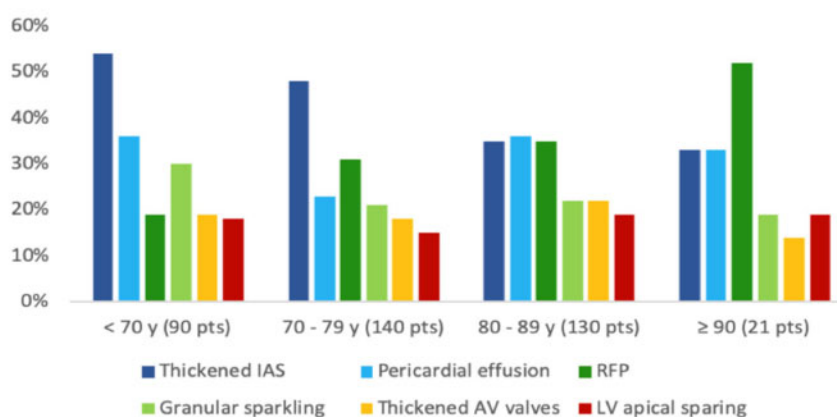
This is a national, multicentre, prospective cohort study performed in 13 tertiary centres across Italy. The local Regional Institutional Review Board approved the study (identifier 199\_2019), and the



Red flags prevalence among the 381 patients with AC suggestive echo



Red flags distribution across age subgroups



**Figure 1** Prevalence of AC-suggestive echocardiograms among screened population (*upper panel*), prevalence of possible echocardiographic red-flags of AC (*middle panel*), and their distribution across age groups (*bottom panel*) in the subgroup of patients with high suspicion of AC. AC, amyloid cardiomyopathy; AV, atrioventricular; LV, left ventricular; IAS, interatrial septum; pts, patients; RFP, restrictive filling pattern; y, years.

participating centres obtained local institutional review board approvals for the collection of prospective anonymous data. The study was registered at ClinicalTrials.gov (#NCT04738266).

The study design consisted of two phases: (i) an observational phase (echocardiographic screening) and (ii) an interventional phase (specific diagnostic work-up for patients with  $\geq 1$  echocardiographic red-flags of AC). In this article, we present the study design and the results of phase 1. Phase 2 is ongoing.

All echocardiograms of consecutive inpatients and outpatients aged  $\geq 55$  years, performed within 15 consecutive working days, were collected. Patients referred for known or suspected AC, known hypertrophic cardiomyopathy or phenocopies were excluded. AC-compatible echocardiogram was defined as: (i) interventricular septum thickness  $\geq 1.2$  cm (women) or  $\geq 1.3$  cm (men); (ii) left ventricular (LV) ejection fraction (EF)  $\geq 50\%$ ; and (iii) indexed end-diastolic LV volume  $\leq 85$  mL/m<sup>2</sup>. AC-suggestive echocardiogram was defined as the presence of AC-compatible echocardiogram and at least one of the following red-flags: (i) restrictive filling pattern; (ii) granular sparkling; (iii) pericardial effusion; (iv) interatrial septum (IAS) thickness  $>0.5$  cm; (v) atrio-ventricular (AV) valve thickness  $>0.5$  cm; and (vi)

LV apical sparing at speckle-tracking echocardiography.<sup>6</sup> IAS and AV valve thickness was measured from the four-chamber view. AC-suggestive echocardiograms were classified according to the number of echocardiographic red-flags: low (1 red-flag), intermediate (2 red-flags), and high ( $\geq 3$  red-flags) suspicion of AC. Echocardiographic parameters were measured by the participating centres, according to international guidelines.<sup>7,8</sup>

Descriptive statistics between the study groups were calculated with appropriate statistical tests. A *P*-value  $<0.05$  was considered statistically significant.

Of the 5315 screened echocardiograms, 1169 (22%) exams were AC-compatible. Among them, 381 exams (7.2% of the screened population; 33% of the AC-compatible echocardiograms) were classified as AC-suggestive, of which 218 (57%), 105 (28%), and 58 (15%; 1.1% of the whole population) patients had a low, intermediate, and high suspicion of AC, respectively (Figure 1, upper panel). The most common clinical indications to echocardiography in AC-suggestive patients were heart failure with preserve ejection fraction (HFpEF) (19.7%), ischaemic heart disease (15.2%), and severe valve disease (12.6%). Indications not included in the list were pooled and

**Table 1** Characteristics of the population with suspected echocardiogram for AC, based on the number of suggestive echocardiographic red-flags

Parameters	N available	All (n 11 (ab	1 red-flag (n = 218, 57%)	2 red-flags (n = 105, 28%)	$\geq 3$ red-flags (n = 58, 15%)	<i>P</i> -value	<i>P</i> -value <sup>a</sup>
Age, years	381	77 (70–83)	78 (70–83)	78 (71–83)	76 (68–84)	0.607	0.356
Men, %	381	191 (50%)	106 (49%)	49 (47%)	36 (62%)	0.135	<b>0.048</b>
HF, %	381	75 (19.7%)	37 (17%)	19 (18%)	19 (33%)	<b>0.024</b>	<b>0.007</b>
IVS, mm	381	13 (13–15)	14 (13–15)	13 (13–14)	14 (13–15)	0.192	0.537
IVS max, mm	381	14 (13–15)	14 (13–15)	13 (13–14)	15 (13–15)	0.063	0.427
EDVi, mL/m <sup>2</sup>	358	51 (43–59)	49 (41–59)	52 (45–61)	52 (47–58)	<b>0.044</b>	0.124
<i>E/E'</i>	311	14 (10–18)	11 (8–17)	12 (10–18)	15 (12–19)	<b>0.002</b>	<b>0.017</b>
LVEF, %	381	59 (55–64)	61 (55–65)	55 (55–60)	55 (50–55)	<b>&lt;0.001</b>	<b>&lt;0.001</b>
RV dysfunction, %	370	35 (10%)	10% (20/209)	9% (9/104)	11% (6/57)	0.924	0.765
RV wall thickness, mm	227	7 (5–9)	5 (4–8)	6 (4–8)	8 (7–10)	<b>&lt;0.001</b>	<b>&lt;0.001</b>
LA diameter, mm	342	42 (37–47)	43 (38–50)	42 (38–46)	39 (36–43)	<b>&lt;0.001</b>	<b>&lt;0.001</b>
Moderate–severe valve disease, %	373	174 (47%)	47% (99/210)	47% (49/105)	45% (26/58)	0.952	0.762
Mitral regurgitation, %	172	82 (48%)	34% (33/97)	67% (33/49)	62% (16/26)	<b>&lt;0.001</b>	0.124
Tricuspid regurgitation, %	173	56 (32%)	29% (28/98)	39% (19/49)	35% (9/26)	0.444	0.791
Aortic regurgitation, %	172	32 (19%)	14% (14/98)	25% (12/49)	23% (6/26)	0.262	0.514
Pulmonary regurgitation, %	173	4 (2%)	3% (3/98)	2% (1/49)	0% (0/26)	0.646	0.395
Mitral stenosis, %	173	4 (2%)	4% (4/98)	0% (0/49)	0% (0/26)	0.209	0.395
Aortic stenosis, %	174	80 (46%)	55% (54/99)	37% (18/49)	31% (8/26)	<b>0.030</b>	0.092
SPAP $> 35$ mmHg, %	337	139 (41%)	52% (93/180)	33% (33/100)	23% (13/57)	<b>&lt;0.001</b>	<b>&lt;0.001</b>
SPAP, mmHg	337	35 (28–44)	36 (30–46)	31 (27–42)	30 (25–35)	<b>0.003</b>	<b>0.030</b>
IVC $> 21$ mm, %	330	38 (12%)	13% (24/180)	10% (9/93)	9% (5/57)	0.519	0.476
IVC, mm	331	16 (13–18)	15 (12–18)	16 (13–18)	17 (15–20)	<b>0.026</b>	<b>0.009</b>

In detail, RV systolic dysfunction was defined as a tricuspid annular plane systolic excursion  $<0.7$  cm, or, in absence of this information, a RV fractional area change  $<35\%$ .

AF, atrial fibrillation; AV, atrioventricular; EDVi, end-diastolic volume indexed; HF, heart failure; IAS, interatrial septum; IVC, inferior vena cava; IVS, interventricular septum; LA, left atrium; LVEF, left ventricular ejection fraction; RFP, restrictive filling pattern; RV, right ventricle; SPAP, systolic pulmonary artery pressure. Boldface values identify statistically significant findings.

<sup>a</sup>*P*-value, comparison between patients with  $\leq 2$  red flags vs.  $\geq 3$  red flags.

accounted for 15.7% of cases. The baseline characteristics of the patients with AC-suggestive echocardiograms are summarized in [Table 1](#).

Thickened IAS ( $n = 169$ , 44%) was the most frequent echocardiographic red-flag, followed by pericardial effusion ( $n = 118$ , 31%) and restrictive LV filling pattern ( $n = 117$ , 31%), granular sparkling appearance of the myocardium ( $n = 90$ , 24%), thickened AV valves ( $n = 74$ , 19%), and apical sparing pattern upon speckle-tracking analysis (66 out of 341 patients with available data, 19%). A similar prevalence of echocardiographic red-flags of AC was found in the subgroup with a high suspicion of AC ([Figure 1](#), middle panel). Of note, the apical sparing pattern was found in 29%, 30%, and 41% of the patients with low, intermediate, and high AC suspicion, respectively. [Figure 1](#), bottom panel shows the prevalence of echocardiographic red-flags according to age groups (<70 years, 70–79 years, 80–89 years,  $\geq 90$  years). The prevalence of thickened IAS decreased with ageing, and the prevalence of the restrictive LV filling pattern increased with ageing.

Compared to the other patients, the 58 patients with high echocardiographic AC suspicion were more frequently men (62% vs. 48%, in the high and non-high AC suspicion patients, respectively,  $P = 0.048$ ); they presented more frequently with HFpEF (33% vs. 17%,  $P = 0.007$ ), had a higher  $E/E'$  ratio [15 (11–18) vs. 10.5 (8–17),  $P = 0.017$ ], a larger left atrial diameter and a thicker right ventricular wall [0.8 cm (0.7–1.0) vs. 0.6 cm (0.4–0.8),  $P < 0.001$ ]. The distribution across age and the prevalence of valve diseases were similar among the patients with a high echocardiographic AC suspicion and the other patients (see [Table 1](#)).

To the best of our knowledge, this is the first report on the prevalence of possible echocardiographic red-flags of AC in a consecutive contemporary cohort of subjects undergoing clinically indicated echocardiography without any pre-test suspicion of AC. The present study is the largest mass screening campaign that measured the proportion of subjects with low, intermediate, and high echocardiographic suspicion of AC.

The main findings of the present study can be summarized as follows: (i) more than 7% of patients  $\geq 55$  years of age undergoing clinically-indicated echocardiography and 33% of patients with non-dilated, hypertrophic LV with preserved EF have echocardiographic red-flags of AC; (ii) patients with a high echocardiographic suspicion of AC ( $\geq 3$  red-flags) represent 1% of patients  $\geq 55$  years of age undergoing clinically-indicated echocardiography and 5% of patients with AC-compatible echocardiograms; (iii) patients with highly AC-suggestive echocardiograms are more frequently referred to echocardiographic laboratories due to HFpEF; and (iv) thickened IAS is the most frequent possible echocardiographic red-flag of AC.

In light of the recent availability and effectiveness of specific therapies (such as tafamidis for transthyretin AC), and regardless of the final AC prevalence (which will be tested in phase 2 of this study), our results suggest the need to modify the current approach of echocardiographic laboratories in order to systematically focus on recognizing AC red-flags (in isolation or in combination).<sup>9</sup> Therefore, increasing awareness of amyloidosis and maintaining a cardiomyopathy-oriented interpretation of echocardiographic images are essential steps to achieve an early AC diagnosis as the benefits from specific therapy initiation are highest in the initial stages of this disease.<sup>1,9</sup> The echocardiographic laboratory should act as the crossroad between outpatient

clinics of the territory and hospital wards, by playing a fundamental role in screening patients, raising the suspicion of AC and orienting diagnostic work-up.<sup>9,10</sup>

## Data Availability Statement

The data underlying this article cannot be shared publicly as these results come from a currently ongoing study and for privacy laws on multicenter datasets. The data will be shared on reasonable request to the corresponding author.

## Funding

This work was supported by the unrestricted general research grant #52524547 by Pfizer, without any control on intellectual contents.

**Conflict of interest:** No conflicts of interest to declare for any author in relation to the submitted work.

Outside the submitted work: G.S. received personal fees for occasional educational activities from Biotronik, Boston Scientific, Astra Zeneca and Novartis. Claudio Rapezzi C.R. served on the Italian scientific advisory board of Pfizer, received unrestricted research grants and personal fees from Pfizer, and personal fees from Alnylam Pharmaceuticals. M.M. received congress fees from Novartis and Vifor Pharma and research grant and congress fees from Pfizer. S.P. received research grants from Pfizer and speaker fees from Pfizer, Alnylam, and Akcea. F.C. received advisory board fees from Pfizer and Akcea and research grants from Pfizer. M.I. received advisory board fees from Kiniksa and Sobi. G.L. received advisory board fees from Pfizer and Genzyme. M.C. received speaker and advisor fees from Akcea Therapeutics, Menarini, Novartis, Pfizer, Sanofi e Sanofi Genzyme, Vifor Pharma, and an investigator-initiated grants from Pfizer. E.B. received advisory board fees from Sanofi, Genzyme and Takeda. All other authors have declared no conflict of interest.

## References

- Maurer MS, Bokhari S, Damy T, Dorbala S, Drachman BM, Fontana M, Grogan M, Kristen AV, Lousada I, Nativi-Nicolau J, Cristina Quarta C. Expert consensus recommendations for the suspicion and diagnosis of transthyretin cardiac amyloidosis. *Circ Heart Fail* 2019;**12**:e006075.
- Porcari A, Merlo M, Rapezzi C, Sinagra G. Transthyretin amyloid cardiomyopathy: an uncharted territory awaiting discovery. *Eur J Intern Med* 2020;**82**:7–15.
- Boldrini M, Cappelli F, Chacko L, Restrepo-Cordoba MA, Lopez-Sainz A, Giannoni A, Aimo A, Baggiano A, Martinez-Naharro A, Whelan C, Quarta C, Passino C, Castiglione V, Chubuchnyi V, Spini V, Taddei C, Vergaro G, Petrie A, Ruiz-Guerrero L, Moñivas V, Mingo-Santos S, Mirelis JG, Dominguez F, Gonzalez-Lopez E, Perlini S, Pontone G, Gilmore J, Hawkins PN, Garcia-Pavia P, Emdin M, Fontana M. Multiparametric echocardiography scores for the diagnosis of cardiac amyloidosis. *JACC Cardiovasc Imaging* 2020;**13**:909–920.
- Maurer MS, Elliott P, Comenzo R, Semigran M, Rapezzi C. Addressing common questions encountered in the diagnosis and management of cardiac amyloidosis. *Circulation* 2017;**135**:1357–1377.
- Buja LM, Khoi NB, Roberts WC. Clinically significant cardiac amyloidosis. Clinicopathologic findings in 15 patients. *Am J Cardiol* 1970;**26**:394–405.
- Phelan D, Collier P, Thavendiranathan P, Popović ZB, Hanna M, Plana JC, Marwick TH, Thomas JD. Relative apical sparing of longitudinal strain using two-dimensional speckle-tracking echocardiography is both sensitive and specific for the diagnosis of cardiac amyloidosis. *Heart* 2012;**98**:1442–1448.
- Lang RM, Badano LP, Mor-Avi V, Afilalo J, Armstrong A, Ernande L, Flachskampf FA, Foster E, Goldstein SA, Kuznetsova T, Lancellotti P, Muraru D, Picard MH, Rietzschel ER, Rudski L, Spencer KT, Tsang W, Voigt J-U. Recommendations for cardiac chamber quantification by echocardiography in adults: an update from the American Society of Echocardiography and the European Association of Cardiovascular Imaging. *Eur Heart J Cardiovasc Imaging* 2015;**16**:233–271.
- Voigt J-U, Pedrizzetti G, Lysyansky P, Marwick TH, Houle H, Baumann R, Pedri S, Ito Y, Abe Y, Metz S, Song JH, Hamilton J, Sengupta PP, Koliaas TJ, d'Hooge J, Aurigemma GP, Thomas JD, Badano LP. Definitions for a common standard for 2D speckle tracking echocardiography: consensus document of the EACVI/ASE/Industry Task Force to standardize deformation imaging. *Eur Heart J Cardiovasc Imaging* 2015;**16**:1–11.

9. Garcia-Pavia P, Rapezzi C, Adler Y, Arad M, Basso C, Brucato A, Burazor I, Caforio ALP, Damy T, Eriksson U, Fontana M, Gillmore JD, Gonzalez-Lopez E, Grogan M, Heymans S, Imazio M, Kindermann I, Kristen AV, Maurer MS, Merlini G, Pantazis A, Pankuweit S, Rigopoulos AG, Linhart A. Diagnosis and treatment of cardiac amyloidosis: a position statement of the ESC Working Group on Myocardial and Pericardial Diseases. *Eur Heart J* 2021;**42**:1554–1568.
10. Gillmore JD, Maurer MS, Falk RH, Merlini G, Damy T, Dispenzieri A, Wechalekar AD, Berk JL, Quarta CC, Grogan M, Lachmann HJ, Bokhari S, Castano A, Dorbala S, Johnson GB, Glaudemans AWJM, Rezk T, Fontana M, Palladini G, Milani P, Guidalotti PL, Flatman K, Lane T, Vonberg FW, Whelan CJ, Moon JC, Ruberg FL, Miller EJ, Hutt DF, Hazenberg BP, Rapezzi C, Hawkins PN. Nonbiopsy diagnosis of cardiac transthyretin amyloidosis. *Circulation* 2016;**133**:2404–2412.