

## Review Article

# Biliary tract cancers: moving from the present standards of care towards the use of immune checkpoint inhibitors

Gaetano Pezzicoli, Giacomo Triggiano, Maria Chiara Sergi, Francesco Mannavola, Camillo Porta, Marco Tucci

*Department of Biomedical Sciences and Human Oncology, University of Bari 'Aldo Moro' and Division of Medical Oncology, A.O.U. Consorziiale Policlinico di Bari, Bari, Italy*

Received January 27, 2021; Accepted June 8, 2021; Epub August 15, 2021; Published August 30, 2021

**Abstract:** Biliary tract cancers (BTCs) are aggressive and chemoresistant tumors associated with poor prognosis. Thus, more active and effective treatments are urgently needed, among which immunotherapy holds promise for the near future. Preclinical data show that BTCs are mainly immunosuppressed cancers, thus suggesting that their immunogenic potential may be unleashed with the appropriate strategy. Immune checkpoint inhibitors (ICIs) could theoretically be effective in BTCs by blocking those inhibitory checkpoints that limit the activation and the expansion of the effector cells of the immune response. Many currently ongoing trials aim to demonstrate the efficacy of ICIs and to incorporate immunotherapy into the routine management of BTCs. Presently available results are controversial and there is no consensus on the role of ICIs in monotherapy, while combinations of immunotherapy with chemotherapy look more promising. Nevertheless, despite the many proposed over time, there are no predictive biomarkers presently available, thus, the early identification of those patients showing a good response is of great significance.

**Keywords:** Biliary tract cancers, immune checkpoint inhibitors, chemotherapy, combinations, biomarkers

## Introduction

Biliary tract cancers (BTCs) are a group of rare tumors arising from biliary epithelial cells that include three main cancer types: gall bladder carcinoma (GBC), intrahepatic cholangiocarcinoma (iCCA), and extrahepatic cholangiocarcinoma (eCCA). Extrahepatic cholangiocarcinoma is further classified as perihilar (pCCA, namely Klastkin tumor), or distal cancer (dCCA). Klastkin tumor is the most common type and originates from the confluence between the right and left hepatic ducts. Distal extrahepatic tumor, instead, takes origin from the upper border of the pancreas to the ampulla. BTCs can also be divided into small-duct and large-duct types which are often associated with chronic hepatitis/liver cirrhosis and chronic cholangiopathies, respectively [1].

The etiology of BTCs is unknown, but chronic inflammation or parasitic infections as well as

autoimmune conditions (i.e., primary sclerosing cholangitis) promote cell proliferation, and cause accumulation of genetic abnormalities, ultimately leading to malignant transformation. Other common risk factors are related to lifestyle, such as alcohol consumption, tobacco smoking, fat-rich diet, and obesity.

BTCs account for almost 3% of all adult cancers, and the overall incidence is still growing, especially in geographic areas with a higher prevalence of the disease such as Japan and South Korea, whereas in Europe and the USA, it ranges from 2 to 6 cases per 100,000 people per year [2]. BTCs mainly involve adults (50-70 years) with a higher prevalence of cholangiocarcinoma (CCA) in males and GBCs in females.

The most common clinical manifestations are jaundice and pruritus caused by biliary obstruction, although frequently BTCs are poorly symptomatic only causing abdominal pain, weight

loss and low-grade fever. The disease evolves rapidly, leading to cachexia and quick deterioration of performance status. The mortality rate is 3.58 per 100,000 while 5-year survival is just 2% in the metastatic setting, often due to late diagnosis [1]. The prognosis depends on primitive tumor extension, lymph node involvement, vascular invasion, positive tumor margins after resection, p53 mutation, and histological features.

To date, the only curative therapy is surgery, but less than 35% of BTCs are detected at an early stage. Moreover, relapse rate is high despite radical surgery. In the locally-advanced or metastatic setting, systemic chemotherapy still represents the standard of care, although it only obtains a modest improvement in median overall survival (OS), which generally remains shorter than 12 months [2].

To date, immunotherapy is increasingly applied in the adjuvant and first-line therapy of many cancers, achieving prolonged progression-free survival (PFS) and OS [3-7]. Like the majority of gastrointestinal cancers, in BTCs, the impact of immune-based approaches has yet to be confirmed. However, the etiological background of BTCs, which almost constantly leads to a state of chronic inflammation, provides a strong clue that these approaches may have an impact on this group of malignancies in the near future [8].

Herein, we describe new insights into the potential role of immunotherapy in locally advanced and metastatic BTCs.

### The standard of care in biliary tract cancer

#### *Surgery*

It is the standard treatment option for BTCs, but its feasibility is limited due to the frequent occurrence of a poor performance status, the presence of distant metastases, the involvement of vascular structures, and the expected inadequacy of liver function after resection, especially in intrahepatic or hilar disease [9]. Whenever considered, the aim of surgery is to achieve negative surgical margins. A meta-analysis from Li et al. [10] demonstrated that the negativity of surgical margin in iCCA is strongly correlated with best OS (HR: 1.864;

95% CI: 1.542-2.252;  $P < 0.001$ ) and PFS (HR: 2.033; 95% CI: 1.030-4.011;  $P = 0.041$ ), which also applies for both eCCA and GC [11, 12].

Partial hepatectomy is the best option for BTCs invading liver parenchyma, while in those showing a massive hepatic involvement, ALPPS (Associating Liver Partition with Portal vein ligation for Staged hepatectomy) is not recommended because it apparently increases mortality [13, 14]. Instead, for those patients who require an extensive resection (up to 50-60% of total parenchyma), portal embolization is the most effective procedure to induce compensatory hypertrophy [15]. Another key factor in the BTC surgery concerns the regional lymphadenectomy, which is recommended by ESMO guidelines [16], although its role is still controversial. In fact, no significant increase in disease-specific survival (DSS) has been observed [17], and therefore, it is considered important for the staging process [18].

#### *Adjuvant therapy*

Adjuvant therapy is indicated for patients following R0 or R1 surgical resection. Available treatments consist of chemotherapy and/or radiation therapy. Nowadays, there is no universal consensus about the best adjuvant chemotherapy regimen; even the use of a monotherapy or a doublet is still debated. The PRODIGE-12 trial evaluated the efficacy and safety of the combination of Gemcitabine and Oxaliplatin, and compared to surveillance there was no significant difference in RFS (HR 0, 88; 95% CI, 0.62 to 1.25;  $P = 0.48$ ) [19]. On the other hand, the BILCAP study, which compared Capecitabine monotherapy to surveillance [20], resulted in a numerically longer, but not statistically significant improvement in OS (51 vs. 36 months; HR 0.81; 95% CI 0.63-1.04;  $P = 0.097$ ).

The role of radiation therapy (RT) in BTC is debated, and the majority of studies were based on small and heterogeneous cohorts mostly formed by patients bearing eCCA. A meta-analysis by Bonnet-Beltràn et al. demonstrated a significant improvement of OS for eCCA patients who received adjuvant RT with 3D techniques (HR 0.62; 95% CI 0.48 to 0.78,  $P < 0.001$ ). Moreover, this treatment is more effective in patients bearing surgical positive margins (R1)

and/or with positive lymph nodes [21]. Almost similar results were also demonstrated in GC patients [22].

Another interesting strategy is represented by the combination of chemotherapy and RT that turns out to be promising. The SWOG S0809 phase II trial investigated 79 patients who underwent 4 courses of Gemcitabine (1,000 mg/mq IV on days 1 and 8) and Capecitabine (1,500 mg/mq per day, on days 1 to 14) every 21 days, followed by concurrent Capecitabine (1330 mg/mq per day) and radiotherapy (45 Gy to regional lymphatics; 54 to 59 Gy to tumor bed), resulting in 2 years survival of 65% (95% CI, 53% to 74%) [23]. Of course, the limited number of patients treated with this combined approach limits its immediate exportability into clinical practice.

### *Treatment of the metastatic disease*

As already highlighted, many BTCs are already diagnosed in a metastatic or unresectable stage and even after radical surgery; relapse occurs in more than 60% of cases within 2 years from the treatment. The main therapeutic option in this setting is chemotherapy with the aim of improving both OS and quality of life. A meta-analysis by Eckel et al. investigated the clinical trials completed between 1985 and 2007 in patients with metastatic BTCs. Combination therapies were superior to single agents in terms of tumor control rate (TCR), and the combination of Gemcitabine and a platinum-compound yielded best results among the explored therapies [24]. These data were confirmed by the ABC-02 trial that compared the combination of Gemcitabine and Cisplatin with Gemcitabine alone. The median OS was 11.7 months among patients treated with the combination and 8.1 months in those receiving gemcitabine (HR 0.64; 95% CI, 0.52 to 0.80;  $P < 0.001$ ). Moreover, a number of phase-2 studies which evaluated the efficacy of Gemcitabine and Oxaliplatin showed an OS ranging from 8.3 to 12.4 months [25-30]. Since no head-to-head randomized clinical trials are available, it is therefore not possible to define the best option among the two described above. As a consequence, the Gemcitabine-Oxaliplatin regimen is usually administered to patients unfit for Cisplatin.

Due to the BTC's poor clinical outcome, very few data are available in the second-line setting; a recent phase 3 study (ABC-06) compared the mFOLFOX regimen (5-Fluorouracil, Folinic Acid, Oxaliplatin) to active supportive care (ASC), in patients who progressed after Gemcitabine-Cisplatin. The OS was slightly but still significantly higher in the chemotherapy group (6.2 vs. 5.3 months, HR 0.69,  $p = 0.031$ ) [31].

Targeted therapy could be a promising option. In the LBA40-FIGHT202 phase II clinical trial, patients who failed at least one therapeutic line were treated with Pemigatinib, a potent and selective FGFR2 inhibitor. Indeed, patients with fusions or rearrangements of FGFR2 gene reported 35.5% objective response rate (ORR), with a PFS and OS of respectively 6.9 and 21.1 months. However, no responses were observed in the FGFR2 wild-type cohort. Therefore, Pemigatinib could be considered as a possible second-line treatment limited to patients bearing the FGFR2 fusions or rearrangement [32].

### **The rationale for the use of immunotherapy in BTCs**

Cancer immunotherapy can arguably be considered as a critical breakthrough in the last decade and emerged as a promising option for chemo-resistant cancers [33-35].

The rationale for the application of immunotherapy in cancer resides in immune evasion mechanisms. They include the attraction nearby tumor of immune suppressor cells, the secretion of immunosuppressive cytokines, and the induction of anergy in effector T lymphocytes. Although, across multiple malignancies, high immune infiltration correlates with a better prognosis, thus suggesting that the immune response plays a consistent role in tumor suppression, and immune cells, di per se, are not enough to induce tumor regression, or even control [36, 37]. At present, the most validated immunotherapeutic strategy relies on the block of immune checkpoints.

Checkpoint inhibitor therapy targets immune checkpoints negatively regulating antitumor immune response. Indeed, cancer cells can protect themselves from the attack by the effector cells of the immune system by activating these

inhibitory proteins which, in turn, are blocked by immune checkpoint inhibitors (ICIs), which are thus able to restore immune system function [38].

Currently available checkpoint inhibitors target the molecules CTLA4, PD-1, and PD-L1.

CTLA-4 (cytotoxic T-lymphocyte-associated protein 4), also known as CD152 is a protein receptor that functions as an immune checkpoint downregulating immune responses at the level of priming of effector T lymphocytes by antigen-presenting cells within lymph nodes. CTLA4 is constitutively expressed in regulatory T cells, but only upregulated in conventional T cells as a physiologic brake after activation. It acts as an “off” switch when bound to CD80 or CD86 on the surface of [39].

PD-1 (programmed cell death 1 protein), aka CD279 is a transmembrane protein which interacts with PD-L1 (PD-1 ligand 1, or CD274); within the tumor microenvironment, PD-L1 expressed on tumor cells binds to PD1 on immune cells' surface, thus inhibiting antitumor immune cell activity. Indeed, among PD-L1 functions there is a key regulatory role on T cell activities. Antibodies that bind to either PD-1 or PD-L1 therefore allow the T-cells to attack the tumor and potentially reject it [40].

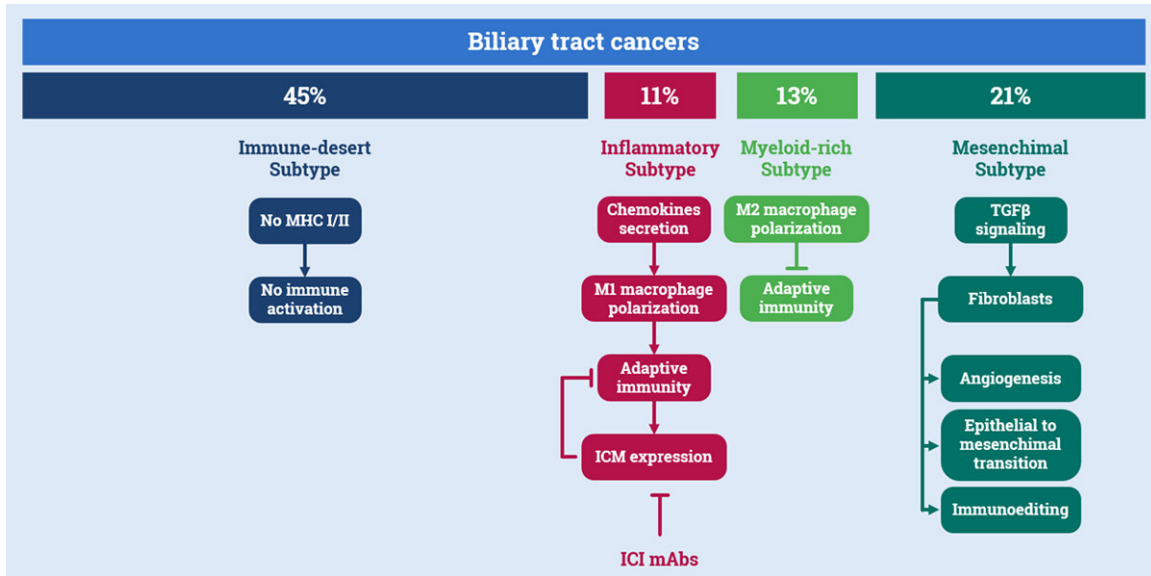
Although tumor tissue analyses revealed response correlations with PD-L1 immunohistochemical expression, mutational load, neoantigen load, immune-related gene expression, and CD8<sup>+</sup> T-cell infiltration at tumor's invasive margins across different tumor types, no biomarker emerged to date, which could be used in everyday clinical practice, as well as in different tumor types [41-43].

### *The immunological landscape of BTCs*

The characterization of the molecular features of microenvironment surrounding malignant cells is fundamental in BTCs and, similarly to other cancers, basic research exploring the ‘hot’ or ‘cold’ tumor milieu is the main focus of a number of ongoing studies. Usually, hot tumors show a high neoantigen load that negatively influences the antitumor response and, moreover, are infiltrated by TILs (Tumor-Infiltrating Lymphocytes) whose activity is however strongly suppressed [44].

A major mechanism that contributes to regulate, positively or negatively, the antitumor immune response is the expression of IC receptors; among them, the most widely studied is PD-L1, endowed-as already discussed-by an inhibitory activity on the immune system. A recent study exploring the gene profile of BTCs demonstrated the existence of a subpopulation characterized by poor prognosis in relation to high TMB and elevated PD-L1 expression [45]. In addition, a subset of PD-L1 expressing BTCs (46% of the total) showed a correlation between the extent of PD-L1 expression, by either neoplastic or inflammatory cells, and the density of the lymphocytic infiltrate [46]. Furthermore, Zhou et al. characterized the lymphocytes infiltrating the tumor, thus revealing that regulatory T cells were often located inside the tumor, whereas the majority of both cytotoxic and helper T cells surrounded the periphery of the tumor. On the contrary, natural killer cells (NKs) were mostly excluded from the tumors. Based on these observations, the authors also produced an ex-vivo model, thus providing the rationale for the use of ICIs in cholangiocarcinoma [47]. These data are consistent with the presence of a subpopulation of BTCs with overwhelming immunosuppressive features. This is also supported by Job et al. who investigated the characteristics of the microenvironment in BTCs, and described four immune subtypes based on the transcriptomic signature of either fibroblasts or immune cells. The majority of the analyzed tumors (45%) showed an ‘immune-desert’ subtype, that is mainly characterized by elements of immunologic ignorance such as depletion of MHC class-I, loss of  $\beta$ 2-microglobulin, defective T-cell priming, reduced CD8<sup>+</sup> T-cells penetration and cytotoxicity. On the other hand, only 11% of tumors have been classified as ‘inflamed’, showing a tumor microenvironment enriched by immune cells such as effector and memory T cells, B cells, and macrophages, and depleted from suppressive factors. Even though this class of tumors is supposed to be strongly immunogenic, it is also able to escape the immune response via ICs immunosuppression (CTLA-4, CD274, PD-CD1LG2) and TGF- $\beta$  signaling. The remaining tumors were almost equally divided between a ‘myeloid’ subtype-infiltrated by M2 macrophages and CD4<sup>+</sup> T lymphocytes, with strong suppression of adaptive immunity-and a ‘mes-

## Immunotherapy in biliary tract cancers



**Figure 1.** Immunological subtypes of BTCs. The majority of BTCs (45%) display an ‘immune-desert’ phenotype, characterized by the depletion of MHC class I and the loss of  $\beta$ 2-microglobulin, implying a defective T-cell priming. Only 11% of tumors can be classified as ‘inflammatory’ subtype, with many types of immune cells infiltrating the tumor in an inflammatory microenvironment, which induces cancer cells to express immunosuppressive factor. About 13% of BTCs show the ‘myeloid’ subtype, with a massive M2 macrophages infiltration and suppressive CD4<sup>+</sup> T lymphocytes. The last 21% of BTCs fall in the “mesenchymal” subtype, with active fibroblast able to produce abundant stroma that acts as a barrier preventing infiltration and migration of immune cells. Modified from Job et al. [48].

**Table 1.** Overview of clinical trials featuring immunotherapy in BTCs

Study	Design	mOS (months)	mPFS (months)	ORR (%)
KEYNOTE-028 (phase Ib)	Pembrolizumab in previously treated PD-L1 <sup>+</sup> pts	NR	NR	17
Kang et al.	Pembrolizumab in previously treated pts	4.3	1.5	12.5
Lee et al.	Pembrolizumab in previously treated pts	6.9	2.1	9.8
Arkenau et al. (phase I)	Pembrolizumab+Ramucirumab in previously treated pts	6.4	1.6	4
Gbolahan et al. (phase II)	Nivolumab in previously treated pts	NR	4	22
Gou et al.	Nivolumab+Gemcitabine in previously treated pts	NR	3.1	20
Sun et al.	Nivolumab+Gemcitabine in 1 <sup>st</sup> line	14.9	5.1	34
Ueno et al. (phase I)	Nivolumab+Cisplatin/Gemcitabine in previously treated pts	15.4	4.2	33
Sahai et al. (phase II)	Nivolumab/Ipilimumab in 1 <sup>st</sup> line	10.6	7.4	NR
NCT03250273 (phase I)	Nivolumab+Entinostat in previously treated pts		ONGOING	
NCT03201458 (phase II)	Atezolizumab+Cobimetinib in previously treated pts		ONGOING	
TOPAZ-1 (phase III)	Durvalumab+Cis/Gem in 1 <sup>st</sup> line		ONGOING	
IMMUWHY (phase II)	Durvalumab+Tremelimumab+ Radiotherapy in 1 <sup>st</sup> line		ONGOING	
IMMUNO-BIL (phase II/III)	Durvalumab+Tremelimumab in previously treated pts		ONGOING	
NCT02268825 (phase I)	Pembrolizumab+mFOLFOX6 in previously treated pts		ONGOING	
KEYNOTE-966 (phase III)	Pembrolizumab+Gemcitabine/Cisplatin vs. Gemcitabine/Cisplatin 1 <sup>st</sup> line		ONGOING	

Abbreviations: NR: not reported.

enchymal’ subtype-with active fibroblasts able to produce abundant stroma acting as a barrier preventing infiltration and migration of immune cells nearby tumor cells (**Figure 1**) [48]. In con-

clusion, BTCs are immunosuppressive tumors, thus explaining why targeting immune cells does not always lead to a real benefit in terms of anti-tumor response.



## Immunotherapy in biliary tract cancers

### *Clinical trials featuring immunotherapy in BTCs*

The principal clinical trials featuring immunotherapy in BTCs are listed in **Table 1**.

*Anti PD-1/PD-L1 agents' monotherapy in pre-treated patients:* ICI monotherapy exploits its action by lowering the immune tolerance against tumor cells. One of the first evidence of its efficacy came from the KEYNOTE-028 study, a phase Ib trial of pembrolizumab in patients with advanced PD-L1<sup>+</sup> cancers, who failed at least one previous line of therapy. Among the BTCs population (represented by 86 patients), 42% were PD-L1<sup>+</sup>; in these patients, the objective response rate (ORR) was 17% (95% CI, 5%-39%), with a 17% of partial responses; another 17% had a stable disease, while 52% progressed. As far as safety, 17% of the patients experienced grade 3-4 adverse events [49].

The efficacy of pembrolizumab was also reported in a case series [50], describing 40 patients with metastatic BTCs who underwent 2 or more lines of therapy and were subsequently treated with pembrolizumab until progression or toxicity. The median OS was 4.3 months, with an ORR of 12.5%. Interestingly, even though the general median PFS was 1.5 months, it was significantly higher in patients with high expression of PD-L1 (defined as those with a Tumor Proportion Score, TPS  $\geq$  50%) [51]. Similar results were reported by Lee et al., who investigated 40 patients with metastatic PD-L1<sup>+</sup> BTCs refractory to Gemcitabine/Cisplatin; in these patients pembrolizumab yielded median PFS and OS of 2.1 months and 6.9 months, respectively [52]. However, no correlation was found between the TPS and outcome.

*Anti PD-1/PD-L1 agents in combination with chemotherapy in pretreated patients:* As previously demonstrated in non-small cell lung cancer, the combination of chemotherapy and ICIs can improve the efficacy of immunotherapy [53]. Mou et al. reported the case of a patient with iCCA, who experienced peritoneal recurrence after surgery. The patient experienced an early progression after 4 cycles of first-line chemotherapy consisting of Gemcitabine and Cisplatin. The tumor had a high PD-L1 expression (TPS: 80%) and a high TMB (19.3 mut/Mb). The patient was treated with a combination of SOX (oxaliplatin 130 mg/m<sup>2</sup>, d1, Tegafur-

Gimeracil-Oteracil 60 mg BID, d1-14, q3w) and pembrolizumab (150 mg q3w) for 8 cycles, achieving a complete response. The patient resulted to be free from active disease for almost one year until the time of the publication [54].

Recently, a phase-I trial analyzing the clinical outcomes of a pembrolizumab-FOLFOX6 combination as first-line therapy for BTCs was completed (NCT02268825), resulting in an acceptable safety profile [55].

Similarly, the phase III study KEYNOTE-966 is evaluating the outcome of Pembrolizumab plus Gemcitabine/Cisplatin versus Gemcitabine/Cisplatin alone as first-line therapy in advanced BTCs (NCT04003636).

A possible role of Nivolumab in combination with chemotherapy has also been investigated [56] in a phase-II study enrolling 58 previously treated patients with metastatic BTC. A 22% ORR and a 4-months median PFS were achieved, in exchange for a 20% incidence of moderate adverse events, which did not require drug discontinuation [57]. Unfortunately, data correlating PD-L1 expression to the outcome are still unavailable. Another trial evaluated nivolumab in monotherapy and in combination with chemotherapy (in 50% of cases represented by gemcitabine) in naïve and pretreated patients with metastatic BTCs. Median PFS was 3.1 months, with an ORR of 20%, with minor adverse events more frequently observed in the combination arm. This study also showed that nivolumab combined with chemotherapy yielded longer PFS compared with nivolumab alone (4.3 vs. 2.1,  $P < 0.05$ ); PD-L1 levels were not correlated with PFS [58].

The Nivolumab-chemotherapy combination was also evaluated in a study by Sun et al. who demonstrated a median OS of 14.9 months for the patients receiving combination therapy (Gemcitabine was again the preferred agent), 4.1 months for the anti-PD-1 monotherapy group, and 6.0 months for those receiving chemotherapy alone. Only the difference between the combination and monotherapy arms was statistically significant ( $P = 0.001$  and  $P = 0.011$  respectively) [59]. However, no data on the relation between PD-L1 expression and clinical outcome were reported.

## Immunotherapy in biliary tract cancers

Finally, a phase III trial (TOPAZ-1) featuring the anti-PD-L1 MoAb Durvalumab is currently ongoing. The study aimed to compare the combination of Durvalumab and Gemcitabine/Cisplatin chemotherapy with Gemcitabine/Cisplatin alone as first-line in advanced BTCs (NCT-03875235).

As a whole, all the above studies those results have already been reported suggested a possible role for chemo-immunotherapy combination and supported the hypothesis of a higher antitumor activity of immunotherapy as a consequence of epitope spreading.

*Anti PD-1/PD-L1 agents in combination with chemotherapy in naïve patients:* Theoretically, a more relevant therapeutic effect by the combination of chemo and immunotherapy could be expected in the first-line setting.

A multi-cohort phase I trial investigated both the efficacy of Nivolumab (240 mg q2w), Cisplatin (25 mg/m<sup>2</sup>) and Gemcitabine (1,000 mg/m<sup>2</sup>) combination in previously untreated patients with unresectable BTCs and Nivolumab alone (240 mg q2w) in patients with unresectable BTCs refractory to gemcitabine-chemotherapy. In the pretreated cohort receiving monotherapy, median OS was 5.2 months, and median PFS was 1.4 months (90% CI 1.4-1.4). On the other hand, the naïve cohort receiving combined therapy showed a median OS of 15.4 months, and a median PFS of 4.2 months, whereas 11 of 30 patients had an OR. Adverse events were more common in the combination arm (90% of patients had a grade 3-4 adverse event). Patients with a PD-L1 TPS  $\geq$  1% reported a better ORR, median PFS, and median OS [60].

*Combinations of anti-PD-1, anti-CTLA4 with or without chemotherapy:* A phase II study comparing the Nivolumab/Gemcitabine-Cisplatin regimen with the Nivolumab/Ipilimumab combination is currently ongoing (NCT03101566). Preliminary data reveal a median PFS of 8.8 months in the chemo-immunotherapy arm and 4.1 months in the combined immunotherapy arm. Median OS was 10.6 months and 8.3 months, respectively. The combination immunotherapy arm performed worse than the historical control while the chemo-immunotherapy arm has clinical outcome comparable to the

standard-of-care treatment. Interestingly, 40% of these patients are still alive [61].

Another phase II trial (IMMUWHY) is evaluating the effect of specific internal radiotherapy combined with Durvalumab alone or with Durvalumab and Tremelimumab (NCT04238637).

Durvalumab and Tremelimumab combination is under investigation also in the setting of platinum-resistant patients: the combination with or without weekly Paclitaxel is indeed the object of the IMMUNO-BIL phase II/III study (NCT03704480).

*Anti PD-1/PD-L1 agents in combination with targeted therapy:* The combination of ICIs with targeted agents is presently extensively studied, given a number of promising data in other types of tumor, such as melanoma [62] and lung cancer [63].

Arkenau et al. concluded a phase-I trial of Pembrolizumab-Ramucirumab combination in patients with advanced or metastatic BTCs [64]. Ramucirumab is an anti-VEGFR2 MoAb, which limits the tumor neo-angiogenesis. Some preclinical studies showed that the combination of angiogenesis blockade and immune stimulation leads to an increased antitumor effect [65, 66]. However, clinical data revealed an ORR of 4%, as well as a median PFS and OS of 1.6 months and 6.4 months, respectively. On the other hand, this study was designed to evaluate the safety profile and the result was acceptable.

The combination of Nivolumab and targeted therapy is also under investigation [67]. A phase I trial (NCT03250273) is presently ongoing aimed at evaluating the combination of Nivolumab and Entinostat, a histone deacetylase inhibitor in BTCs patients who have progressed after at least one line of therapy [68]. Indeed, in murine models of pancreatic cancer, Entinostat was shown to inhibit suppressive myeloid-derived suppressor cells (MDSC) with consequent recruitment of T cells, and thus, it could exert a synergistic effect together with anti-PD-1 therapy.

In a phase II trial (NCT03201458), Atezolizumab was compared with a combination of Atezolizumab and the MEK inhibitor Cobimetinib. Early

## Immunotherapy in biliary tract cancers

results showed a better performance of the combination (median PFS of 111 days vs. 57 days). Interestingly, patients assigned to the combination remained on treatment for more than 15 months. One of the synergistic mechanisms hypothesized for this combination could be an effect of MEK inhibition, which induces an increase in the CD8/Foxp3 ratio, thus reducing the cohort of immunoregulatory cells in the tumor infiltrate [69].

*Anti PD-1/PD-L1 agents in combination with local therapies:* A phase II ongoing clinical trial (NCT03937830) is evaluating the efficacy of Bevacizumab, Durvalumab, Tremelimumab with Transarterial Chemoembolization (TACE) in advanced BTC. The rationale for this combination resides in the epitope-spreading effect of the TACE that may enhance the activation of immune system caused by the ICI combination. Results are expected in 2023.

*Anti PD-1/PD-L1 agents in the adjuvant and neoadjuvant setting:* Given the first efficacy data reported for the chemo-immuno combination in the metastatic BTC setting, ICI are currently under evaluation in the adjuvant and neoadjuvant setting. The ACCORD phase II trial (NCT04333927) is investigating the efficacy and safety of adjuvant immunotherapy combined with chemoradiation for patients with high-risk resectable extrahepatic cholangiocarcinoma and gallbladder cancer. Specifically, the patients who underwent radical surgery, received Camrelizumab (an anti PD-1 agent) for 1-2 courses and subsequently went on to receive capecitabine concurrent with radiotherapy to preoperative tumor bed. The completion of the follow-up is expected in 2024. In a similar fashion, the DEBATE phase II trial (NCT043-08174) is enrolling patients with localized BTC to receive Durvalumab plus gemcitabine/cisplatin as a neoadjuvant therapy in order to improve the R0 resection rate.

### Future perspectives

Biliary tract cancers show a worst clinical outcome and are mainly diagnosed in an already metastatic stage. Moreover, none of the presently available treatment strategies is satisfactory.

Cancer immunotherapy is the major breakthrough achieved by medical oncology in the

last decade, leading to an important change in clinical practice in many tumor types.

BTCs are highly immunosuppressive cancers, but molecular analysis suggests that an inflammatory subtype may exist, even if it would be the rarest. The scarcity of this potentially immune-sensible tumors justifies by the usually poor outcome observed in clinical of ICIs in BTCs, although a small number of patients with a much better clinical outcome compared with the overall study population are constantly reported, not to take into account a number of case reports of extraordinary responses to immunotherapy (which however realistically suffer from reporting bias).

Slightly better results were usually observed with combinations of immunotherapy and chemotherapy, and this could be explained by a mechanism of epitope spreading exerted by cytotoxic drugs.

As a whole, available evidence suggests the presence of a subgroup of patients which would benefit from ICIs, due to peculiar molecular characteristics. These tumors could match the 'inflammatory' BTC subtype mentioned above [48].

Therefore, immunotherapy could find a field of application in BTCs, but a predictive biomarker would be badly needed. The role of the PD-L1 TPS appears to be controversial since it does not often correlate with response to ICIs. On the other hand, despite being promising, TMB has not yet been confirmed within prospectively conducted randomized clinical trials. Another possibility could be the evaluation of the microsatellite instability that often correlates with a greater neoantigen generation, but there are not many evidences in the BTCs setting yet.

Finally, immunotherapy could move far beyond ICIs. Recently, Rojas-Sepúlveda et al. worked on the isolation of specific neoantigen from BTCs to create a specific vaccine, which showed promising results *in vitro* [70]. Another promising strategy could be cell therapy, specifically, the development of chimeric antigen receptor T-cells (CAR-T) engineered to target cancer cells. A phase I clinical trial evaluating the effectiveness of HER 2 specific CAR-T cells was recently published. Nine chemotherapy-resistant



HER-2<sup>+</sup> BTCs patients received the infusion of CAR-T cells. The regression or even the disappearance of metastatic lesions was reported, implying that this option could be applied in this field, even if it needs to be confirmed in larger studies [71]. Research on alternative targets is currently ongoing, with an active phase I/II clinical trial based on MUC-1 specific CAR-T cells (NCT03633773).

### Disclosure of conflict of interest

None.

**Address correspondence to:** Dr. Marco Tucci, Department of Biomedical Sciences and Human Oncology, University of Bari 'Aldo Moro' and Division of Medical Oncology, A.O.U. Consorziale Policlinico di Bari, Piazza Giulio Cesare, 11, 70124, Bari (BA), Italy. Tel: +39-080-5593674; E-mail: marco.tucci@uniba.it

### References

- [1] Tariq NU, McNamara MG and Valle JW. Biliary tract cancers: current knowledge, clinical candidates and future challenges. *Cancer Man Res* 2019; 11: 2623-2642.
- [2] Benavides M, Antón A, Gallego J, Gómez MA, Jiménez-Gordo A, La Casta A, Laquente B, Macarulla T, Rodríguez-Mowbray JR and Maurel J. Biliary tract cancers: SEOM clinical guidelines. *Clin Transl Oncol* 2015; 17: 982-987.
- [3] Vasekar M, Degraff D and Joshi M. Immunotherapy in bladder cancer. *Curr Mol Pharmacol* 2016; 9: 242-251.
- [4] Bassas Freixas P, Aparicio Español G and García-Patos Briones V. Immunotherapy in nonmelanoma skin cancer. *Actas Dermosifiliogr* 2019; 110: 353-359.
- [5] Moskovitz J, Moy J and Ferris RL. Immunotherapy for head and neck squamous cell carcinoma. *Curr Oncol Rep* 2018; 20: 22.
- [6] Steven A, Fisher SA and Robinson BW. Immunotherapy for lung cancer. *Respirology* 2016; 21: 821-833.
- [7] Cuevas LM and Daud AI. Immunotherapy for melanoma. *Semin Cutan Med Surg* 2018; 37: 127-131.
- [8] Duffy AG, Makarova-Rusher OV and Greten TF. The case for immune-based approaches in biliary tract carcinoma. *Hepatology* 2016; 64: 1785-1791.
- [9] Schulick RD. Criteria of unresectability and the decision-making process. *HPB (Oxford)* 2008; 10: 122-125.
- [10] Li MX, Bi XY, Li ZY, Huang Z, Han Y, Zhao JJ, Zhao H and Cai JQ. Impaction of surgical margin status on the survival outcome after surgical resection of intrahepatic cholangiocarcinoma: a systematic review and meta-analysis. *J Surg Res* 2016; 203: 163-173.
- [11] Mansour JC, Aloia TA, Crane CH, Heimbach JK, Nagino M and Vauthey JN. Hilar cholangiocarcinoma: expert consensus statement. *HPB (Oxford)* 2015; 17: 691-699.
- [12] Benson AB, D'Angelica MI, Abbott DE, Abrams TA, Alberts SR, Saenz DA, Are C, Brown DB, Chang DT, Covey AM, Hawkins W, Iyer R, Jacob R, Karachristos A, Kelley RK, Kim R, Palta M, Park JO, Sahai V, Scheffter T, Schmidt C, Sicklick JK, Singh G, Sohal D, Stein S, Tian GG, Vauthey JN, Venook AP, Zhu AX, Hoffmann KG and Darlow S. NCCN guidelines insights: hepatobiliary cancers version 1.2017. *J Natl Compr Canc Netw* 2017; 15: 563-573.
- [13] Serenari M, Zanella M, Schadde E, Toschi E, Ratti F, Gringeri E, Masetti M, Cillo U, Aldrighetti L and Jovine E; ALPPS Italian Registry Group. Importance of primary indication and liver function between stages: results of a multicenter Italian audit of ALPPS 2012-2014. *HPB (Oxford)* 2016; 18: 419-427.
- [14] Olthof PB, Coelen RJS, Wiggers JK, Groot Koerkamp B, Malago M, Hernandez-Alejandro R, Topp SA, Vivarelli M, Aldrighetti LA, Robles Campos R, Oldhafer KJ, Jarnagin WR and van Gulik TM. High mortality after ALPPS for perihilar cholangiocarcinoma: case-control analysis including the first series from the international ALPPS registry. *HPB (Oxford)* 2017; 19: 381-387.
- [15] Wajswol E, Jazmati T, Contractor S and Kumar A. Portal vein embolization utilizing N-butyl cyanoacrylate for contralateral lobe hypertrophy prior to liver resection: a systematic review and meta-analysis. *Cardiovasc Intervent Radiol* 2018; 41: 1302-1312.
- [16] Valle JW, Borbath I, Khan SA, Huguet F, Gruenberger T and Arnold D; ESMO Guidelines Committee. Biliary cancer: ESMO Clinical Practice Guidelines for diagnosis treatment and follow-up. *Ann Oncol* 2016; 27 Suppl 5: v28-v37.
- [17] Bagante F, Gani F, Spolverato G, Xu L, Alexandrescu S, Marques HP, Lamelas J, Aldrighetti L, Gamblin TC, Maitzel SK, Pulitano C, Bauer TW, Shen F, Poultides GA, Marsh JW and Pawlik TM. Intrahepatic cholangiocarcinoma: prognosis of patients who did not undergo lymphadenectomy. *J Am Coll Surg* 2015; 221: 1031-1040.
- [18] Lendoire JC, Gil L and Inventarza O. Intrahepatic cholangiocarcinoma surgery: the impact of lymphadenectomy. *Chin Clin Oncol* 2018; 7: 53.
- [19] Edeline J, Benabdelghani M, Bertaut A, Watelet J, Hammel P, Joly JP, Boudjema K, Fartoux

## Immunotherapy in biliary tract cancers

- L, Bouhier-Leporrier K, Jouve JL, Faroux R, Guerin-Meyer V, Kurtz JE, Assénat E, Seitz JF, Baumgaertner I, Tougeron D, de la Fouchardière C, Lombard-Bohas C, Boucher E, Stanbury T, Louvet C, Malka D and Phelip JM. Gemcitabine and oxaliplatin chemotherapy or surveillance in resected biliary tract cancer (PRODIGE 12-ACCORD 18-UNICANCER G1): a randomized phase III study. *J Clin Oncol* 2019; 37: 658-667.
- [20] Primrose JN, Fox RP, Palmer DH, Malik HZ, Prasad R, Mirza D, Anthony A, Corrie P, Falk S, Finch-Jones M, Wasan H, Ross P, Wall L, Wadsley J, Evans JTR, Stocken D, Praseedom R, Ma YT, Davidson B, Neoptolemos JP, Iveson T, Raftery J, Zhu S, Cunningham D, Garden OJ, Stubbs C, Valle JW and Bridgewater J; BILCAP study group. Capecitabine compared with observation in resected biliary tract cancer (BILCAP): a randomised controlled multicentre phase 3 study. *Lancet Oncol* 2019; 20: 663-673.
- [21] Bonet Beltrán M, Allal AS, Gich I, Solé JM and Carrió I. Is adjuvant radiotherapy needed after curative resection of extrahepatic biliary tract cancers? A systematic review with a meta-analysis of observational studies. *Cancer Treat Rev* 2012; 38: 111-119.
- [22] Kim BH, Kwon J, Chie EK, Kim K, Kim YH, Seo DW, Narang AK and Herman JM. Adjuvant chemoradiotherapy is associated with improved survival for patients with resected gallbladder carcinoma: a systematic review and meta-analysis. *Ann Surg Oncol* 2018; 25: 255-264.
- [23] Ben-Josef E, Guthrie KA, El-Khoueiry AB, Corless CL, Zalupski MM, Lowy AM, Thomas CR Jr, Alberts SR, Dawson LA, Micetich KC, Thomas MB, Siegel AB and Blanke CD. SWOG S0809: a phase II intergroup trial of adjuvant capecitabine and gemcitabine followed by radiotherapy and concurrent capecitabine in extrahepatic cholangiocarcinoma and gallbladder carcinoma. *J Clin Oncol* 2015; 33: 2617-2622.
- [24] Eckel F and Schmid RM. **Chemotherapy in advanced biliary tract carcinoma: a pooled analysis of clinical trials.** *Br J Cancer* 2007; 96: 896-902.
- [25] André T, Reyes-Vidal JM, Fartoux L, Ross P, Leslie M, Rosmorduc O, Clemens MR, Louvet C, Perez N, Mehmed F and Scheithauer W. Gemcitabine and oxaliplatin in advanced biliary tract carcinoma: a phase II study. *Br J Cancer* 2008; 99: 862-867.
- [26] Harder J, Riecken B, Kummer O, Lohrmann C, Otto F, Usadel H, Geissler M, Opitz O and Henss H. Outpatient chemotherapy with gemcitabine and oxaliplatin in patients with biliary tract cancer. *Br J Cancer* 2006; 95: 848-852.
- [27] Lee J, Park SH, Chang HM, Kim JS, Choi HJ, Lee MA, Jang JS, Jeung HC, Kang JH, Lee HW, Shin DB, Kang HJ, Sun JM, Park JO, Park YS, Kang WK and Lim HY. Gemcitabine and oxaliplatin with or without erlotinib in advanced biliary-tract cancer: a multicentre open-label randomised phase 3 study. *Lancet Oncol* 2012; 13: 181-188.
- [28] Malka D, Cervera P, Foulon S, Trarbach T, de la Fouchardière C, Boucher E, Fartoux L, Faivre S, Blanc JF, Viret F, Assenat E, Seufferlein T, Herrmann T, Grenier J, Hammel P, Dollinger M, André T, Hahn P, Heinemann V, Rousseau V, Ducreux M, Pignon JP, Wendum D, Rosmorduc O and Greten TF; BINGO investigators. Gemcitabine and oxaliplatin with or without cetuximab in advanced biliary-tract cancer (BINGO): a randomised open-label non-comparative phase 2 trial. *Lancet Oncol* 2014; 15: 819-828.
- [29] Fiteni F, Nguyen T, Vernerey D, Paillard MJ, Kim S, Demarchi M, Fein F, Borg C, Bonnetain F and Pivrot X. Cisplatin/gemcitabine or oxaliplatin/gemcitabine in the treatment of advanced biliary tract cancer: a systematic review. *Cancer Med* 2014; 3: 1502-1511.
- [30] Verderame F, Russo A, Di Leo R, Badalamenti G, Santangelo D, Cicero G, Valerio MR, Gulotta G, Tomasello G, Gebbia N and Fulfaro F. Gemcitabine and oxaliplatin combination chemotherapy in advanced biliary tract cancers. *Ann Oncol* 2006; 7: 68-72.
- [31] Lamarca A, Palmer DH, Wasan HS, Ross PJ, Ma. YT, Arora A, Falk S, Gillmore R, Wadsley J, Patel K, Anthoney A, Maraveyas A, Waters JS, Hobbs C, Barber S, Ryder D, Ramage J, Davies L.M, Bridgewater JA and Valle JW. ABC-06. A randomized phase III multi-center open-label study of active symptom control (ASC) alone or ASC with oxaliplatin/5-FU chemotherapy (ASC+mFOLFOX) for patients (pts) with locally advanced/metastatic biliary tract cancers (ABC) previously-treated with cisplatin/gemcitabine (CisGem) chemotherapy. *Journal of Clinical Oncology* 2019; 37: 4003-4003.
- [32] Abou-Alfa GK, Sahai V, Hollebecque A, Vaccaro G, Melisi D, Al-Rajabi R, Paulson AS, Borad MJ, Gallinson D, Murphy AG, Oh DY, Dotan E, Catenacci DV, Van Cutsem E, Ji T, Lihou CF, Zhen H, Félix L and Vogel A. Pemigatinib for previously treated locally advanced or metastatic cholangiocarcinoma: a multicentre open-label phase 2 study. *Lancet Oncol* 2020; 21: 671-684.

## Immunotherapy in biliary tract cancers

- [33] Topalian SL, Hodi FS, Brahmer JR, Gettinger SN, Smith DC, McDermott DF, Powderly JD, Carvajal RD, Sosman JA, Atkins MB, Leming PD, Spigel DR, Antonia SJ, Horn L, Drake CG, Pardoll DM, Chen L, Sharfman WH, Anders RA, Taube JM, McMiller TL, Xu H, Korman AJ, Jure-Kunkel M, Agrawal S, McDonald D, Kollia GD, Gupta A, Wigginton JM and Sznol M. Safety activity and immune correlates of anti-PD-1 antibody in cancer. *N Engl J Med* 2012; 366: 2443-2454.
- [34] Brahmer JR, Tykodi SS, Chow LQ, Hwu WJ, Topalian SL, Hwu P, Drake CG, Camacho LH, Kauh J, Odunsi K, Pitot HC, Hamid O, Bhatia S, Martins R, Eaton K, Chen S, Salay TM, Alaparthi S, Grosso JF, Korman AJ, Parker SM, Agrawal S, Goldberg SM, Pardoll DM, Gupta A and Wigginton JM. Safety and activity of anti-PD-L1 antibody in patients with advanced cancer. *N Engl J Med* 2012; 366: 2455-2465.
- [35] Wolchok JD, Kluger H, Callahan MK, Postow MA, Rizvi NA, Lesokhin AM, Segal NH, Ariyan CE, Gordon RA, Reed K, Burke MM, Caldwell A, Kronenberg SA, Agunwamba BU, Zhang X, Lowy I, Inzunza HD, Feely W, Horak CE, Hong Q, Korman AJ, Wigginton JM, Gupta A and Sznol M. Nivolumab plus ipilimumab in advanced melanoma. *N Engl J Med* 2013; 369: 122-133.
- [36] Raval RR, Sharabi AB, Walker AJ, Drake CG and Sharma P. Tumor immunology and cancer immunotherapy: summary of the 2013 SITC primer. *J Immunother Cancer* 2014; 2: 14.
- [37] Zheng L, Xue J, Jaffee EM and Habtezion A. Role of immune cells and immune-based therapies in pancreatitis and pancreatic ductal adenocarcinoma. *Gastroenterology* 2013; 144: 1230-1240.
- [38] Pardoll DM. The blockade of immune checkpoints in cancer immunotherapy. *Nat Rev Cancer* 2012; 12: 252-264.
- [39] Walunas TL, Lenschow DJ and Bakker CY. CTLA-4 can function as a negative regulator of T cell activation. *Immunity* 1994; 1: 405-413.
- [40] Topalian SL, Drake CG and Pardoll DM. Targeting the PD-1/B7-H1 (PD-L1) pathway to activate anti-tumor immunity. *Curr Opin Immunol* 2012; 24: 207-212.
- [41] Zappasodi R, Merghoub T and Wolchok JD. Emerging concepts for immune checkpoint blockade-based combination therapies. *Cancer Cell* 2018; 33: 581-598.
- [42] Klempner SJ, Fabrizio D, Bane S, Reinhart M, Peoples T, Ali SM, Sokol ES, Frampton G, Schrock AB, Anhorn R and Reddy P. Tumor mutational burden as a predictive biomarker for response to immune checkpoint inhibitors: a review of current evidence. *Oncologist* 2020; 25: 147-159.
- [43] Jessurun CAC, Vos JAM, Limpens J and Luiten RM. Biomarkers for response of melanoma patients to immune checkpoint inhibitors: a systematic review. *Front Oncol* 2017; 7: 233.
- [44] Maleki Vareki S. High and low mutational burden tumors versus immunologically hot and cold tumors and response to immune checkpoint inhibitors. *J Immunother Cancer* 2018; 6: 157.
- [45] Nakamura H, Arai Y, Totoki Y, Shirota T, Elzawahry A, Kato M, Hama N, Hosoda F, Urushidate T, Ohashi S, Hiraoka N, Ojima H, Shimada K, Okusaka T, Kosuge T, Miyagawa S and Shibata T. Genomic spectra of biliary tract cancer. *Nat Genet* 2015; 47: 1003-1010.
- [46] Fontugne J, Augustin J, Pujals A, Compagnon P, Rousseau B, Luciani A, Tournigand C, Cherqui D, Azoulay D, Pawlotsky JM and Calderaro J. PD-L1 expression in perihilar and intrahepatic cholangiocarcinoma. *Oncotarget* 2017; 8: 24644-24651.
- [47] Zhou G, Sprengers D, Mancham S, Erkens R, Boor PPC, van Beek AA, Doukas M, Noordam L, Campos Carrascosa L, de Ruyter V, van Leeuwen RWF, Polak WG, de Jonge J, Groot Koerkamp B, van Rosmalen B, van Gulik TM, Verheij J, IJzermans JNM, Bruno MJ and Kwekkeboom J. Reduction of immunosuppressive tumor microenvironment in cholangiocarcinoma by ex vivo targeting immune checkpoint molecules. *J Hepatol* 2019; 71: 753-762.
- [48] Job S, Rapoud D, Dos Santos A, Gonzalez P, Desterke C, Pascal G, Elarouci N, Ayadi M, Adam R, Azoulay D, Denis C, Vibert E, Cherqui D, Samuel D, Sa Cuhna A, Marchio A, Pineau P, Guettier C, de Reyniès A and Faivre J. Identification of four immune subtypes characterized by distinct composition and functions of tumor microenvironment in intrahepatic cholangiocarcinoma. *Hepatology* 2019; 72: 965-981.
- [49] Bang Y, Doi T, Braud F, Piha-Paul S, Hollebecque A, Razak A, Lin C, Ott P, He A, Yuan S, Koshiji M, Lam B and Aggarwal R. 525 Safety and efficacy of pembrolizumab (MK-3475) in patients (pts) with advanced biliary tract cancer: interim results of KEYNOTE-028. *Eur J Cancer* 2015; 51.
- [50] Alshari OM, Dawaymeh TA, Tashtush NA, Aleshawi AJ, Al Manasra ARA and Obeidat KA. Completely resolved advanced biliary tract cancer after treatment by pembrolizumab: a report of two cases. *Onco Targets Ther* 2019; 12: 5293-5298.
- [51] Kang J, Jeong JH, Hwang HS, Lee SS, Park DH, Oh DW, Song TJ, Kim KH, Hwang S, Hwang DW, Kim SC, Park JH, Hong SM, Kim KP, Ryoo BY and Yoo C. Efficacy and safety of pembrolizum-

## Immunotherapy in biliary tract cancers

- ab in patients with refractory advanced biliary tract cancer: tumor proportion score as a potential biomarker for response. *Cancer Res Treat* 2020; 52: 594-603.
- [52] Lee SH, Lee HS, Lee SH, Woo SM, Kim DU and Bang S. Efficacy and safety of pembrolizumab for gemcitabine/cisplatin-refractory biliary tract cancer: a multicenter retrospective study. *J Clin Med* 2020; 9: 1769.
- [53] Uprety D. Chemoimmunotherapy for stage IV non-small-cell lung cancer. *Lancet Oncol* 2019; 20: 466.
- [54] Mou H, Yu L, Liao Q, Hou X, Wu Y, Cui Q, Yan N, Ma R, Wang L, Yao M and Wang K. Successful response to the combination of immunotherapy and chemotherapy in cholangiocarcinoma with high tumour mutational burden and PD-L1 expression: a case report. *BMC Cancer* 2018; 18: 1105.
- [55] Stenehjem D, Gupta S, Wade M, Gilcrease G, Garrido-Laguna I, Weis JR, Whisenant J and Sharma S. A phase I dose escalation trial to assess the safety and preliminary efficacy of mFOLFOX6 combined with pembrolizumab (MK3475) in advanced gastrointestinal malignancies. *Immunother Canc* 2016; 27: 367.
- [56] Gbolahan O, Hashemi-Sadraei N and O'Neil B. Prolonged response to Anti-PD-1 antibody therapy in chemotherapy-refractory cholangiocarcinoma with high tumor mutational burden. *J Natl Compr Canc Netw* 2019; 17: 644-648.
- [57] Galsky MD, Mortazavi A, Milowsky MI, George S, Gupta S, Fleming MT, Dang LH, Geynisman DM, Walling R, Alter RS, Kassir M, Wang J, Gupta S, Davis N, Picus J, Philips G, Quinn DI, Haines GK 3rd, Hahn NM, Zhao Q, Yu M and Pal SK. Randomized double-blind phase II study of maintenance pembrolizumab versus placebo after first-line chemotherapy in patients (pts) with metastatic urothelial cancer (mUC): HCRN GU14-182. *J Clin Oncol* 2019; 37: 4504.
- [58] Gou M, Zhang Y, Si H and Dai G. Efficacy and safety of nivolumab for metastatic biliary tract cancer. *Onco Targets Ther* 2019; 12: 861-867.
- [59] Sun D, Ma J, Wang J, Han C, Qian Y, Chen G, Li X, Zhang J, Cui P, Du W, Wu Z, Chen S, Zheng X, Yue Z, Song J, Gao C, Zhao X, Cai S and Hu Y. Anti-PD-1 therapy combined with chemotherapy in patients with advanced biliary tract cancer. *Cancer Immunol Immunother* 2019; 68: 1527-1535.
- [60] Ueno M, Ikeda M, Morizane C, Kobayashi S, Ohno I, Kondo S, Okano N, Kimura K, Asada S, Namba Y, Okusaka T and Furuse J. Nivolumab alone or in combination with cisplatin plus gemcitabine in Japanese patients with unresectable or recurrent biliary tract cancer: a non-randomised multicentre open-label phase 1 study. *Lancet Gastroenterol Hepatol* 2019; 4: 611-621.
- [61] Vaibhav S, Kent AG, Muhammad SB, Walid LS, Devalingam M, David BZ, Dustin AD, Sumi D, Mishal ML and Mark Z. A multicenter randomized phase II study of nivolumab in combination with gemcitabine/cisplatin or ipilimumab as first-line therapy for patients with advanced unresectable biliary tract cancer (BiIT-01). *J Clin Oncol* 2020; 15: 4582.
- [62] Yu C, Liu X, Yang J, Zhang M, Jin H, Ma X and Shi H. Combination of immunotherapy with targeted therapy: theory and practice in metastatic melanoma. *Front Immunol* 2019; 10: 990.
- [63] Moya-Horno I, Viteri S, Karachaliou N and Rosell R. Combination of immunotherapy with targeted therapies in advanced non-small cell lung cancer (NSCLC). *Ther Adv Med Oncol* 2018; 10.
- [64] Arkenau HT, Martin-Liberal J, Calvo E, Penel N, Krebs MG, Herbst RS, Walgren RA, Widau RC, Mi G, Jin J, Ferry D and Chau I. Ramucirumab plus pembrolizumab in patients with previously treated advanced or metastatic biliary tract cancer: nonrandomized open-label phase I trial (JVDF). *Oncologist* 2018; 23: 136.
- [65] Motz GT and Coukos G. The parallel lives of angiogenesis and immunosuppression: cancer and other tales. *Nat Rev Immunol* 2011; 11: 702-711.
- [66] Huang Y, Chen X, Dikov MM, Novitskiy SV, Mosse CA, Yang L and Carbone DP. Distinct roles of VEGFR-1 and VEGFR-2 in the aberrant hematopoiesis associated with elevated levels of VEGF. *Blood* 2007; 110: 624-631.
- [67] Chen WX, Li GX, Hu ZN, Zhu P, Zhang BX and Ding ZY. Significant response to anti-PD-1 based immunotherapy plus lenvatinib for recurrent intrahepatic cholangiocarcinoma with bone metastasis: a case report and literature review. *Medicine (Baltimore)* 2019; 98: 17832.
- [68] Baretta M, Walker R, Durham J, Christmas B, Cope L, Jaffee EM and Azad NS. ABO49. P-17. A phase II study of HDAC inhibition to sensitize to immunotherapy in advanced cholangiocarcinoma. *Hepatobiliary Surg Nutr* 2019; 8: ABO49.
- [69] Yarchoan M, Cope L, Anders RA, Noonan A, Goff LW, Goyal L, Lacy J, Li D, Patel A, He AR, Abou-Alfa G, Spencer K, Kim E, Xavier S, Ruggieri A, Davis SL, McRee A, Kunk P, Zhu Q, Wang-Gillam A, Poklepovic A, Chen H, Sharon E, Lesinski GB and Azad N. Abstract CT043. AACR Annual Meeting 2020.



## Immunotherapy in biliary tract cancers

- [70] Rojas-Sepúlveda D, Tittarelli A, Gleisner MA, Ávalos I, Pereda C, Gallegos I, González FE, López MN, Butte JM, Roa JC, Fluxá P and Salazar-Onfray F. Tumor lysate-based vaccines: on the road to immunotherapy for gallbladder cancer. *Cancer Immunol Immunother* 2018; 67: 1897-1910.
- [71] Feng K, Liu Y, Guo Y, Qiu J, Wu Z, Dai H, Yang Q, Wang Y and Han W. Phase I study of chimeric antigen receptor modified T cells in treating HER2-positive advanced biliary tract cancers and pancreatic cancers. *Protein Cell* 2018; 9: 838-847.