

## Renal cell carcinoma: ESMO Clinical Practice Guidelines for diagnosis, treatment and follow-up<sup>†</sup>

B. Escudier<sup>1</sup>, C. Porta<sup>2</sup>, M. Schmidinger<sup>3</sup>, N. Rioux-Leclercq<sup>4</sup>, A. Bex<sup>5</sup>, V. Khoo<sup>6,7</sup>, V. Gruenvald<sup>8</sup> & A. Horwich<sup>9</sup> on behalf of the ESMO Guidelines Committee\*

<sup>1</sup>Department of Medical Oncology, Gustave Roussy, Villejuif, France; <sup>2</sup>IRCCS San Matteo University Hospital Foundation, Pavia, Italy; <sup>3</sup>Department of Medicine I, Clinical Division of Oncology and Comprehensive Cancer Center, Medical University of Vienna, Vienna, Austria; <sup>4</sup>Department of Pathology, Rennes Hospital and University, Rennes, France; <sup>5</sup>Division of Surgical Oncology—Urology, The Netherlands Cancer Institute, Amsterdam, The Netherlands; <sup>6</sup>Institute of Cancer Research, Royal Marsden Hospital, London, UK; <sup>7</sup>University of Melbourne and Monash University, Victoria, Australia; <sup>8</sup>Clinic for Hematology, Hemostasis, Oncology and Stem Cell Transplantation, Medical School Hanover, Hanover, Germany; <sup>9</sup>The Institute of Cancer Research, London, UK

### incidence and epidemiology

Kidney cancer accounts for 5% and 3% of all adult malignancies in men and women, respectively, thus representing the 7th most common cancer in men and the 10th most common cancer in women [1]. However, available statistics include not only renal parenchymal tumours, but also urothelial cancer of the renal pelvis; renal cell carcinoma (RCC) accounts for ~80% of all kidney cancers.

After over two decades of increasing rates, RCC incidence trends worldwide have shown signs of plateauing or decreasing in recent years. Furthermore, kidney cancer mortality rates overall have levelled. These patterns are consistent with reports of incidental diagnosis and downward shift of tumour stage and size; indeed, the widespread use of non-invasive radiological techniques [e.g. ultrasonography (US), computed tomography (CT)] allows the frequent detection of early and small RCCs, which are potentially curable.

Beyond well-known risk factors for RCC, such as cigarette smoking, obesity and hypertension, evidence is accumulating to suggest an aetiological or, on the contrary, a protective role, for additional factors [2], such as trichloroethylene. Furthermore, RCC also appears to be more common in patients with end-stage renal failure or acquired renal cystic disease, and in patients on dialysis, those who have had kidney transplantation, or those with tuberous sclerosis syndrome.

Approximately 2%–3% of all RCCs are hereditary and several autosomal dominant syndromes are described, each with a distinct genetic basis and phenotype, the most common one being Von Hippel Lindau (VHL) disease.

### diagnosis

As stated above, >50% of RCCs are currently detected incidentally, making the classical triad of flank pain, gross haematuria and palpable abdominal mass less frequent than in the past. Despite this, RCC remains the ‘Internist’s cancer’ with paraneoplastic syndromes such as hypercalcaemia, unexplained fever, erythrocytosis and Stauffer’s syndrome (signs of cholestasis unrelated to tumour infiltration of the liver or intrinsic liver disease, which typically resolve after kidney tumour resection), still being relatively frequent.

Suspicion of RCC should prompt laboratory examinations of serum creatinine, haemoglobin, leukocyte and platelet counts, lymphocyte to neutrophil ratio, lactate dehydrogenase, C-reactive protein (CRP) and serum-corrected calcium, in addition to other symptom-derived tests [IV, B]. Some of these tests are prognosticators for survival and are used for risk assessment within different prognostic score systems (see later).

Most cases of RCC are strongly suspected by imaging. Diagnosis is usually suggested by US and further investigated by CT scan, which allows for assessment of local invasiveness, lymph node involvement, or distant metastases. Magnetic resonance imaging (MRI) may provide additional information in investigating local advancement and venous involvement by tumour thrombus.

For accurate staging of RCC, contrast-enhanced chest, abdominal, and pelvic CT is mandatory [III, A]; unless indicated by clinical or laboratory signs or symptoms, the use of bone scan or CT (or MRI) of the brain is not recommended for routine clinical practice [III, A]. In case of an allergy to CT contrast medium, adequate staging should include a high-resolution CT scan of the chest without contrast medium, together with an abdominal MRI. <sup>18</sup>Fluorodeoxyglucose-positron emission tomography (<sup>18</sup>FDG-PET) is not a standard investigation in the diagnosis and staging of clear cell RCC (ccRCC) and should not be used. The role of new tracers is under investigation only.

A renal tumour core biopsy provides histopathological confirmation of malignancy with high sensitivity and specificity; it

\*Correspondence to: ESMO Guidelines Committee, ESMO Head Office, Via L. Taddei 4, 6962 Viganello-Lugano, Switzerland.  
E-mail: clinicalguidelines@esmo.org

<sup>†</sup>Approved by the ESMO Guidelines Committee: September 2008, last update August 2016. This publication supersedes the previously published version—Ann Oncol 2014; 25 (Suppl. 3): iii49–iii56.

is especially recommended before treatment with ablative therapies [III, B] as well as in patients with metastatic disease before starting systemic treatment [III, B]. Nowadays, complications (e.g. bleeding or tumour seeding) are rare or even exceptional (as in the case of tumour seeding) [3], while diagnostic accuracy remains high [4]. The final histopathological diagnosis, classification, grading and evaluation of prognostic factors are based on the nephrectomy specimen when available.

## pathology assessment

The new edition of the World Health Organization (WHO) histological classification of renal tumours has been recently reported (Table 1) and was based on tumour histology, chromosomal alterations and molecular pathways [5]. Changes in the 2016 WHO classification are as follows:

- The molecular genetic profile of ccRCC is characterised in >80% of sporadic cases, by biallelic VHL gene alterations: VHL gene mutations, hypermethylation of VHL gene promoter, and loss of heterozygosity. Mutations in chromatin remodelling genes have also been reported (*PBRM1*: 41%, *BAP1*: 8%–10%, and *SETD2*: 11.5%) and are associated with an increased risk of ccRCC-related death.
- Multilocular cystic ccRCC has been renamed as multilocular cystic renal neoplasia of low malignant potential due to its indolent behaviour.
- Even though papillary RCC are histologically and cytogenetically defined by two main subtypes, type 1 and type 2, they represent a heterogeneous disease including tumours with indolent outcome and tumours with aggressive and lethal phenotype. RCCs associated with the hereditary leiomyomatosis are usually type 2 papillary RCC and have a poor prognosis with a high risk of dissemination.
- The oncocytic variant of papillary RCC should be reclassified as type 1 (mainly) or type 2 papillary RCC.

**Table 1.** WHO 2016 classification of renal cell tumours

Clear cell renal cell carcinoma
Multilocular cystic renal neoplasm of low malignant potential
Papillary renal cell carcinoma
Hereditary leiomyomatosis and renal cell carcinoma-associated renal cell carcinoma
Chromophobe renal cell carcinoma
Collecting duct carcinoma
Renal medullary carcinoma
MiT family translocation renal cell carcinoma
Succinate dehydrogenase-deficient renal cell carcinoma
Mucinous tubular and spindle cell carcinoma
Tubulocystic renal cell carcinoma
Acquired cystic disease-associated renal cell carcinoma
Clear cell papillary renal cell carcinoma
Unclassified renal cell carcinoma
Papillary adenoma
Oncocytoma

Reprinted with permission from Moch et al. [5].  
WHO, World Health Organization.

- In the 2004 WHO classification of RCC, the maximum size of papillary adenoma was 5 mm. From now, papillary adenoma is defined as a papillary renal tumour  $\leq 15$  mm in its largest dimension.
- The main prognostic factors in chromophobe RCC are tumour stage, the presence of necrosis, a sarcomatoid and/or rhabdoid component and small vessel invasion.
- Hybrid tumours present overlapping features of oncocytomas and chromophobe RCC. They have indolent behaviour and are usually observed in Birt–Hogg–Dubé syndrome.
- The diagnosis of the highly aggressive collecting duct carcinoma is based on six histological features: medullary location, infiltrative growth pattern, tubular architecture, desmoplastic stromal reaction, high-grade atypia and that the tumour is neither an RCC nor a transitional cell carcinoma.
- Renal medullary carcinoma occurs in young patients with sickle traits and is histologically similar to collecting duct carcinoma.
- MiTF translocation RCCs harbour gene fusions involving mainly *TFE3* and *TFEB* genes, and occur in young patients. The median age at diagnosis is 31 years. The diagnosis is based on a strong nuclear *TFE3/TFEB* immunoreactivity and the presence of a translocation involving *TFE3* or *TFEB* genes: t(X;1)(p11.2;q21) and t(6,11)(p21;q12), respectively.
- Among angiomyolipomas (AMLs), epithelioid AML is now recognised as a separate entity with a risk of progression or metastasis. The prognostic factors for the risk of progression are association with tuberous sclerosis, multiple AML, the presence of necrosis, tumour size >7 cm, extrarenal extension and/or renal vein invasion and the presence of a carcinoma-like growth pattern.
- Two new entities are now recognised:
  - o acquired cystic disease-associated RCCs that have indolent outcome and occur in patients with end-stage renal disease and acquired cystic disease and
  - o succinate dehydrogenase (SDH)-deficient RCCs that occur in patients with germline mutations in an *SDH* gene, leading to a dysfunction of mitochondrial complex II.

The prognostic factors validated by the International Society of Urological Pathology (ISUP) consensus, and the new WHO 2016 classification of RCC, and to be reported in routine practice are as follows [6]:

- The tumour histological subtype
- The ISUP nucleolar grading system that should be applied only to ccRCC and papillary RCC
- A sarcomatoid and/or rhabdoid differentiation that defines a grade 4 tumour
- The presence of necrosis
- The presence of microscopic vascular invasion
- The pTNM staging

## biology

Beyond the classical one gene–one histology paradigm, a more complex biological classification of RCC (and especially of its clear cell histotype) is currently emerging [7].

First, RCC proved to be an extremely heterogeneous disease [8]; beyond the seminal genetic alteration (mutation, deletion or hypermethylation) of the *VHL* tumour suppressor gene, which is present in the vast majority of sporadic RCCs, other genetic alterations may occur, especially over time [9], contributing to worsen the prognosis of patients harbouring these tumours. Notably enough, three of these other genes (*PBRM1*, *BAP1*, and *SETD2*) are located on the same short arm of chromosome 3 where the *VHL* gene is also located. Genetic abnormalities to these genes seem to increase tumour aggressiveness [10], defining these cancers as ‘diseases of chromosome 3p’.

On the contrary, some RCCs are characterised by mutations in the mTOR pathway and especially in the highly conserved FAT (FRAP–ATM–TTRAP) and kinase domains of the *MTOR* gene; these cancers have been defined as metabolic RCCs [11]. When metastatic, they are thought to be more sensitive to mTOR inhibitors [12].

Finally, according to another comprehensive molecular characterisation of papillary RCCs, type 1 and type 2 papillary RCCs were shown to be clinically and biologically distinct. Alterations in the MET pathway were indeed associated with type 1, and activation of the NRF2–ARE pathway was associated with type 2, while *CDKN2A* loss, and a CpG island methylator phenotype in type 2 contributed to convey a poor prognosis. Based on this genomic profile, type 2 papillary RCC consisted of at least three subtypes based on molecular and phenotypic features [13].

Finally, some of the escape mechanisms, namely cMET (cabozantinib) and FGF (fibroblast growth factor, lenvatinib) activation, have been used to develop new strategies in vascular endothelial growth factor (VEGF) refractory patients.

## staging and risk assessment

### staging

The American Joint Committee on Cancer (AJCC)/Union for International Cancer Control (UICC) tumour–node–metastasis (TNM) staging system should be used (Table 2).

### risk assessment

The natural clinical course varies in RCC, which has led to the development of different prognostic models for the assessment of the patient’s individual risk. Extent of disease, histology, grading and clinical factors have been recognised as having prognostic value in RCC and may be used in localised or metastatic disease [5].

*localised disease.* Different pre- or postoperative scores have been applied to assess prognosis in RCC, which are used for risk-adapted follow-up strategies. Integrated prognostic scores offer some predictive advantages over single tumour characteristics and are used preferentially. These models are composed of histological and clinical factors. The most recent modifications of the stage, size, grade and necrosis (SSIGN) score [14] (Table 3) and the University of California Los Angeles Integrated Staging System (UISS) (Table 4) [15] score are frequently used.

However, among different prognostic scores, a concordance of 0.68–0.89 for cancer-specific survival (CSS) and 0.74–0.82 for

recurrence-free survival was reported [16], indicating that a plateau has been reached for prognostication with available models. Hence, no clear preference for a specific prognostic model may be given.

*advanced disease.* The Memorial Sloan Kettering Cancer Centre (MSKCC) was the gold standard for the risk assessment during cytokine treatment in metastatic (m)RCC [17]. Its applicability to targeted agents was shown more recently [18]. Further refinement was introduced with the International Metastatic RCC Database Consortium (IMDC) score, which extended the previous factors to a total number of 6 to increase concordance [19, 20]:

- Karnofsky performance status (PS) <80%
- Haemoglobin <lower limit of normal
- Time from diagnosis to treatment of <1 year
- Corrected calcium above the upper limit of normal
- Platelets greater than the upper limit of normal
- Neutrophils greater than the upper limit of normal

A recent evaluation of this model in second-line treatment underscored its predictive value in previously treated mRCC [21] (Table 5).

*molecular prognostication.* Gene signatures were known to detect different risk groups in RCC [22]. More recently, a 16-gene assay was shown to improve prediction of recurrence-free survival in localised RCC compared with the SSIGN score according to Leibovich (concordance: 0.81 versus 0.74) [23].

These data indicate that molecular analysis may exert additional benefit to already established clinical and histo-anatomical parameters, which may lead to an individual risk assessment in the future. Other putative markers such as circulating DNA, microRNA or DNA methylation status were shown to have prognostic relevance in RCC and warrant future investigation. As of today, no specific molecular marker can be recommended for clinical use.

## management of local/locoregional disease

A summary of the recommendations for treatment of localised and locally advanced disease is shown in Table 6.

### T1 tumours (<7 cm)

- Partial nephrectomy (PN) is recommended as the preferred option in organ-confined tumours measuring up to 7 cm (elective indication). This is based on a systematic review including multiple retrospective studies and a prospective randomised, controlled trial (RCT) which compared radical nephrectomy (RN) with PN in solitary T1a–b N0M0 renal tumours <5 cm with normal contralateral kidney function [I, A] [24].
- PN can be carried out via open, laparoscopic or laparoscopic robot-assisted approaches.
- Laparoscopic RN is recommended if PN is not technically feasible.

**Table 2.** Staging of RCC (AJCC/UICC TNM classification of malignant tumours, 7th edition)

Primary tumour (T)			
TX	Primary tumour cannot be assessed		
T0	No evidence of primary tumour		
T1	Tumour ≤7 cm in greatest dimension, limited to the kidney		
T1a		Tumour ≤4.0 cm	
T1b		Tumour >4.0 cm but ≤7.0 cm	
T2	Tumour >7.0 cm in greatest dimension, limited to the kidney		
T2a		Tumour >7 cm but ≤10 cm	
T2b		Tumour >10 cm, limited to the kidney	
T3	Tumour extends into major veins or perinephric tissues but not into the ipsilateral adrenal gland and not beyond Gerota's fascia		
T3a		Tumour grossly extends into the renal vein or its segmental (muscle containing) branches, or tumour invades perirenal and/or renal sinus fat (peripelvic) but not beyond Gerota's fascia	
T3b		Tumour grossly extends into the vena cava below the diaphragm	
T3c		Tumour grossly extends into the vena cava above the diaphragm or invades the wall of the vena cava	
T4	Tumour invades beyond Gerota's fascia (including contiguous extension into the ipsilateral adrenal gland)		
Regional lymph nodes (N)			
NX	Regional lymph nodes cannot be assessed		
N0	No regional lymph node metastasis		
N1	Metastasis in regional lymph node(s)		
N2	More than one lymph node involved		
Distant metastases (M)			
cM0	Clinically no distant metastasis		
cM1	Clinically distant metastasis		
pM1	Pathologically proven distant metastasis, e.g. needle biopsy		
Anatomic stage/prognostic groups			
Stage I	T1	N0	M0
Stage II	T2	N0	M0
Stage III	T1–2	N1	M0
	T3	Any	M0
Stage IV	T4	Any	M0
	Any	Any	M1

Used with the permission of the American Joint Committee on Cancer (AJCC), Chicago, IL, USA. The original source for this material is the AJCC Cancer Staging Handbook, 7th edition (2010) published by Springer Science and Business Media LLC, [www.springerlink.com](http://www.springerlink.com).  
RCC, renal cell carcinoma; AJCC, American Joint Committee on Cancer; UICC, Union for International Cancer Control; TNM, tumour–node–metastases.

- In patients with compromised renal function, solitary kidney or bilateral tumours, PN is also the standard of care, with no tumour size limitation (imperative indication).
- Systematic reviews comparing surgical management of localised RCC (T1–2N0M0) were unable to identify prospective comparative studies reporting on oncological outcomes for minimally invasive ablative procedures compared with RN [24].
- Radio frequency ablation (RFA) or cryoablation (CA) treatments are options in patients with small cortical tumours (≤3 cm), especially for patients who are frail, present a high surgical risk and those with a solitary kidney, compromised renal function, hereditary RCC or multiple bilateral tumours. Renal biopsy is recommended to confirm malignancy and subtype in this setting.
- Systematic reviews of RFA and PN suggest that RFA has a long-term CSS equal to PN with a low metastasis rate but slightly higher local recurrence rate compared with PN and CA [25]. The quality of the available evidence prevents definitive conclusions regarding morbidity and oncological outcomes for RFA and CA [III].
- Active surveillance is an option in elderly patients with significant co-morbidities or those with a short-life expectancy and solid renal tumours measuring <40 mm. The growth of renal tumours (mean 3 mm/year) is low in most cases, and progression to metastatic disease is reported in 1%–2% [26]. Renal biopsy is recommended to select patients with small masses for active surveillance [III] with high accuracy [3, 4].

**Table 3.** SSIGN score for localised RCC [14]

Features	Score	
Pathological T category of primary tumour (TNM 2002)		
pT1a	0	
pT1b	2	
pT2	3	
pT3a-4	4	
Regional lymph node status (TNM 2002)		
pNx or pN0	0	
pN1 or pN2	2	
Tumour size		
<10 cm	0	
10 cm or more	1	
Nuclear grade		
1 or 2	0	
3	1	
4	3	
Histological tumour necrosis		
No	0	
Yes	1	
Scores	Group	5-year metastasis-free survival
0-2	Low risk	97.1%
3-5	Intermediate risk	73.8%
6 or more	High risk	31.2%

Reprinted from [14], with permission from John Wiley & Sons, Inc. SSIGN, size, stage, grade, and necrosis; RCC, renal cell carcinoma; TNM, tumour-node-metastases.

**T2 tumours (>7 cm)**

Laparoscopic RN is the preferred option.

**locally advanced RCC (T3 and T4)**

- Open RN remains the standard of care even though a laparoscopic approach can be considered.
- Systematic adrenalectomy or extensive lymph node dissection is not recommended when abdominal CT shows no evidence of adrenal or lymph node invasion [27].
- The evidence regarding management of venous tumour thrombus is based on retrospective studies with significant risks of bias and confounding. Resection of venous thrombi is challenging and associated with a high risk of complications. Surgical intervention should be considered, but the most effective approach remains unknown and outcome depends on tumour thrombus level [III].
- Currently, there is no evidence from randomised phase III trials that adjuvant therapy is of survival benefit or prolongs disease-free survival (DFS). Several RCTs of adjuvant sunitinib, sorafenib, pazopanib, axitinib and everolimus are ongoing. Data from a large adjuvant trial of sunitinib versus sorafenib versus placebo were reported in 2015 (ASSURE) after an interim analysis carried out with 62% information. Results demonstrated no significant differences in DFS or overall survival (OS) between the experimental arms and

**Table 4.** UISS (UCLA Integrated Staging System)

Patient group	Prognostic group			
	T stage	Fuhrman's grade	ECOG status	5-year disease-specific survival
Localized disease (N0, M0)				
Low risk	1	1-2	0	91.1%
Intermediate risk	1	1-2	1 or more	80.4%
	2	3-4	Any	
	3	Any	Any	
	3	1	Any	
High risk	3	2-4	1 or more	54.7%
	4	Any	Any	
Metastatic disease				
Low risk	N <sub>1</sub> M <sub>0</sub>	Any	Any	32%
	N <sub>2</sub> M <sub>0</sub> /M <sub>1</sub>	1-2	0	
Intermediate risk	N <sub>2</sub> M <sub>0</sub> /M <sub>1</sub>	1-2	1 or more	19.5%
		3	0, 1, or more	
		4	0	
High risk	N <sub>2</sub> M <sub>0</sub> /M <sub>1</sub>	4	1 or more	0%

Risk groups and 5-year disease-specific survival. UCLA, University of California Los Angeles; ECOG, Eastern Cooperative Oncology Group.

**Table 5.** Median overall survival estimates in first- and second-line according to IMDC risk groups

Number of risk factors	Risk category	First-line [8] median OS (months)	Second-line [9] median OS (months)
0	Favourable	43.2	35.3
1-2	Intermediate	22.5	16.6
3-6	Unfavourable	7.8	5.4

IMDC, International Metastatic RCC Database Consortium; OS, overall survival; RCC, renal cell carcinoma.

- placebo [28]. However, recently a press release announced that the S-TRAC trial, comparing sunitinib to placebo in high-risk localised RCC, met its primary end point. Full data should be presented at the ESMO 2016 meeting. Depending on these data, the role of sunitinib in the adjuvant setting will have to be discussed. Neoadjuvant approaches are experimental and should not be proposed outside clinical trials.
- Attempting to downsize venous tumour thrombi with systemic targeted therapy cannot be recommended.

**management of metastatic disease**

**role of surgery and local therapy**

- In the era of immunotherapy, cytoreductive nephrectomy was recommended in patients with good PS [I, A] [29]. Whether

**Table 6.** Recommendations for the treatment of localised and locally advanced RCC

	Level of evidence and grade of recommendation
Partial nephrectomy is recommended for the treatment of all T1 tumours if negative margins are obtained and risk of morbidity is acceptable.	III, C
Laparoscopic radical nephrectomy is the preferred option for the treatment of organ-confined RCC (stages T1T2N0NxM0) when partial nephrectomy is not feasible.	II, B
Routine adrenalectomy and lymph node dissection are not required for all radical nephrectomies.	III, D
Open radical nephrectomy with the goal of obtaining negative margins is still the standard of care for locally advanced RCC.	III, C
Ablative treatments are options in patients with small cortical tumours ( $\leq 3$ cm) and age $>70$ years, high surgical risk, solitary kidney, compromised renal function, hereditary RCC or multiple bilateral tumours.	III, C

RCC, renal cell carcinoma.

this recommendation will remain with current targeted therapies is currently being investigated in two prospective trials. In routine practice, cytoreductive nephrectomy is recommended in patients with good PS and large primary tumours with limited volumes of metastatic disease and for patients with a symptomatic primary lesion. Cytoreductive nephrectomy is not recommended in patients with poor PS [III, B].

- Metastectomy and other local treatment strategies including whole brain radiotherapy (WBRT), conventional radiotherapy, stereotactic radiosurgery (SRS), stereotactic body radiotherapy (SBRT), cyberknife radiotherapy and hypofractionated radiotherapy can be considered and carried out for selected patients after multidisciplinary review. A recent systematic review of 16 studies including 2350 patients sought to identify the evidence base for local treatment strategies of metastases from RCC [25]. The results consistently point towards a benefit of complete metastectomy for OS and CSS. No systemic treatment is recommended after metastectomy.
- No general guidelines can be given as to whether a patient should be referred for local treatment of metastases. Patient selection should be discussed in a multidisciplinary team. Good PS, solitary or oligo metastases, metachronous disease with disease-free interval  $>2$  years, the absence of progression on systemic therapy, low or intermediate Fuhrmann grade and complete resection have been associated with favourable outcome after local treatment of metastases from RCC.

### systemic treatment

An algorithm for systemic treatment in mRCC is presented in Figure 1.

Recommendations mainly relate to clear cell histology, since most of the pivotal trials have been done in this common histological subtype. In addition, recommendations will differ according to risk stratification (see above).

The time to start systemic therapy is not well defined. Because some RCCs have a very indolent course, a period of observation before starting treatment should be considered, especially in patients with limited tumour burden and few symptoms. Indeed, the outcome of patients who crossed over to an active agent after a brief period of treatment with placebo, within placebo-controlled phase III trials, indirectly supports this

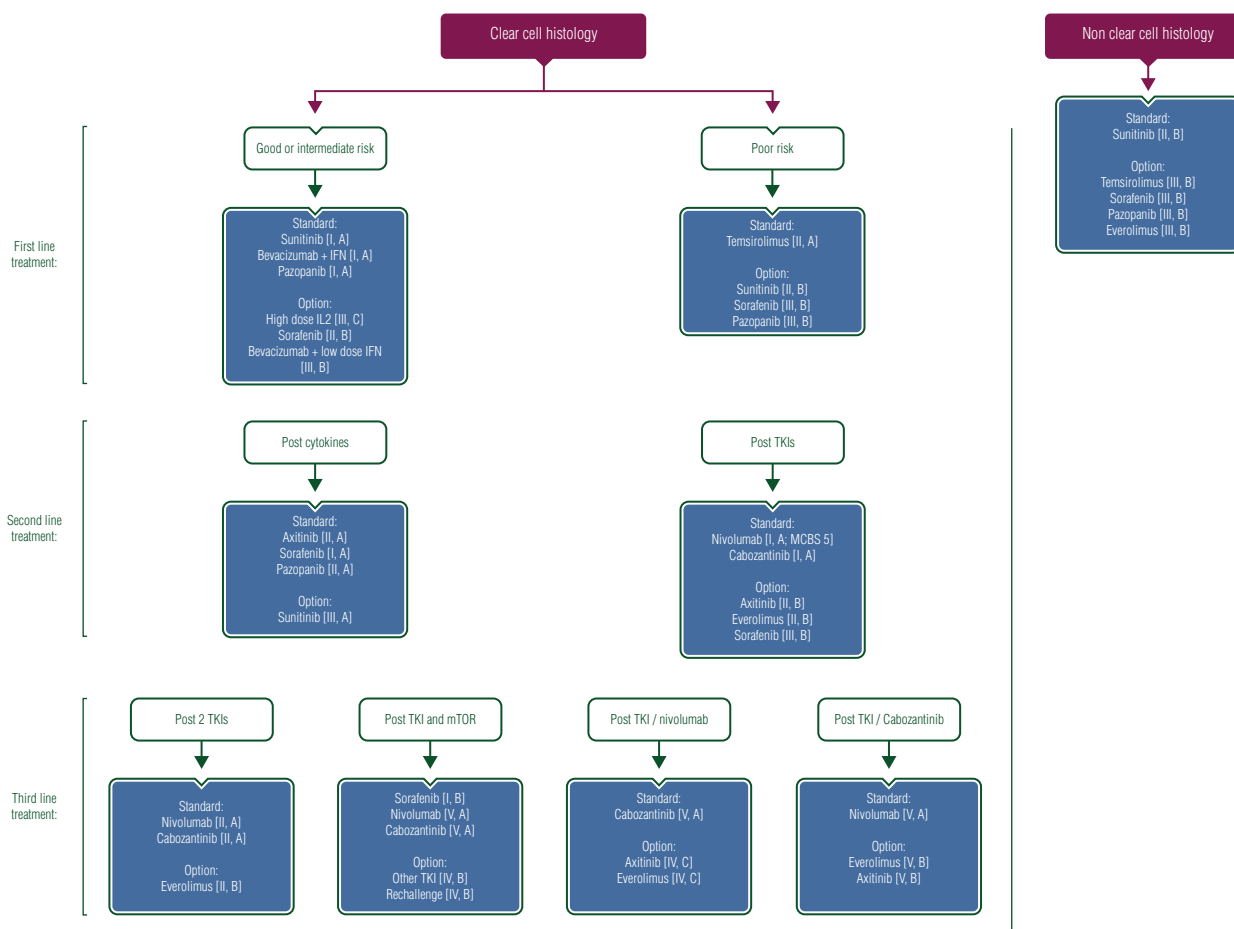
option [II, C]. The safety of observation has also been suggested by retrospective and prospective studies.

#### *first-line treatment of patients with good or intermediate prognosis.*

- Three treatments have demonstrated efficacy in pivotal phase III trials: bevacizumab (combined with interferon), sunitinib and pazopanib [30–32]. All three drugs have been registered based on improvement of progression-free survival (PFS) over either interferon or placebo. More recently, pazopanib has been shown not to be inferior to sunitinib in a large phase III trial [33]. Efficacy of both sunitinib and pazopanib has been confirmed by real-world evidence studies. These two tyrosine kinase inhibitors (TKIs) are currently the most commonly used treatments. Considering all of the published trials, the level of recommendation is considered to be [I, A] for all three regimens.
- Sorafenib [II, B], high-dose interleukin-2 [III, C], and low-dose interferon combined with bevacizumab [III, A] are alternative options.
- Single-agent interferon-alpha, as the inferior arm of three RCTs, should no longer be regarded as a standard option [I, D]. There is currently no evidence that new checkpoint inhibitors should be used in first line, although numerous ongoing trials are exploring their role, either as monotherapy or in combination (with either VEGF inhibitors or other checkpoint inhibitors).
- Interestingly, very recently, cabozantinib has been reported to be superior to sunitinib in a randomised phase 2 trial. If these results are confirmed, the role of cabozantinib in the first-line setting will have to be assessed.

#### *first-line treatment of patients with poor prognosis.*

- Temsirolimus is currently the only drug tested in a phase III study, demonstrating evidence of activity in this patient population [II, A] [34]. The pivotal trial demonstrated improvement of OS compared with interferon or the combination of temsirolimus and interferon.
- Based on subgroup analysis from the pivotal trial, as well as expanded access programmes, sunitinib is another reasonable



**Figure 1.** Algorithm for systemic treatment in mRCC. mRCC, metastatic renal cell carcinoma; IFN, interferon; IL2, interleukin 2; TKI, tyrosine kinase inhibitor; mTOR, mammalian target of rapamycin; MCBS, ESMO Magnitude of Clinical Benefit Scale v1.0.

- option in this setting [II, B]. Sorafenib as well as pazopanib, based on expanded access programmes or real-world evidence studies, are other possible alternatives [III, B].
- There is no clear recommendation on whether temsirolimus or TKIs should be used in poor risk patients, although TKIs are more commonly used in patients with good PS (expert opinion). The advantage of using TKIs in this setting will be to use second-line recommendations below, as some patients in the second-line trials were in the poor prognostic group.
- It is clear that, for some poor prognosis patients, best supportive care remains the only suitable treatment option.

*second-line treatment.*

- Evidence that TKIs are active after cytokines has been seen with sorafenib [I, A], pazopanib [II, A] and, recently, axitinib [II, A] [32, 35, 36]. Sunitinib also has activity in this setting [III, A]. However, since VEGF-targeted therapy is now the first-line standard of care, the number of patients treated with cytokines is decreasing.
- After first-line treatment with VEGF-targeted therapy,
  - Both axitinib [II, B] and everolimus [II, B] are active [36, 37]. Both drugs have shown significantly improved PFS over sorafenib (axitinib) or placebo (everolimus).

- Based on recent phase III trials, sorafenib can also be used as an option [III, B].
- However, second-line treatment has recently been dramatically modified by the report of two large trials showing improvement in OS with nivolumab [an anti-programmed death 1 (PD-1) inhibitor] and cabozantinib [38–40] over everolimus. Both trials showed very significant improvement in OS and response rate, while PFS was improved only in the cabozantinib trial. In both trials, patients could be treated after either one or two TKIs.
- Obviously, availability of these two drugs is still very limited, and several situations should be differentiated:
  - Only nivolumab is available: It should be recommended [I, A; ESMO-Magnitude of Clinical Benefit Scale (MCBS) v1.0 score: 5].
  - Nivolumab and cabozantinib are both available: either drug is recommended [I, A; ESMO-MCBS v1.0 score: 5 (nivolumab)]
  - Neither of these drugs is available: either everolimus [II, B] or axitinib [II, B] can be used.
- Of note, the combination of lenvatinib and everolimus has recently been approved by the FDA (Food and Drug Administration) based on a randomised study of 150 patients,

Downloaded from <http://annonc.oxfordjournals.org/> at Biblioteca IRCCS Policlinico San Matteo - Pavi on October 20, 2016

showing PFS and OS benefit over everolimus [41]. Recently in Europe, the CHMP (Committee for Medicinal Products for Human Use) gave a positive opinion for this combination. However, based on the size of this study, this combination cannot, at this stage, be added to current European guidelines.

- Finally, the optimal duration of treatment, especially for nivolumab, remains questionable, as well as the benefit of treatment beyond progression.

*third-line treatment.* Beyond second-line treatment, enrolment into clinical trials is recommended where possible. However, based on recent trials with nivolumab and cabozantinib, different situations should be defined:

- In patients already treated with two TKIs, either nivolumab or cabozantinib is recommended [II, A]. If neither of these drugs is available, everolimus remains the standard option [II, B]
- In patients previously treated with one TKI and nivolumab, cabozantinib is recommended, if available [V, A]. In the absence of cabozantinib, either everolimus or axitinib can be used [IV, C].
- In patients previously treated with one TKI and cabozantinib, nivolumab is recommended [V, A], and either everolimus or axitinib remains an acceptable option [V, B].
- In patients previously treated with VEGF-targeted therapy and an mTOR inhibitor, sorafenib [II, B] has shown activity [42]. In addition, nivolumab or cabozantinib can be recommended in this setting [V, A]. Finally, another TKI or rechallenge with the same TKI is considered as an option [IV, B].

*medical treatment of metastatic disease of non-clear cell histology.* For these patients, enrolment into specifically designed clinical trials is strongly recommended. However, small prospective trials as well as subgroup analyses from larger trials have recently been reported [43–45]. In these trials, sunitinib and everolimus have been compared, and in every trial, there is a trend in favour of sunitinib. In addition, some recommendations can be provided according to the results of the expanded access programmes of sunitinib and sorafenib, of small retrospective studies, and of the subgroup analysis of the temsirolimus registration trial. Overall, sunitinib has the most reproducible efficacy [II, B]. These studies also suggest that patients with non-clear cell histology may benefit from treatment with everolimus [III, B], sorafenib, pazopanib or temsirolimus [III, B]. However, in most of these studies, only patients with papillary and chromophobe tumours were enrolled.

In the absence of prospective data, genetic considerations may influence treatment decisions: in papillary type 1 tumours, activation of the c-MET pathway has commonly been reported. Novel agents inhibiting the cMET receptor are currently under investigation. However, as the c-MET receptor and VEGF-receptor were shown to cooperate, VEGF-inhibiting agents may be a reasonable choice. Similarly, there is no evidence for the optimal treatment of papillary type 2, which is characterised by inactivation of the fumarate-hydratase gene, fumarate accumulation and HIF upregulation. Again, VEGF inhibitors may be considered in this context. Patients with chromophobe RCC may benefit from mTOR inhibitors since mutation on

chromosome 7 was shown to lead to a loss of the folliculin gene with up-regulation of mTOR. Finally, collecting duct tumours (and also medullary carcinomas) were reported to behave more like aggressive urothelial tumours rather than RCCs and may therefore be considered for chemotherapy. None of these ‘genetic’ recommendations can be graded, as data are limited and no clear treatment recommendation can be made for these subgroups with distinct biology.

### role of radiotherapy and bisphosphonates

The spectrum of radiosensitivity in RCC is wide, but it is not a radioresistant disease. Radiotherapy has been shown to provide good symptom palliation and local control in RCC depending on the dose that can be delivered [46]. There is a developing rationale with emerging data suggesting that the apparent radioresistance of RCC can be overcome through the ceramide pathway with the use of higher dose per fraction treatments usually delivered by new high-precision radiotherapy methods such as SBRT [IV, B] [47]. This can be exploited and used in many different clinical situations particularly for unresectable local recurrences or oligometastatic disease.

- There is no current evidence for the use of radiotherapy in the neoadjuvant or adjuvant setting. This is on the basis of four negative ‘old’ trials with two pre-operative and two adjuvant studies. Despite being randomised trials, there are several major limitations in trial design and methodology that included inappropriate case selection, sub-therapeutic radiotherapy regimes and inadequate patient numbers. Furthermore, treatment morbidity was substantially high and the radiotherapy techniques used then have now been superseded by improved modern irradiation methods such as intensity-modulated radiotherapy or SBRT [II, D].
- Radiotherapy can be used to treat unresectable local or recurrent disease with the aim of improving local control. For patients in whom surgery cannot be carried out due to poor PS or unsuitable clinical condition, radiotherapy can be an alternative if other local therapies such as radioablation are not appropriate. Modern image-guided radiotherapy techniques are needed to enable a high biological dose to be delivered, such as volumetric modulated arc therapy (VMAT) or SBRT [IV, B]. As discussed earlier, there is an emerging role for its use in the synchronous or metachronous development of oligometastatic mRCC disease, oligoprogression or in mixed response scenarios with immuno- or targeted therapies [IV, B].
- Radiotherapy is an effective treatment for palliation of local and symptomatic mRCC disease or to prevent the progression of metastatic disease in critical sites: bones, brain [I, A]. For symptomatic bone metastasis, local radiotherapy (either as a single fraction or as fractionated course) can provide good symptom relief in up to two-thirds of cases with complete symptomatic responses in up to 20%–25% [I, A].
- For the management of spinal cord compression, an ambulatory status at diagnosis and limited metastatic disease are favourable prognostic factors in those patients able to undergo surgery. The use of initial surgery and postoperative radiotherapy was reported in a randomised trial to improve survival and maintenance of ambulation compared with irradiation alone [48–50] [I, A].



• In the management of mRCC patient with brain metastases, the use of corticosteroids can provide effective temporary relief of cerebral symptoms. WBRT between 20 and 30 Gy in 4–10 fractions, respectively, is effective for symptom control [II, B]. Most trials in brain metastasis include only a small proportion of RCC cases [48–50]. With the use of SRS delivering larger doses per fraction, the mRCC response outcomes are not thought to differ from other solid tumours. For the subset of good prognosis patients with a single unresectable brain metastasis, SRS with or without WBRT should be considered [II, A]. There is less reported late cognitive dysfunction using SRS alone compared with the combination therapy [II, A]. Adequate control of brain metastases before initiation of anti-VEGF therapy is recommended (expert opinion).

Multidisciplinary management is needed to optimise care for mRCC patients suffering from bone metastasis. The approach will need to be individualised to the extent of bone metastasis,

its location and potential consequences (see sections above on radiotherapy palliation and spinal cord compression). In widespread mRCC bone metastasis, bisphosphonate therapy with zoledronic acid has been shown to significantly reduce skeletal-related events (SREs) in patients and increase time to first SRE [51]. Denosumab is a synthetic RANK ligand inhibitor that may have a greater bone effect as it is capable of reaching all sites within bone (being a circulating antibody), compared with bisphosphonates, which have a greater affinity for sites of active bone turnover. Denosumab has been shown in a randomised trial to extend the time to first SRE by 4.3 months and was non-inferior to zoledronic acid [52]. In addition, denosumab has the convenience of subcutaneous administration with no requirement for renal monitoring or dose adjustment [I, A]. Bone-targeted therapy with either zoledronic acid or denosumab should be considered in mRCC patients with reasonable life expectancy and widespread bony metastasis weighting the potential benefits of the treatment (supposed benefit in terms of OS)

Downloaded from <http://annonc.oxfordjournals.org/> at Biblioteca IRCCS Policlinico San Matteo - Pavi on October 20, 2016

**Table 7.** Magnitude of Clinical Benefit Scale (MCBS) table for new therapies/indications in renal cell carcinoma<sup>a</sup>

Therapy	Disease setting	Trial	Control	Absolute survival gain	Hazard ratio (95% CI)	QoL/toxicity	MCBS score <sup>b</sup>
Nivolumab, a PD-1 checkpoint inhibitor	Advanced	Study of nivolumab versus everolimus in pre-treated advanced or metastatic clear cell renal cell carcinoma (CheckMate 025) [40] Phase III NCT01668784	Everolimus, in patients with renal cell carcinoma who had received previous TKI treatment. Median OS 19.6 months	OS gain: 5.4 months	OS: HR for death 0.73 (0.57–0.93)	Improved toxicity profile and QoL	5 (Form 2a)

CI, confidence interval; QoL, quality of life; PD-1, programmed death 1; TKI, tyrosine kinase inhibitor; OS, overall survival; HR, hazard ratio.

<sup>a</sup>EMA approvals in 2016 to end of August 2016.

<sup>b</sup>ESMO-MCBS version 1.0 [53].

**Table 8.** Levels of evidence and grades of recommendation (adapted from the Infectious Diseases Society of America–United States Public Health Service Grading System<sup>a</sup>)

Levels of evidence	
I	Evidence from at least one large randomised, controlled trial of good methodological quality (low potential for bias) or meta-analyses of well-conducted randomised trials without heterogeneity
II	Small randomised trials or large randomised trials with a suspicion of bias (lower methodological quality) or meta-analyses of such trials or of trials with demonstrated heterogeneity
III	Prospective cohort studies
IV	Retrospective cohort studies or case–control studies
V	Studies without control group, case reports, experts opinions
Grades of recommendation	
A	Strong evidence for efficacy with a substantial clinical benefit, strongly recommended
B	Strong or moderate evidence for efficacy but with a limited clinical benefit, generally recommended
C	Insufficient evidence for efficacy or benefit does not outweigh the risk or the disadvantages (adverse events, costs, etc.), optional
D	Moderate evidence against efficacy or for adverse outcome, generally not recommended
E	Strong evidence against efficacy or for adverse outcome, never recommended

<sup>a</sup>By permission of the Infectious Diseases Society of America [54].

with the potential harms (risk of osteonecrosis of the mandible) [II, A]. Further trials are ongoing to explore its other applications.

## personalised medicine

In this disease setting, more research is needed to identify molecular markers which could lead to advances in personalised medicine.

## response evaluation, follow-up, long-term implications and survivorship

So far, there is no evidence that early treatment of metastasis results in better outcome compared with delayed treatment. Overall, there is no evidence that any particular follow-up protocol influences the outcome in early RCC. No standard recommendation can be given for the follow-up in advanced RCC either.

The follow-up scheme for localised RCC following surgery should depend on the therapeutic possibilities upon recurrence. CT scans of thorax and abdomen are routinely carried out, with time intervals depending on risk factors. It is recommended to perform CT scans every 3–6 months in high-risk patients for the first 2 years, while a yearly CT scan is probably sufficient in low-risk patients (expert opinion).

Long-term follow-up is proposed in some institutions, due to the possibility of late relapse, but its benefit has never been demonstrated.

During systemic therapy in mRCC patients, 2- to 4-month follow-up schemes with CT scan should be advised to determine response and resistance. Although not perfect, RECIST (Response Evaluation Criteria in Solid Tumours) criteria remain the most frequently used method to assess drug efficacy. However, in the case of RECIST-defined disease progression, there is no clinical evidence that this quantity of progression is a clinically valid end point that should require treatment interruption or modification.

## methodology

These clinical practice guidelines were developed in accordance with the ESMO standard operating procedures for clinical practice guidelines development, [www.esmo.org/Guidelines/ESMO-Guidelines-Methodology](http://www.esmo.org/Guidelines/ESMO-Guidelines-Methodology). The relevant literature has been selected by the expert authors. An MCBS table with ESMO-MCBS scores is included in Table 7. ESMO-MCBS v1.0 [53] was used to calculate scores for new therapies/indications approved by the EMA since 1st January 2016. Levels of evidence and grades of recommendation have been applied using the system shown in Table 8. Statements without grading were considered justified standard clinical practice by the experts and the ESMO faculty. This manuscript has been subjected to an anonymous peer-review process.

## acknowledgements

AB took part as practicing urologist and not as vice chair of the European Association of Urology (EAU) RCC guideline panel

to synchronise the surgical recommendations with the surgical recommendations of the EAU RCC guidelines.

## conflict of interest

BE has reported honoraria for lectures and advisory boards received from Novartis, Pfizer, Bristol-Myers Squibb, Exelixis, Roche, Ipsen, and Eisai. CP acted as a consultant and/or speaker for Novartis, Pfizer, Bristol-Myers Squibb, Roche/Genentech, Exelixis, Ipsen, Eisai and Peloton. MS has reported honoraria for lectures and advisory boards from Pfizer, Roche, Novartis, Exelixis, Eisai, Bristol-Myers Squibb, Aveo and Astellas. AB took part in advisory boards for Pfizer, Novartis, Nektar, and Eisai. VG has reported honoraria from Bristol-Myers Squibb, Novartis, Pfizer, and Roche, and advisory role in Bristol-Myers Squibb, Exelixis, Ipsen, Novartis, and Pfizer. All remaining authors have declared no conflicts of interest.

## references

1. Siegel RL, Miller KD, Jemal A. Cancer statistics, 2016. *CA Cancer J Clin* 2016; 66: 7–30.
2. Chow WH, Dong LM, Devesa SS. Epidemiology and risk factors for kidney cancer. *Nat Rev Urol* 2010; 7: 245–257.
3. Volpe A, Kachura JR, Geddie WR et al. Techniques, safety and accuracy of sampling of renal tumors by fine needle aspiration and core biopsy. *J Urol* 2007; 178: 379–386.
4. Marconi L, Dabestani S, Lam TB et al. Systematic review and meta-analysis of diagnostic accuracy of percutaneous renal tumour biopsy. *Eur Urol* 2016; 69: 660–673.
5. Moch H, Cubilla AL, Humphrey PA et al. The 2016 WHO classification of tumours of the urinary system and male genital organs-part A: renal, penile, and testicular tumours. *Eur Urol* 2016; 70: 93–105.
6. Delahunt B, Cheville JC, Martignoni G et al. The International Society of Urological Pathology (ISUP) grading system for renal cell carcinoma and other prognostic parameters. *Am J Surg Pathol* 2013; 37: 1490–1504.
7. Brugarolas J. Molecular genetics of clear-cell renal cell carcinoma. *J Clin Oncol* 2014; 32: 1968–1976.
8. Gerlinger M, Rowan AJ, Horswell S et al. Intratumor heterogeneity and branched evolution revealed by multiregion sequencing. *N Engl J Med* 2012; 366: 883–892.
9. Gerlinger M, Horswell S, Larkin J et al. Genomic architecture and evolution of clear cell renal cell carcinomas defined by multiregion sequencing. *Nat Genet* 2014; 46: 225–233.
10. Hakimi AA, Ostrovskaya I, Reva B et al. Adverse outcomes in clear cell renal cell carcinoma with mutations of 3p21 epigenetic regulators BAP1 and SETD2: a report by MSKCC and the KIRC TCGA research network. *Clin Cancer Res* 2013; 19: 3259–3267.
11. Hakimi AA, Pham CG, Hsieh JJ. A clear picture of renal cell carcinoma. *Nat Genet* 2013; 45: 849–850.
12. Voss MH, Hakimi AA, Pham CG et al. Tumor genetic analyses of patients with metastatic renal cell carcinoma and extended benefit from mTOR inhibitor therapy. *Clin Cancer Res* 2014; 20: 1955–1964.
13. Cancer Genome Atlas Research Network Linehan WM, Spellman PT et al. Comprehensive molecular characterization of papillary renal-cell carcinoma. *N Engl J Med* 2016; 374: 135–145.
14. Leibovich BC, Blute ML, Cheville JC et al. Prediction of progression after radical nephrectomy for patients with clear cell renal cell carcinoma: a stratification tool for prospective clinical trials. *Cancer* 2003; 97: 1663–1671.
15. Zisman A, Pantuck AJ, Dorey F et al. Improved prognostication of renal cell carcinoma using an integrated staging system. *J Clin Oncol* 2001; 19: 1649–1657.

16. Sun M, Shariat SF, Cheng C et al. Prognostic factors and predictive models in renal cell carcinoma: a contemporary review. *Eur Urol* 2011; 60: 644–661.
17. Motzer RJ, Mazumdar M, Bacik J et al. Survival and prognostic stratification of 670 patients with advanced renal cell carcinoma. *J Clin Oncol* 1999; 17: 2530–2540.
18. Motzer RJ, Escudier B, Bukowski R et al. Prognostic factors for survival in 1059 patients treated with sunitinib for metastatic renal cell carcinoma. *Br J Cancer* 2013; 108: 2470–2477.
19. Heng DY, Xie W, Regan MM et al. Prognostic factors for overall survival in patients with metastatic renal cell carcinoma treated with vascular endothelial growth factor-targeted agents: results from a large, multicenter study. *J Clin Oncol* 2009; 27: 5794–5799.
20. Heng DY, Xie W, Regan MM et al. External validation and comparison with other models of the International Metastatic Renal-Cell Carcinoma Database Consortium prognostic model: a population-based study. *Lancet Oncol* 2013; 14: 141–148.
21. Ko JJ, Xie W, Kroeger N et al. The International Metastatic Renal Cell Carcinoma Database Consortium model as a prognostic tool in patients with metastatic renal cell carcinoma previously treated with first-line targeted therapy: a population-based study. *Lancet Oncol* 2015; 16: 293–300.
22. Jones J, Otu H, Spentzos D et al. Gene signatures of progression and metastasis in renal cell cancer. *Clin Cancer Res* 2005; 11: 5730–5739.
23. Rini B, Goddard A, Knezevic D et al. A 16-gene assay to predict recurrence after surgery in localised renal cell carcinoma: development and validation studies. *Lancet Oncol* 2015; 16: 676–685.
24. MacLennan S, Imamura M, Lapitan MC et al. Systematic review of oncological outcomes following surgical management of localised renal cancer. *Eur Urol* 2012; 61: 972–993.
25. Dabestani S, Marconi L, Hofmann F et al. Local treatments for metastases of renal cell carcinoma: a systematic review. *Lancet Oncol* 2014; 15: e549–e561.
26. Jewett MA, Mattar K, Basiuk J et al. Active surveillance of small renal masses: progression patterns of early stage kidney cancer. *Eur Urol* 2011; 60: 39–44.
27. Bekema HJ, MacLennan S, Imamura M et al. Systematic review of adrenalectomy and lymph node dissection in locally advanced renal cell carcinoma. *Eur Urol* 2013; 64: 799–810.
28. Haas NB, Manola J, Uzzo RG et al. Adjuvant sunitinib or sorafenib for high-risk, non-metastatic renal-cell carcinoma (ECOG-ACRIN E2805): a double-blind, placebo-controlled, randomised, phase 3 trial. *Lancet* 2016; 387: 2008–2016.
29. Flanigan RC, Mickisch G, Sylvester R et al. Cytoreductive nephrectomy in patients with metastatic renal cancer: a combined analysis. *J Urol* 2004; 171: 1071–1076.
30. Escudier B, Pluzanska A, Koralewski P et al. Bevacizumab plus interferon alfa-2a for treatment of metastatic renal cell carcinoma: a randomised, double-blind phase III trial. *Lancet* 2007; 370: 2103–2111.
31. Motzer RJ, Hutson TE, Tomczak P et al. Sunitinib versus interferon alfa in metastatic renal-cell carcinoma. *N Engl J Med* 2007; 356: 115–124.
32. Sternberg CN, Davis ID, Mardiak J et al. Pazopanib in locally advanced or metastatic renal cell carcinoma: results of a randomized phase III trial. *J Clin Oncol* 2010; 28: 1061–1068.
33. Motzer RJ, Hutson TE, Cella D et al. Pazopanib versus sunitinib in metastatic renal-cell carcinoma. *N Engl J Med* 2013; 369: 722–731.
34. Hudes G, Carducci M, Tomczak P et al. Temsirolimus, interferon alfa, or both for advanced renal-cell carcinoma. *N Engl J Med* 2007; 356: 2271–2281.
35. Escudier B, Eisen T, Stadler WM et al. Sorafenib in advanced clear-cell renal-cell carcinoma. *N Engl J Med* 2007; 356: 125–134.
36. Rini BI, Escudier B, Tomczak P et al. Comparative effectiveness of axitinib versus sorafenib in advanced renal cell carcinoma (AXIS): a randomised phase 3 trial. *Lancet* 2011; 378: 1931–1939.
37. Motzer RJ, Escudier B, Oudard S et al. Efficacy of everolimus in advanced renal cell carcinoma: a double-blind, randomised, placebo-controlled phase III trial. *Lancet* 2008; 372: 449–456.
38. Choueiri TK, Escudier B, Powles T et al. Cabozantinib versus everolimus in advanced renal-cell carcinoma. *N Engl J Med* 2015; 373: 1814–1823.
39. Choueiri TK, Escudier B, Powles T et al. Cabozantinib versus everolimus in advanced renal cell carcinoma (METEOR): final results from a randomised, open-label, phase 3 trial. *Lancet Oncol* 2016; 17: 917–927.
40. Motzer RJ, Escudier B, McDermott DF et al. Nivolumab versus everolimus in advanced renal-cell carcinoma. *N Engl J Med* 2015; 373: 1803–1813.
41. Motzer RJ, Hutson TE, Glen H et al. Lenvatinib, everolimus, and the combination in patients with metastatic renal cell carcinoma: a randomised, phase 2, open-label, multicentre trial. *Lancet Oncol* 2015; 16: 1473–1482.
42. Motzer RJ, Porta C, Vogelzang NJ et al. Dovitinib versus sorafenib for third-line targeted treatment of patients with metastatic renal cell carcinoma: an open-label, randomised phase 3 trial. *Lancet Oncol* 2014; 15: 286–296.
43. Motzer RJ, Barrios CH, Kim TM et al. Phase II randomized trial comparing sequential first-line everolimus and second-line sunitinib versus first-line sunitinib and second-line everolimus in patients with metastatic renal cell carcinoma. *J Clin Oncol* 2014; 32: 2765–2772.
44. Armstrong AJ, Halabi S, Eisen T et al. Everolimus versus sunitinib for patients with metastatic non-clear cell renal cell carcinoma (ASPEN): a multicentre, open-label, randomised phase 2 trial. *Lancet Oncol* 2016; 17: 378–388.
45. Tannir NM, Jonasch E, Albiges L et al. Everolimus versus sunitinib prospective evaluation in metastatic non-clear cell renal cell carcinoma (ESPN): a randomized multicenter phase 2 trial. *Eur Urol* 2016; 69: 866–874.
46. Khoo VS, Pyle L. Radiotherapy and supportive care. In Eisen T, Christmas T (eds), *Clinical Progress in Renal Cancer*, Vol 15. Oxford: Informa UK Ltd 2007; 191–201. ISBN 10-1-84184-604-X.
47. De Meerleer G, Khoo V, Escudier B et al. Radiotherapy for renal-cell carcinoma. *Lancet Oncol* 2014; 15: e170–e177.
48. Patchell RA, Tibbs PA, Regine WF et al. Direct decompressive surgical resection in the treatment of spinal cord compression caused by metastatic cancer: a randomised trial. *Lancet* 2005; 366: 643–648.
49. Andrews DW, Scott CB, Sperduto PW et al. Whole brain radiation therapy with or without stereotactic radiosurgery boost for patients with one to three brain metastases: phase III results of the RTOG 9508 randomised trial. *Lancet* 2004; 363: 1665–1672.
50. Kocher M, Soffietti R, Abacioglu U et al. Adjuvant whole-brain radiotherapy versus observation after radiosurgery or surgical resection of one to three cerebral metastases: results of the EORTC 22952-26001 study. *J Clin Oncol* 2011; 29: 134–141.
51. Henry DH, Costa L, Goldwasser F et al. Randomized, double-blind study of denosumab versus zoledronic acid in the treatment of bone metastases in patients with advanced cancer (excluding breast and prostate cancer) or multiple myeloma. *J Clin Oncol* 2011; 29: 1125–1132.
52. Rosen LS, Gordon D, Tchekmedyan NS et al. Long-term efficacy and safety of zoledronic acid in the treatment of skeletal metastases in patients with nonsmall cell lung carcinoma and other solid tumors: a randomized, Phase III, double-blind, placebo-controlled trial. *Cancer* 2004; 100: 2613–2621.
53. Cherny NI, Sullivan R, Dafni U et al. A standardised, generic, validated approach to stratify the magnitude of clinical benefit that can be anticipated from anti-cancer therapies: the European Society for Medical Oncology Magnitude of Clinical Benefit Scale (ESMO-MCBS). *Ann Oncol* 2015; 26: 1547–1573.
54. Dykewicz CA. Summary of the guidelines for preventing opportunistic infections among hematopoietic stem cell transplant recipients. *Clin Infect Dis* 2001; 33: 139–144.