

# Brain perfusion defects by SPET/CT and neurostat semi-quantitative analysis in two patients with congenital erythropoietic porphyria

Vincenzo Frusciante<sup>1</sup> MD,  
Cristina Ferrari<sup>2</sup> MD,  
Manuela Totaro<sup>1</sup> MD,  
Guido Valle<sup>1</sup> MD,  
Claudio Carmine Guida<sup>3</sup> MD,  
Filippo Aucella<sup>3</sup> MD,  
Paola Caputo<sup>2</sup> MD,  
Giuseppe Rubini<sup>2</sup> MD, PhD

1. Nuclear Medicine, IRCCS "Casa Sollievo della Sofferenza",  
San Giovanni Rotondo, Foggia,  
Italy

2. Nuclear Medicine, D.I.M.,  
University of Bari "Aldo Moro",  
Bari, Italy

3. Nephrology, IRCCS "Casa Sollievo  
della Sofferenza", San Giovanni  
Rotondo, Foggia, Italy

**Keywords:** Congenital  
erythropoietic porphyria  
-Brain perfusion defect  
-Single photon emission  
tomography  
-Magnetic resonance imaging

## Corresponding author:

Giuseppe Rubini, Professor MD,  
PhD  
Piazza G. Cesare, 11, 70124 Bari,  
Italy  
Phone number: +39 080 5592913  
Fax number: +39 080 5593250  
giuseppe.rubini@uniba.it

Received:

23 March 2018

Accepted revised:

10 April 2018

## Abstract

**Background:** Congenital erythropoietic porphyria (CEP) is a rare autosomal recessively inherited disorder with chronic and relatively stable presentation. Till now brain blood flow derangements have been described only in acute hepatic porphyrias. We describe the first findings of brain perfusion defects, studied by single photon emission tomography/computed tomography (SPET/CT), in two patients affected by CEP, by using a semi-quantification anatomic-standardized voxel-based program compared with magnetic resonance imaging (MRI) results. **Subjects and Methods:** Two Pakistanis brothers were investigated for CEP confirmed by a genetic test. The disease was severe with: skin burning, mood depression and haemolytic anemia. Considering depression, patients underwent brain SPET/CT and MRI. Single photon emission tomography/CT images were processed by neurostat semi-quantitative software. Data obtained were compared to a normal database and z-score images were generated. **Results:** In both patients we found several perfusion defects evident in transaxial slices and in z-score images obtained by neurostat processing. Magnetic resonance imaging was negative in both patients. Biochemical mechanisms inducing localized brain hypoperfusion are uncertain. However, mismatch between SPET/CT data and MRI was probably due to absence of necrosis. **Conclusion:** In our opinion, SPET/CT could have a key role in this setting of patients due to its high sensitivity and reliability in mild-to-moderate brain perfusion defects detection. Moreover, the quantitative analysis by using neurostat may allow to recognize even mild brain perfusion alterations, difficult to detect only visually.

*Hell J Nucl Med* 2018; 21(1): 43-47

Published online: 25 April 2018

## Introduction

Congenital erythropoietic porphyria (CEP), or Gunther's disease, is an autosomal recessively inherited disorder that affects heme, involving one of the eighth enzymatic steps which starts and ends in the mitochondria with intermediate steps taking place in the cytosol.

Congenital erythropoietic porphyria belongs to the non-acute porphyrias group and it is caused by deficiency of uroporphyrinogen III synthase (UROS), the fourth cytoplasmatic enzyme of the heme biosynthetic pathway, which catalyzes the conversion of the hydroxymethylbilane into uroporphyrinogen III [1].

Heme is an essential component of several hemoprotein such as hemoglobin, cytochrome enzymes and myoglobin. Hemoglobin synthesis in erythroid precursor cells accounts for about 85% of heme synthesis, while synthesis of cytochrome P450 enzymes in hepatocytes accounts for most of the other heme synthesis [2].

Forty five different CEP-causing mutations have been identified throughout the UROS gene on chromosome 10q25.2-26.3, with impact on disease severity that can ranges from fetal hydrops to adult onset with mild cutaneous photosensitivity [3].

Typically, CEP begins with red urine shortly after birth. Bullous cutaneous photosensitivity and skin fragility starts in early infancy, leading to scarring with photomutilation. Other manifestations include hypertrichosis, erythrodontia, chronic hemolytic anemia, osteoporosis, corneal ulceration and scarring [4, 5].

No neurological and/or psychiatric symptoms were described to date neither in CEP patients nor in other non-acute porphyrias. Conversely, literature reports several neurological manifestations for acute porphyrias such as motor weakness, sensory loss, psychiatric problems, seizures, and mental and behavioral abnormalities, even if pathophysi-

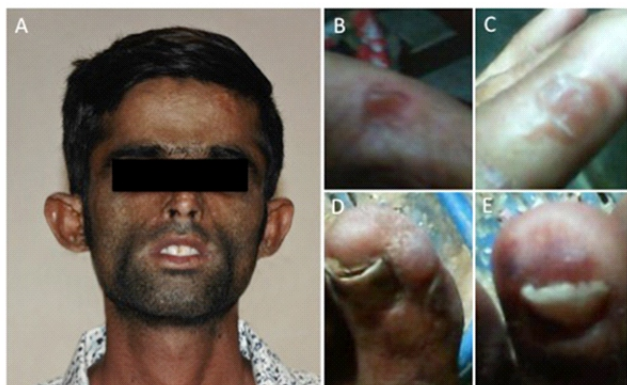ology is not yet fully understood [6].

Several authors reported the presence of cerebral ischemia in patients with acute intermittent porphyria (AIP). Totaro et al. (2013) [7] described the possible role of single photon emission tomography (SPET) in the early detection of mild brain perfusion defects in a series of 15 AIP patients, before any morphological changes were evident on MRI. Comparable SPET perfusion pattern was observed in patients with hereditary coproporphria (HCP) [8, 9].

We describe in two patients affected by CEP, to the best of our knowledge, the first findings in literature of brain SPET/CT perfusion defects by using a quantification anatomic-standardized voxel-based analysis.

### Patients' description

Two Pakistanis brothers, of 27 and 23 years of age respectively, were admitted at our hospital presenting red to yellow urine, mild yellow teeth coloration, hypertrichosis, skin friable with red bullae and blisters prone to rupture and infection, skin thickening, focal hypopigmentation and hyperpigmentation, skin burning, light sensitivity and symptoms like paresthesia, worsening fatigue and depression (Figure 1).



**Figure 1.** One of the two Pakistanis brothers with signs of CEP (patient 1). A. Evidence of yellow teeth coloration and hypertrichosis; B, C. Fingers with red bullae and blisters prone to rupture and; D, E. Toes with ulcerations and infection.

Hemolytic anemia was demonstrated and osteopenia resulted at dual-energy X-ray absorptiometry (DEXA) examination. The disease was investigated by genetic testing and confirmed by biomolecular analysis.

Considering patients' depression and taking into account that in other porphyrias, even if acute, brain perfusion abnormalities have been already demonstrated [7-10], the presence of a possible brain vascular damage was assessed by performing brain perfusion SPET/CT and MRI.

Clinical conditions that could interfere with the brain perfusion like hypertension or family history of stroke or of other cardiovascular diseases were denied. None of the two patients was tobacco smoker or drug abuser [11]. A written informed consent was obtained from both patients.

## Imaging Methods

### SPET/CT examinations

Patients received an intravenous injection of 740MBq of  $^{99m}\text{Tc}$ -hexamethylpropyleneamine oxime (HMPAO) when lying down in the supine position with eyes closed in a dimly lit, quiet room. Thirty minutes after the injection of the radiopharmaceutical, brain SPET/CT was performed using a double-head rotating gamma-camera Symbia T16 (Siemens, Erlangen Germany) equipped with high resolution low-energy collimators. Data were acquired with 128x128 matrix in step & shoot mode, 60 steps for each camera at 30 seconds per angle; data were acquired with an auto contour orbit; scatter correction was performed with two windows method. Spiral CT data were acquired with 130kV and 130 mAs. The SPET data were reconstructed with Flash 3D iterative algorithm method (Siemens) and corrected for attenuation by CT maps.

The qualitative assessment was performed analyzing transaxial, sagittal and coronal images. Any area of decreased radiopharmaceutical uptake was considered as hypoperfused and then pathologic. According with the usual practice, the evaluation of the severity of the perfusional abnormalities has been done on the basis of a personal evaluation expressed by the consensus of two nuclear physicians with at least 5 years of experience [12].

Moreover, the semi-quantification of defects' severity was performed by processing the brain perfusion reconstructed images with an anatomic-standardized voxel-based program named neurostat software installed on a windows 7 64-bit computer (Microsoft, Redmond USA) [13, 14]. An individual brain image set was aligned to the midsagittal plane. The AC-PC line (a line passing through the anterior and posterior commissure) was estimated by an iterative matching between the individual image set and a standard atlas template. Differences in size between the individual brain and the standard template were removed by linear scaling. Then a nonlinear warping along the major neuronal fiber bundles was performed to adjust the individual brain shape to the stereotactic atlas of Talairach and Tournoux [15]. At the end of the process neurostat produced a standardized set of 60 slices 128x128 matrix, voxel size of 2.25mm.

Then, neurostat compared the obtained patients' data to a normal HMPAO SPET database resulting in a set of z-score surface images normalized to cerebellar activity: right lateral, left lateral, right medial, left medial (Figure 2A). On the two lateral z-score images 9 standardized regions of interest (ROI) were overlaid: frontal, pre-central, post-central, superior parietal, inferior parietal, anterior temporal, posterior temporal, occipital, cerebellar (Figure 2 B, C); while, on the two medial z-score images 1 standardized ROI was positioned on posterior cingulate.

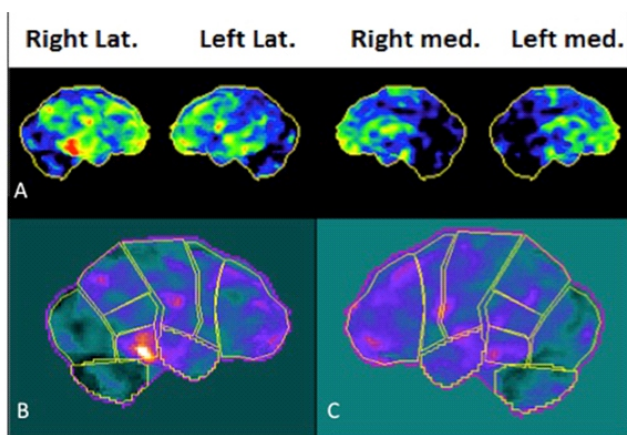
Areas with a z-score >2 were considered as hypoperfused.

Moreover, hand-made polygonal ROI of the same pixel-size were drawn on the two more severely hypoperfused regions on transaxial Talairach standardized images and the ratio of counts in this areas to counts of contralateral specular areas was calculated.

### MRI examinations

Magnetic resonance imaging examinations were performed using a Philips Ingenia 3 T scanner (Philips Healthcare, Best, The Netherlands). Each MRI study included: SE T1, on

transversal and sagittal planes, TR 450ms, TE 8.90ms, FA 90, Thickness 5mm, Gap 5; BLADE T2, on transversal and coronal planes, TR 3800ms, TE 99ms, FA 141, Thickness 5mm, Gap 5mm; 3D fluid-attenuated inversion recovery (FLAIR) (voxel 1.2x1.2x1.2mm<sup>3</sup>, TR/TE/TI=4,800/350/1,600 milliseconds, flip angle 90°, 250x250x180mm<sup>3</sup> FOV, NEX=1,163 slices), susceptibility weighted imaging (SWI) on transversal plane, (0.7x0.7x0.7mm<sup>3</sup>, TR 15, TE 0 milliseconds, flip angle 15°, 250x250x180mm<sup>3</sup> FOV, NEX=1,200 slices), Diffusion Weighted Imaging (DWI) TR 7200ms, TE 80ms, FA 90, Thickness 5mm, Gap 5mm, b values 0 and 1000; post-contrast T1-MPRAGE TR 1900, TE 3.02, FA 15, Thickness 1mm, Gap 0mm. All the sequences were acquired using the same Matrix (320x320) and 1 NEX, except for DWI in which 2 NEX were used.



**Figure 2.** Brain perfusion SPET z-score surface images produced by neurostat (A), with the 9 standardized regions of interest (ROI) overlaid on right-lateral (B) and left-lateral (C) images, in one of the two Pakistan brothers (patient 1).

## Results

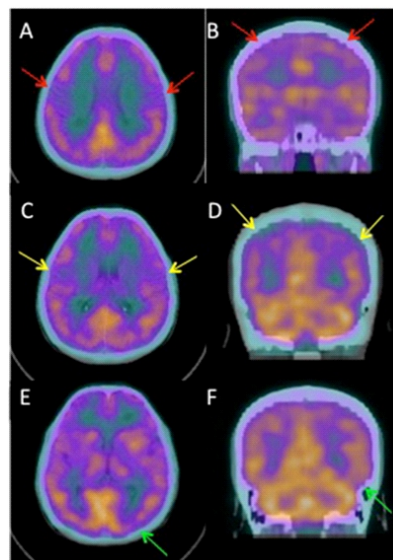
In patient 1 qualitative analysis demonstrated moderate brain perfusion defects in the parietal cortex bilaterally especially in the right upper gyrus and the bilateral temporal cortex with high hypoperfusion in the right posterior gyrus, and mild hypoperfusion in left occipital cortex, as showed in Figure 3.

The neurostat analysis demonstrated wide hypoperfused areas located in: the frontal, pre-central, post-central, superior and inferior parietal, anterior and posterior temporal standardized regions of the right hemisphere and in the superior and inferior parietal, anterior and posterior temporal and the occipital regions of the left hemisphere, by quantifying the defect severity, as reported in Table 1.

Considering the most severely hypoperfused areas, we drew two specular ROI on the right and left medium temporal gyri and two specular ROI on right and left post-central gyri; The ratios of the counts from the right to left regions for the temporal gyri and the post-central gyri were: 0.26 and 0.29, respectively.

In patient 2 qualitative analysis demonstrated mild to moderate brain perfusion defects in: frontal cortex bilaterally,

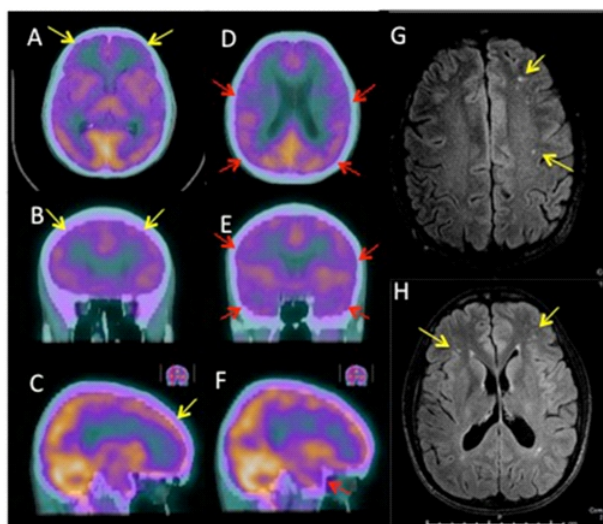
particularly in the right inferior frontal area, and the anterior and posterior temporal cortex bilaterally, as showed in Figure 4 (A-F).



**Figure 3.** Brain perfusion SPET/CT of patient 1, axial (A-E) and coronal (B-F) slices. Mild to moderate hypoperfusion is detectable in: parietal cortex bilaterally especially in the right upper gyrus (A, B), bilateral temporal cortex (C, D) and the left occipital cortex (E, F), with the qualitative analysis.

**Table 1.** Right and left lateral z-score of patients 1 and 2, respectively. Areas with a z-score > 2 were considered as hypoperfused.

Regions of interest	Patient 1		Patient 2	
	Right hemisphere z-scores	Left hemisphere z-scores	Right hemisphere z-scores	Left hemisphere z-scores
Frontal	2.86	0.97	2.40	2.04
Pre-central	2.33	1.45	1.64	1.64
Post-central	2.47	1.80	2.40	1.89
Superior parietal	2.82	2.65	2.66	1.72
Inferior parietal	2.18	2.48	1.64	1.88
Anterior temporal	3.14	2.13	2.16	1.76
Posterior temporal	5.20	2.04	4.10	2.22
Occipital	0.81	2.68	1.20	1.33
Cerebellum	0.56	0.62	0.32	0.35
Posterior gyrus cinguli	0.06	0.53	1.01	1.68



**Figure 4.** Brain perfusion SPET/CT (A-F) and related MRI imaging findings (G-H) of patient 2, axial (A, D, G, H), coronal (B, E) and sagittal (C, F) slices. Moderate with the qualitative analysis hypoperfusion is detectable in the: frontal cortex bilaterally especially in the inferior right frontal area (A-C) and the anterior and posterior temporal cortex bilaterally (D-F). Some hyperintense lesions are located in the periventricular white matter and the subcortical frontal white matter on MRI-FLAIR sequences (G-H).

The neurostat analysis demonstrated similar but wider perfusion defects located in: the frontal, post-central, superior parietal, anterior and posterior temporal regions of the right hemisphere and in the frontal and posterior temporal regions of the left hemisphere, by quantifying the defect severity, as reported in Table 1.

Then, considering the more severely hypoperfused regions, we drew two specular ROI on the right and left temporal gyri and another two specular ROI on the right and left post-central gyri; the ratios of right to left regions 0.31 and 0.30 for the temporal gyri and the post-central gyri respectively.

The MRI studies did not show any significant pathological brain findings, related to SPET/CT abnormalities for both patients; only some micro-focal FLAIR and T2-w hyperintensities were present in patient 2, related to chronic microvascular injury (Figure 4G-H).

## Discussion

Congenital erythropoietic porphyria is extremely rare, with a prevalence in Europe of 1 in 1,000,000 or less [16, 17]. It results from the markedly deficient, but not absent, activity of URO-synthase, leading to overproduction and accumulation of porphyrins, heme precursors. The major clinical manifestations of CEP are either erythropoietic, with hemolytic anemia, or cutaneous, resulting from phototoxicity, with a chronic, relatively stable, presentation. Excess porphyrins are also deposited in teeth and bones.

Differently from other acute porphyrias, in which the excess of porphyrins can cause neuro-toxicity with neuro-

pathic visceral (abdominal) pains and mental status change effects [2], these complications, to the best of our knowledge, have never before been described in CEP. The main mechanism implicated seems to be the hepatic production of a neurotoxic substance, presumably ALA (a  $\gamma$ -aminobutyric acid analog) and/or PBG, that may interact with  $\gamma$ -aminobutyric acid or glutamate receptors, resulting in re-uptake reduction and accumulation of catecholamines, with hypertension and tachycardia commonly observed during the acute porphyria attack [18].

Nuclear medicine imaging methods have always been distinguished, as they are able to highlight functional alterations before the evidence of morphological changes [19]. In particular, the role of brain perfusion SPET/CT with semi-quantitative analysis has already been tested in several other brain diseases such as encephalitis dementia and/or mild cognitive impairment [20, 21].

The young age of our patients, the absence of other vascular risk factors (diabetes, hypertension, dyslipidemia, high fibrinogenemia, pro-coagulative disorders) and of other endangerment conditions, like tobacco smoke and drug addiction, leave little doubt that the observed hypoperfusion phenomena at SPET/CT scan are depending from CEP.

The observation as above, in reference to acute porphyrias, is consistent with the presence of regional hypoperfusion also in subjects with CEP. Likewise it is difficult to make a guess on the biochemical/functional mechanisms inducing localized brain hypoperfusion. The molecules thought to be able to induce vascular derangements in porphyrias are ALA and PBG that reduce the re-uptake of catecholamines [18]. However, in our two cases these molecules were within the normal range and therefore their causative role appears therefore unlikely. On the contrary, serum urobilinogen and coprobinogen were very elevated but in the extremely limited medical literature on this issue there is no evidence that these molecules might induce arterial spasm or that might trigger derangements of blood supply.

However, since heme is required for a variety of hemoproteins, including hemoglobin, myoglobin, respiratory cytochromes and the cytochrome P450 enzymes we can speculate that other different mechanisms can be implicated in brain perfusion defects, in "non acute" porphyrias line CEP. First of all, the severe hemolytic anemia which is characteristic of CEP could be the basis of chronic hypoxia that, as a mild but constant factor affecting microcirculation, could explain the hypoperfusion defects detected on brain SPET/CT. In fact, SPET/CT is able to detect even mild functional alterations in contrary to morphological imaging methods like MRI, for which brain hypoxia was not sufficient to determine neither necrosis nor cytotoxic oedema. A mismatch between the SPET (positive for ischemia) and MRI (normal) patterns has been observed in our CEP patients, similar to what is observed in other porphyrias like AIP and HCP [7, 8, 10].

It could also be hypothesized, as has already been speculated, that porphyric patients may have a disorder of heme enzymes, like nitric oxide synthase and prostacyclin synthase implicated in vascular tone regulation [10, 22]. A dys-

function of this latter heme-enzyme, that catalyzes the synthesis of PGI<sub>2</sub> from prostaglandin H<sub>2</sub>, may induce hypertension, and cerebral and myocardial infarction [23]. Also, the heme-cytochrome CYP4F2 haplotype has been reported to be associated to cerebral infarction [24]. Other causes however cannot be excluded and the genesis of vascular dysfunction in CEP remains to be ascertained.

Probably, all these conditions together, incurred by a chronic stimulus, contribute to the onset of cerebral vascular damage even at early age, thus explaining the neurological symptoms and brain damage, which probably could increase and get worse with age.

*In conclusion*, to the best of our knowledge, this is the first brain SPET/CT perfusion study in congenital erythropoietic porphyria and therefore the first SPET/CT study demonstrating a brain vascular damage in these patients. In our opinion, SPET/CT could have a key role in this setting of patients due to its high sensitivity and reliability in the detection of mild-to-moderate brain perfusion defects and to follow the disease course. Moreover, the semi-quantitative analysis by using neurostat may allow to recognize even mild brain perfusion changes, difficult to detect by only visual assessment.

*The authors declare that they have no conflicts of interest.*

## Bibliography

- Das D, Murad A, Saad A. Erythropoietic Porphyria-Role of Curative Hematopoietic Stem Cell Transplantation. *J Hematol Transfus* 2013; 1(1): 1005.
- Balwani M, Desnick RJ. The porphyrias: advances in diagnosis and treatment. *Blood* 2012; 120(23):4496-504.
- Warner CA, Yoo HW, Roberts AG, Desnick RJ. Congenital erythropoietic porphyria: identification and expression of exonic mutations in the uroporphyrinogen III synthase gene. *J Clin Invest* 1992; 89:693-700.
- Poh-Fitzpatrick MB. The erythropoietic porphyrias. *Dermatol Clin* 1986; 4:291-6.
- Bishop DF, Johansson A, Phelps R et al. Uroporphyrinogen III synthase knock-in mice have the human congenital erythropoietic porphyria phenotype, including the characteristic light-induced cutaneous lesions. *Am J Hum Genet* 2006; 78:645-58.
- Solinas C, Vajda F. Neurological complications of porphyria. *J Clin Neurosci* 2008; 15:263-8.
- Totaro M, Guida CC, Frusciantè V et al. Perfusional brain <sup>99m</sup>Tc-Bicisate (Neurolite) Single Photon Emission Computed Tomography (SPECT) in Acute Intermittent Porphyria (AIP). *Clin Transl Imaging Rev Nucl Med Mol Imaging* 2013; 1 (Suppl 1), S1: S88.
- Guida CC, Totaro M, Aucella F et al. Brain Perfusion in Acute Intermittent Porphyria (AIP) and in Hereditary Coproporphyrin (HCP): <sup>99m</sup>Tc-Bicisate (Neurolite) Single Photon Emission Computed Tomography (SPECT) studies. *Clin Chem Lab Med* 2013; 51(5): eA7.
- Mullin S, Platts A, Randhawa K, Watts P. Cerebral vasospasm and anterior circulation stroke secondary to an exacerbation of hereditary coproporphyrin. *Pract Neurol* 2012; 12:384-7.
- Valle G, Guida CC, Nasuto M et al. Cerebral Hypoperfusion in Hereditary Coproporphyrin (HCP): a Single Photon Emission Computed Tomography (SPECT) study. *Endocr Metab Immune Disord Drug Targets* 2016; 16(1): 39-46.
- Gigante AF, Defazio G, Niccoli Asabella A et al. Smoking in Patients with Parkinson's Disease: preliminary striatal DaT-SPECT findings. *Acta Neurol Scand* 2016; 134(4):265-70.
- Rana KM, Narwal V, Chauhan L et al. Structural and perfusion abnormalities of brain on MRI and technetium-99m-ECD SPECT in children with cerebral palsy: a comparative study. *J Child Neurol* 2015; 31:3-4.
- Minoshima S, Koeppe RA, Frey KA et al. Anatomic Standardization: linear scaling and nonlinear warping of functional brain images. *J Nucl Med* 1995; 35: 1528-37.
- Nishimya M, Matsuda H, Imabayashi E et al. Comparison of SPM and NEUROSTAT in voxelwise statistical analysis of brain SPECT and MRI at the early stage of Alzheimer's disease. *Ann Nucl Med* 2008; 22: 921-7.
- Talairach J, Tournoux P. Co-planar stereotaxic atlas of the human brain. New York: Thieme; 1988.
- Deybach JC, Badminton M, Puy H et al. European porphyria initiative (EPI): a platform to develop a common approach to the management of porphyrias and to promote research in the field. *Physiol Res* 2006; 55 (Suppl 2): S67-73.
- Elder GH, Harper P, Badminton M et al. The incidence of inherited porphyrias in Europe. *J Inher Metab Dis* 2013; 36:849-57.
- Beal MF, Atuk NO, Westfall TC, Turner SM. Catecholamine uptake, accumulation, and release in acute porphyria. *J Clin Invest* 1979; 60: 1141-8.
- Altini C, Niccoli Asabella A, Ferrari C et al. <sup>18</sup>F-FDG PET/CT contribution to diagnosis and treatment response of rhino-orbital-cerebral mucormycosis. *Hell J Nucl Med* 2015; 18(1):68-70.
- Barai S, Sanjay G, Shankar PD, Manish O. Sequential brain perfusion abnormalities in various stages of Japanese encephalitis. *Hell J Nucl Med* 2006; 9(3): 163-6.
- Tranfaglia C, Palumbo B, Siepi D et al. Semi-quantitative analysis of perfusion of Brodmann areas in the differential diagnosis of cognitive impairment in Alzheimer's disease, fronto-temporal dementia and mild cognitive impairment. *Hell J Nucl Med* 2009; 12(2): 110-4.
- Kupferschmidt H, Bont A, Schnorf H et al. Transient cortical blindness and bioccipital brain lesions in two patients with acute intermittent porphyria. *Ann Int Med* 1995; 123: 598-600.
- Nakayama T. Genetic polymorphisms of prostacycline synthase gene and cardiovascular disease. *Int Angiol* 2010; 29: 33-42.
- Fu Z, Nakayama T, Sato N et al. Haplotype of the CYP4F2 gene is associated with cerebral infarction in Japanese men. *Am J Hypertens* 2008; 21: 1216-23.