




Since January 2020 Elsevier has created a COVID-19 resource centre with free information in English and Mandarin on the novel coronavirus COVID-19. The COVID-19 resource centre is hosted on Elsevier Connect, the company's public news and information website.

Elsevier hereby grants permission to make all its COVID-19-related research that is available on the COVID-19 resource centre - including this research content - immediately available in PubMed Central and other publicly funded repositories, such as the WHO COVID database with rights for unrestricted research re-use and analyses in any form or by any means with acknowledgement of the original source. These permissions are granted for free by Elsevier for as long as the COVID-19 resource centre remains active.



Review Article

Hepatic consequences of COVID-19 infection. Lapping or biting?

Piero Portincasa^{a,*}, Marcin Krawczyk^{b,c}, Antonia Machill^b, Frank Lammert^b, Agostino Di Ciaula^a^a *Clinica Medica “A. Murri”, Department of Biomedical Sciences and Human Oncology, University of Bari “Aldo Moro”, Bari 70124, Italy*^b *Department of Medicine II Saarland University Medical Center, Saarland University, Homburg, Germany*^c *Laboratory of Metabolic Liver Diseases, Department of General, Transplant and Liver Surgery, Laboratory of Metabolic Liver Diseases, Centre for Preclinical Research, Medical University of Warsaw, Warsaw, Poland*

ARTICLE INFO

Keywords:

Ischemia-reperfusion damage
Liver damage
Nonalcoholic fatty liver disease
SARS-CoV-2
COVID-19
Toll-like receptors

ABSTRACT

The outbreak of coronavirus disease 2019 (COVID-19) starting last December in China placed emphasis on liver involvement during infection. This review discusses the underlying mechanisms linking COVID-19 to liver dysfunction, according to recent available information, while waiting further studies. The manifestations of liver damage are usually mild (moderately elevated serum aspartate aminotransferase activities), and generally asymptomatic. Few patients can still develop severe liver problems, and therapeutic options can be limited. Liver dysfunction may affect about one-third of the patients, with prevalence greater in men than women, and in elderly. Mechanisms of damage are complex and include direct cholangiocyte damage and other coexisting conditions such as the use of antiviral drugs, systemic inflammatory response, respiratory distress syndrome-induced hypoxia, sepsis, and multiple organ dysfunction. During new COVID-19 infections, liver injury may be observed. If liver involvement appears during COVID-19 infection, however, attention is required. This is particularly true if patients are older or have a pre-existing history of liver diseases. During COVID-19 infection, the onset of liver damage impairs the prognosis, and hospital stay is longer.

1. Introduction

A novel coronavirus was reported to World Health Organization on Dec 30, 2019, as the cause of a cluster of pneumonia cases in China, city of Wuhan, Hubei Province. The first name of 2019-nCoV(human) was adopted on Jan 7, 2020, lately changed to severe acute respiratory syndrome coronavirus 2 (SARS-CoV-2). COVID-19 infection became an outbreak throughout China on Feb 11, 2020 and subsequently was identified as a global pandemic on March 11, 2020, spreading to more than 120 countries, as a major threat to public health [1–3]. The COVID-19 pandemic suddenly represented an enormous burden of care [4], and raised issues related to medical ethics [5], since specific therapies and/or vaccines are missing, to date. COVID-19 may manifest in different ways. Many subjects may remain asymptomatic [6], but the exact number is still unknown. Specific settings might facilitate the spread of infection e.g., in skilled nursing facility where more than half of residents with positive test results were asymptomatic at the time of testing and most likely contributed to transmission [7,8]. The proposed 3-stage classification system of potential increasing severity for COVID-19 infection encompasses stage I (early infection), stage II (pulmonary

phase), and stage III (hyperinflammation phase) [9]. Although the most frequent and critical clinical presentation is secondary to the involvement of the lung (fever, cough), the infection by SARS-CoV-2 virus may lead to a systemic and multi-organ disease [10], also involving the gastrointestinal tract (nausea/vomiting, or diarrhea) [11,12]. The liver appears to be the second organ involved, after the lung [13–15].

The present paper explores the available evidences on liver involvement in patients with COVID-19 infection, to provide a comprehensive understanding of the phenomenon, and to anticipate effective follow-up.

2. Symptoms

During COVID-19 infection, patients can be asymptomatic or present clinical symptoms ranging from fever, dry cough, headache to dyspnea and fatigue, to acute respiratory distress syndrome (ARDS), shock, and cardiac failure [9,16]. A nasopharyngeal swab is the collection method used to obtain a specimen for testing. Because the likelihood of the SARS-CoV-2 being present in the nasopharynx increases over time, repeated testing is often used [17]. Multi-organ

* Corresponding author: Piero Portincasa, MD, PhD, dr H. Causa, Chief, Clinica Medica “A. Murri”, Dept. of Biomedical Sciences & Human Oncology, University “Aldo Moro” Medical School, Policlinico Hospital, Piazza G. Cesare 11 - 70124 Bari – Italy. Tel. +39-080-5478892/234

E-mail addresses: piero.portincasa@uniba.it (P. Portincasa), Marcin.Krawczyk@uks.eu (M. Krawczyk), antoniamachill@hotmail.com (A. Machill), Frank.Lammert@uks.eu (F. Lammert), agostinodiciaula@tiscali.it (A. Di Ciaula).

<https://doi.org/10.1016/j.ejim.2020.05.035>

Received 26 April 2020; Received in revised form 14 May 2020; Accepted 23 May 2020

Available online 01 June 2020

0953-6205/ © 2020 European Federation of Internal Medicine. Published by Elsevier B.V. All rights reserved.

involvement secondary to COVID-19 infection occurs in a subgroup of patients [10]. COVID-19 infection can be associated with myocardial injury [18–20], heart failure [18], vascular inflammation, myocarditis, cardiac arrhythmias [19], and hypoxic encephalopathy [21]. The progression and prognosis of COVID-19 infection is worse in the presence of diabetes mellitus [22,23]. The case-fatality rate increases with age (from 8% to 15% in the age range 70–79 years, and ≥ 80 years, respectively) and with associated diseases, i.e., 11%, 7%, 6%, 6%, and 6% in patients with cardiovascular disease, diabetes mellitus, chronic respiratory disease, hypertension, and cancer, respectively [24].

During COVID-19 infection, gastrointestinal manifestations may appear, as reported from China [11,12] and among U.S. patient population [25]. The appearance of gastrointestinal symptoms could even represent the chief complaints [10,26]. The overall prevalence of GI symptoms was 18% (diarrhea 13%, nausea, vomiting 10%, and abdominal pain 8%) in Hong Kong [27], and 11.4% in another study in Zhejiang province [26]. Gastrointestinal involvement could be the consequence of COVID-19- Angiotensin-Converting Enzyme 2 (ACE2) receptors at the enterocyte level (i.e. glandular cells of gastric, duodenal and distal enterocytes), resulting in malabsorption, unbalanced intestinal secretion and activated enteric nervous system, therefore diarrhoea [28,29]. In human small intestinal organoids, SARS-CoV-2 rapidly infects the enterocytes and strongly induces a generic viral response program, pointing to a marked viral replication in the intestinal epithelium [30].

Notably, continuous viral RNA shedding occurs into feces up to 11 days negativity of respiratory samples [31]. It is difficult to establish if the virus is viable using nucleic acid detection [31,32]. Further research is required by using fresh stool samples at later time points in patients with extended duration of faecal sample positivity to the possibility of fecal-oral route transmission [31]. A study reported that the virus can be detected but not cultivated from stool (despite high RNA concentration), consistent with the lack of transmission [33]. In a case-control study from USA (enrolling 278 COVID-19 positive patients and 238 COVID-19 negative patients), the presence of gastrointestinal symptoms was predictive of COVID-19 positivity, and symptoms were associated with slower and less severe disease course [34].

3. General mechanisms of damage

Most important pathogenic mechanisms act at local and systemic levels, and play a critical role in the evolution of the disease. Steps include: (i) Inoculation and multiplication in the human body, when the virus binds to ACE2 receptors [35–37] to enter the target cell [38]. Receptors are well expressed in epithelia of the lung, gastrointestinal tract, and vascular endothelium, also in the liver [39]. This early period of COVID-19 infection can evolve to the second stage of viral pneumonia.; (ii) Extra-pulmonary systemic hyperinflammation syndrome occurs in the minority of infected patients, and is characterized by the so-called “cytokine storm”. At this moment, several cytokine levels increase, namely interleukin (IL)-2, IL-6, IL-7, IL-10, and tumor necrosis factor (TNF) α . Additional inflammatory biomarkers include granulocyte-colony stimulating factor, interferon (IFN)- γ inducible protein 10, monocyte chemoattractant protein 1, macrophage inflammatory protein 1- α , lymphopenia (in CD4+ and CD8+ T cells), decreased IFN γ expression in CD4+ T cells [40–42], and monocyte chemoattractant protein-1 (MCP-1) [42]. Increased serum levels of D-dimer, troponin and N-terminal pro B-type natriuretic peptide (NT-proBNP) can also occur, together with altered coagulation function [43–45]. An extensive meta-analysis included 21 studies describing 3,377 patients, and 33 laboratory parameters, with respect to severe and non-severe COVID-19 infection and (in another 3 studies totaling 393 patients) survivors and non-survivors of the disease. Patients with severe and fatal disease had significantly increased white blood cell count, and decreased lymphocyte and platelet counts compared to non-severe disease and survivors. Biomarkers of inflammation, muscle and cardiac injury, as well as liver

and kidney function and coagulation measures also increased in patients with both severe and fatal COVID-19. Severe disease was characterized by elevated levels of interleukins 6 (IL-6) and 10 (IL-10) and serum ferritin [46].

4. Liver involvement

ACE2 receptors in the liver are expressed mainly in cholangiocytes (60% of cells), minimally expressed in hepatocytes (3% of cells), and absent in Kupffer cells [36,39,47]. The presence of these receptors, together with the local effects of systemic inflammation and possible iatrogenic toxicity seem to be the main mechanisms involved in the onset of liver damage in COVID-19 patients.

Involvement of the liver with elevated serum alanine aminotransferase (AST), aspartate aminotransferase (ALT), and lactate dehydrogenase (LDH) activities has been firstly reported this year in 43% of the 99 COVID-19 cases from Wuhan [48]. This aspect deserves further attention.

Although the level of serum transaminases could be already elevated before the onset of COVID-19, results from clinical reports and autopsy studies [26,49,50] suggest that liver dysfunction can be an expression of a worse disease evolution, and that an isolated elevation of transaminases alone is likely to be the indirect expression of a systemic inflammation.

Previous data from COVID-19 outbreak in China found that 2–11% of patients had liver comorbidities, 14–53% of patients presented with abnormal serum aminotransferases levels during the disease, and that the rates of liver dysfunction were more present in subjects with the most severe clinical presentation [26,49]. In another large series of 417 Chinese COVID-19 patients, abnormal liver tests (AST, ALT, total bilirubin, GGT) were present in 76.3% of patients and 21.5% of subjects showed liver injury during hospitalization, in particular during the first two weeks after admittance. In addition, patients with abnormal liver tests had higher risks of progressing to severe disease. One point was therefore that clinicians should carefully monitor the detrimental effects on liver injury mainly related to certain medications during hospital admission [51]. Acute liver injury had a prevalence of 15.4% in 187 patients with confirmed COVID-19 in Wuhan [52]. Whereas gastrointestinal symptoms may occur without clinically evident respiratory involvement [53], abnormal liver function tests during COVID-19 have not been linked with any specific symptoms.

4.1. Liver test abnormalities

Mild liver involvement occurs in more than one-third of infected patients who can show elevated serum ALT or AST, elevated LDH, creatinine kinase or myoglobin, abnormal prothrombin time and high gamma-glutamyl transferase (GGT) during COVID-19 progression, as observed at intensive care units (ICU) or normal care units (NCU) during hospitalization [10,49,54–59].

A large retrospective, multicenter study in Chinese adults with COVID-19 pneumonia described a dynamic pattern of liver injury indicators, with a first elevation of AST, followed by ALT in severe patients, and mild fluctuations of total bilirubin levels irrespective of disease severity. In this series of patients, AST levels were strongly associated with the mortality risk [60].

Hyperbilirubinemia was observed in 11% to 18% of cases [48,49]. A clear and severe cholestatic pattern is absent during COVID-19 infection. In a comprehensive review examining 14 eligible studies [61], elevated AST and ALT activities were reported in Guangzhou Medical University, China, in 6% to 22% and 21% to 28% of patients, respectively. In studies from Wuhan, AST levels were increased in 24% to 37% of patients, a proportion higher than in other Chinese regions (Zhejiang), reporting a proportion of 16%. A gender difference might exist in this respect [62], since the prevalence of AST increase is higher in men than women, as documented by six case series (i.e., average 66%

vs. 35%, respectively). Case reports and case series also suggest that the probability of developing liver dysfunction increases with older age [61]. Notably, the elevation of aminotransferases was mild, with no report about intrahepatic cholestasis or liver failure. It is a possible that abnormal liver function tests during COVID-19 infection are transient. Abnormalities often coexist with increased enzyme activities from muscle and heart. Changes may not affect liver-related morbidity and mortality.

4.2. Mechanisms of liver damage directly or indirectly related to COVID-19 infection in the normal liver

The main target of COVID-19 is the lung via ACE2 receptors [63,64]. However, SARS-CoV2 RNA has been detected in feces [27,31,32], with a longer presence in faecal samples, as compared with respiratory samples [31]. The presence of the virus in gut lumen could lead to translocation into the liver via portal flow, with direct negative effects on hepatic cells (unconfirmed hypothesis). The liver damage occurring during COVID-19 infection is likely of multifactorial origin.

In particular, during COVID-19 progression, the liver could be involved either as a direct target of the SARS-CoV-2 (e.g. hepatocyte apoptosis [65] or caspase-dependent pathways [66]) and secondary to the complex pathways of systemic alterations promoted by the viral infection, mainly including inflammation and cytokine release (including IL-1, IL-6, IL-10 [67]), immune response, altered coagulation, hepatic ischemia and hypoxia, and sepsis-related abnormalities.

Additional elements possibly concurring to liver damage are drug-related injury and the progression of underlying liver diseases.

It is still under debate if these alterations can really be an expression of a clinically relevant liver injury requiring particular attention in the management of the disease [13, 68]. In one study, patients developing abnormal liver tests had higher risks of progressing to severe disease [51], and the finding is associated with longer hospital stay [62]. In addition, the more severe form of COVID-19 infection is a predisposing condition to a more evident liver damage [10, 49, 69], and therefore also patients admitted to ICU [59].

Table 1 depicts the most distinctive post-mortem histopathological changes of the liver from patients with COVID-19. Remarkably, liver failure and bile duct injuries were not reported in these studies.

Liver damage is more likely to occur in patients with more severe disease [9], in whom concomitant alterations of liver function tests are more likely [10, 42]. Aggravating factors include ischemic/hypoxic liver injury [70], and immunologic, inflammatory and toxic mechanisms promoted by systemic sepsis [71]. Viral inclusions seem to be absent in the liver [57], but this possibility deserves further investigations, because of potential viral RNA translocation from intestine through portal blood.

Table 1
Major post-mortem histopathological changes of the liver from patients with COVID-19

| Reference | Findings |
|-------------------------|--|
| Xu et al., 2020 [57] | Microvesicular steatosis Mild lobular and portal activity |
| Liu et al., 2020 [50] | Hepatomegaly Hepatocyte degeneration Lobular focal necrosis Neutrophil infiltration Infiltration of lymphocytes and monocytes (portal area) Congestion of hepatic sinuses with microthrombosis. |
| Tian et al., 2020 [126] | Mild sinusoidal dilatation Mild lobular lymphocytic infiltration Patchy hepatic necrosis in the periportal and centrilobular areas |
| Ji et al., 2020 [99] | Microvesicular steatosis Overactivation of T cells |

Another possibility is the direct damage from COVID-19. Cholangiocytes express ACE2 receptors (more than 20-fold than in hepatocytes). Although cell damage can also occur at the level of bile ducts [72, 73], specific abnormalities of bile duct chemistry [49], major histological abnormalities [57], and liver failure [14] are rare. A major involvement of cholangiocytes during COVID-19 would parallel increased levels of serum alkaline phosphatase, but this is an uncommon finding. Likely, COVID-19 promotes liver damage mainly through ACE2 receptors expressed in endothelial cells [39]. These cells actively participate to liver ischemia-reperfusion damage and promote oxidant stress via reactive oxygen species (ROS) and nitric oxide (NO) derivatives [74].

COVID-19 infection can progress to the inflammatory cytokine storm [75], which involve both the innate (Toll-like receptors, TLRs) and the cellular adaptive immunity (killer T lymphocytes) [76, 77]. The deleterious sequence, resembling pictures evolving during sepsis, includes COVID-19 infection, activation of intrahepatic CD4+ and CD8+ T-cells, Kupffer cells, activation of B cells and release of antiviral antibodies [13, 78]. These pathways evolve towards apoptosis and necrosis of infected cells with release of damage-associated molecular patterns and inflammatory signals which can interact with TLRs [76, 77]. Further complications include bacterial infections, more pro-inflammatory signaling pathways, macrophage activation and more inflammatory responses. The involvement of the innate immune system, becoming defective during COVID-19 infection, is further supported by depressed platelet counts, activation of coagulative and fibrinolytic pathways, increased neutrophil counts and neutrophil to lymphocyte ratios, as well as hyperferritinemia [10]. Elderly patients go worse, in this respect [79]. This sudden and immense immune hyperactivation may result in multiple organ failure lungs but also to the liver, heart, and kidneys [75]. Serum levels of the monocyte chemoattractant protein-1 (MCP-1), in particular, are increased in COVID-19 patients [42]. This chemokine has a critical role in the pathogenesis of liver disease [80], and is able to exacerbate steatohepatitis [12].

A further mechanism of liver damage includes the pneumonia-associated hypoxic damage in the liver, as the consequence of respiratory distress syndrome, hyperinflammatory response, and multiple organ failure [61]. The prevalence of this condition should be lower than above-mentioned conditions [13]. Hepatocyte cell death will result from the ongoing status of hepatic ischemia and hypoxia-reperfusion dysfunction, leading to hyperaccumulation of lipids, production of reactive oxygen species and increased oxidant stress and further pro-inflammatory molecules [81]. In this context, mitochondrial damage may also play a role [82, 83].

4.3. The impact of a pre-existing liver disease

In general, an underlying liver disease represents a potential risk factor for COVID-19 evolution to severe infection [84]. Conditions might include the ongoing liver damage due to chronic hepatitis B, combined HBV/HCV hepatitis (with risk of enhanced replication of hepatitis virus [85]), nonalcoholic fatty liver disease (NAFLD) (because of associated comorbidities of diabetes and cardiovascular disorder, and increased susceptibility to drugs) [86] liver cirrhosis [87], patients undergone liver transplant and who are on immunosuppressants [71], patients with hepatocellular carcinoma and immune-deficient status [31]. Preventive measures are highly recommended in these patients [88]. The aspect related to an underlying liver disease, represents a major burden in China, where liver diseases, primarily viral hepatitis (predominantly hepatitis B virus, HBV), NAFLD and alcoholic liver disease affect approximately 300 million people [87]. Similar aspects, e.g. liver disorder connected with underlying metabolic abnormalities, are frequent in Western industrialized countries. In particular, the issue of COVID-19 infection and underlying metabolic abnormalities should also consider liver steatosis. NAFLD refers to the development of abnormal hepatic steatosis in the absence of other causes for secondary

hepatic fat accumulation. NAFLD is the most common liver disorder in Western industrialized countries, (prevalence ranging from 10 to 46% in the United States [89–91]) and a median of 20% worldwide with a documented rising trend with time [92]. This trend in North America and Europe is the consequence of the rising prevalence of major risk factors for NAFLD, including obesity, sedentary lifestyles, type 2 diabetes mellitus, dyslipidaemia, and metabolic syndrome [92–95]. However, lean non-alcoholic steatohepatitis (NASH) can develop as well [94] and is frequent in Asia [96]. Overall, factors contributing to NAFLD include the environment, the gut microbiome, disrupted gluco-lipid metabolic pathways, metabolic inflammation primarily mediated by innate immune signalling, comorbidities and genetic risk factors [97, 98].

In the study by Ji et al., 202 patients with COVID-19 infection and NAFLD (assessed by steatosis index and/or abdominal ultrasonography), developed liver injury in 50% and 75% of cases on admission and during hospitalization, respectively [99]. NAFLD [86], higher BMI [86], and age [79], as well as underlying liver disease [86] were associated with COVID-19 progression. Thus, patients suffering from NAFLD could be vulnerable to COVID-19 infection and viral-related complications. These patients might display an increased risk of NAFLD progression to steatohepatitis in the long-term [100]. Notably, ACE2 expression is significantly increased in liver injury in both humans and rat, likely in response to increasing hepatocellular hypoxia [101].

Furthermore, as described above, a previous NAFLD could be exacerbated by chemokines released during SARS-CoV-2 infection [12, 80].

In addition, the presence of NAFLD can put patients at increased risk of a severe course of COVID-19, due to the frequent coexistence of metabolic comorbidities such as diabetes, hypertension, and obesity [86]. Non-cirrhotic patients with NAFLD/NASH can be considered as cardio-metabolic subjects and, therefore, at very high risk of COVID-19 complications. From a pathogenic point of view, the presence of inflammatory pathways (in particular those involving cytokines) common to NAFLD [102–104] and COVID-19 [40–42, 46] might increase the risk of liver inflammation in subjects with NAFLD and further aggravate the outcome if these patients are infected with the SARS-CoV-2. In a Chinese retrospective study, the presence of NAFLD was linked with a high risk of COVID-19 progression, and with longer viral shedding time, as compared to patients without NAFLD [99].

According to the EASL-ESCMID position paper [86], based on the experience on Chinese patients [49], chronic viral hepatitis would not increase the risk of a severe course of COVID-19. However, in patients with advanced liver disease and after liver transplantation there is increased risk of infection and/or a severe course of COVID-19 [86, 105].

Patients with autoimmune hepatitis or on immunosuppressive medications can be at increased risk for severe COVID-19 outcomes [105, 106]. According to the recent AASLD guidelines, this group of patients should be prioritized for testing until further will become available. Furthermore, in COVID-19 patients with autoimmune hepatitis or previous liver transplantation, a more aggressive approach is required, i.e., a suspect flare or acute cellular rejection should not be based on liver biochemistry alone but should undergo liver biopsy confirmation [105]. In addition, a flare of autoimmune liver disease due to unnecessary drug reduction or withdrawal would lead to increased doses of steroids. This possibility, in turn, will expose patients to increased risks of SARS-CoV-2 infection [106]. The immunosuppressive therapy in COVID-19 patients with liver disease should be minimized but not stopped [105].

During COVID-19 pandemic and afterwards (“Phase 2”), measures of social distancing aimed at the primary prevention of the infection, see the key involvement of the national health system. Such measures can influence the regular path of care of patients with chronic liver diseases, particularly those with decompensated cirrhosis, hepatocellular carcinoma and waiting for liver transplantation [105]. This

approach could lead to increased decompensation, morbidity, onset of complications or transplant waiting list dropout. In this context, the preventive care provided to these patients must be intensified and tools imply, whenever possible, telehealth programs and reorganization of care delivery [107].

4.4. The liver damage caused by agents used for treatment of the infection

During COVID19 infection, liver damage could originate following the use of drugs, as suggested by the presence of microvesicular steatosis, and liver inflammation [57]. Agents include potentially hepatotoxic antiviral drugs employed off-label to treat the infection, as well as the use of antibiotics (quinolones, macrolides) in preventing/treating bacterial superinfections, antipyretics, or steroids [62, 108].

Liver toxicity might involve the drug-cytochrome P-450 interaction, as reported for azithromycin [109, 110], lopinavir/ritonavir [62, 111], hydroxy-chloquine [112, 113], and acetaminophen [114, 115].

A study was conducted from clinical records and laboratory results from 417 laboratory-confirmed COVID-19 patients admitted to the hospital in Shenzhen, China, treatment with lopinavir/ritonavir lead to increased odds of liver injury [51]. This observation is in line with results from a retrospective study in 148 patients in Shangai Hospital, showing that abnormal liver function tests was more frequent among those receiving lopinavir/ritonavir after hospital admission [62]. Remdesivir, a nucleoside analog prodrug developed by Gilead Sciences (USA), is effective against COVID-19 replication in vitro [116] and in infected patients [117]. This drug produced similar effects on liver enzymes [118]. Hydroxy Chloroquine sulphate is also effective in vitro [116] and, in COVID-19 patients for short periods, appears to safe. Rare case of fulminant hepatic failure have been described with Hydroxy Chloroquine [119, 120]. Acute liver injury is also possible after azithromycin treatment, with a clinically evident presentation following about two weeks after drug cessation, and after an average duration of treatment of 4 days [121]. Several patients with concomitant diseases (i.e. diabetes type 1 or 2, or hypertensive), undergo antihypertensive therapies with ACE inhibitors and angiotensin II type I receptor blockers. In this context, a possibility is the onset of ACE2 over-expression. Whether this condition will facilitate COVID-19 infection and penetrance, deserves further attention [122, 123]. There is no evidence, however, that ACE inhibitors will worsen the consequence of infection [123]. Many patients with fever use antipyretic agents, namely acetaminophen [124]. This drug might mediate, at least in part, the liver damage [57].

Patients with underlying metabolic abnormalities and NAFLD might be more exposed to drug-induced liver damage (DILI) [99, 108]. As mentioned earlier, the cytokine MCP-1 is often increased in COVID-19 patients [42] and act as a further hit for steatohepatitis [125]. In addition, patients with NAFLD/nonalcoholic steatohepatitis (NASH) COVID-19 infection, might be more susceptible to DILI, as well as to therapy with steatogenic drugs (amiodarone, sodium valproate, tamoxifen and methotrexate), and/or ischemic damage to the liver [108].

According to the recent AASLD guidelines, regular monitoring of liver function should be considered in all hospitalized COVID-19 patients, in particular in those treated with remdesivir or tocilizumab, irrespective of baseline value of liver biochemistry [105].

Thus, mainly due to possible interplay between mechanisms of liver damage promoted by SARS-CoV-2 infection and potential drug-induced hepatic side-effects, liver function tests should be carefully monitored independently from the presence of a pre-existing liver disease. This is particularly true when using biological agents against targeting the inflammatory/immunological responses.

5. Conclusion

Preliminary observations accumulated from China, following the COVID-19 outbreak in Wuhan, show that liver involvement during

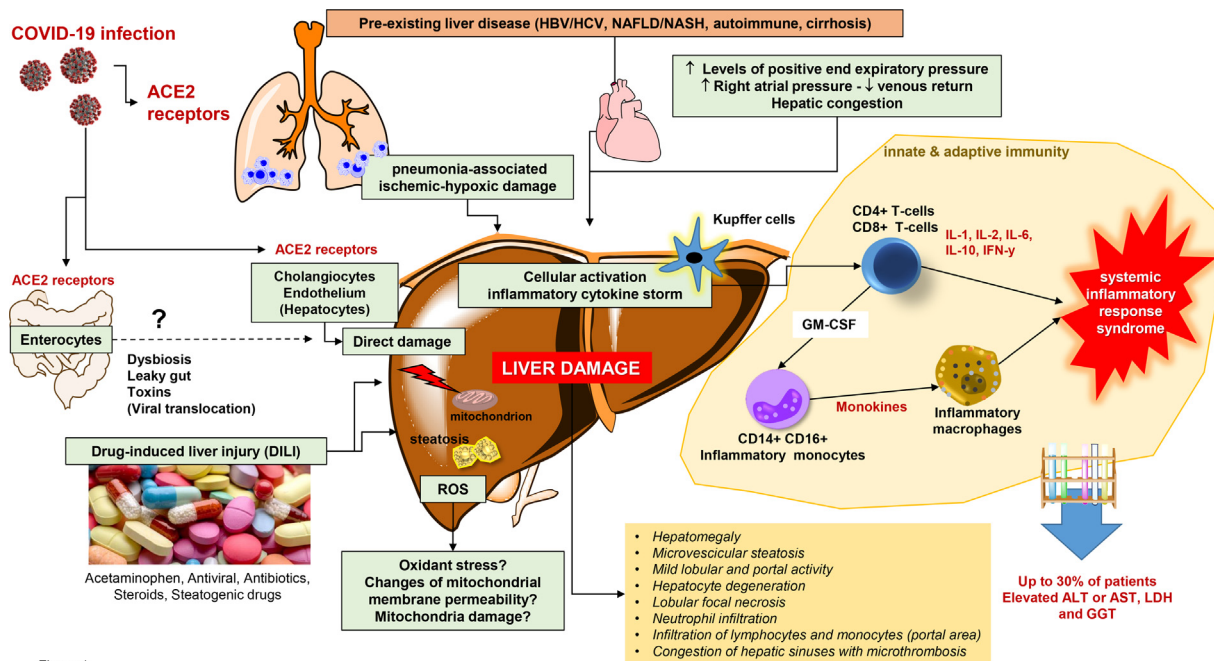


Figure 1

Figure 1. Major mechanisms involved in the pathogenesis of liver damage during COVID-19 infection. The COVID-19 infection implies the first interaction between the virus and the angiotensin-converting enzyme 2 (ACE2) receptors (expressed in the lung, gastrointestinal tract, cholangiocytes, and vascular endothelium). Several factors contribute to liver damage, namely direct viral effect, drug-induced liver injury (including the underlying effect of steatogenic drugs, see text), pre-existing liver disease, hepatic congestion, ischemic-hypoxic damage. Such factors activate the inflammatory “cytokine storm”, when pathogenic T cells are activated. Production of granulocyte-macrophage colony-stimulating factor (GM-CSF), interleukin (IL)-6 and other proinflammatory factors is the next step. Inflammatory monocytes CD14 + CD16 + respond to GM-CSF, producing a larger amount of IL-6 and other proinflammatory factors. The inflammatory “storm” evolve to immune damage in other organs such as lungs and the liver. Additional mechanisms of damage might include the intestine (abnormal permeability? Viral persistence in enterocytes? Dysbiosis? Leaky gut and production of toxins travelling to the liver via portal vein?), and liver mitochondrial dysfunction, as a source of oxidant stress and production of reactive oxygen species (ROS).

Abbreviations: ACE2, angiotensin-converting enzyme 2; ALT, alanine aminotransferase; AST, aspartate aminotransferase; GGT, gamma-glutamyl transferase; HBV, hepatitis B; HCV, hepatitis C; IFN, interferon; LDH, lactate dehydrogenase; NAFLD, non-alcoholic fatty liver disease; NASH, non-alcoholic steatohepatitis.

COVID-19 infection may affect about one-third of the patients, with prevalence greater in men than women, and in elderly. Although the manifestations of liver damage are usually mild (elevated serum aminotransferases), mechanisms are complex, and include underlying liver injury, direct cholangiopathy, use of antiviral drugs, hyperinflammatory status, and underlying hypoxia (Figure 1). Thus, the appearance of liver involvement during COVID-19 infection requires attention. This is particularly true since typical patients are older, with a pre-existing history of liver diseases, and essentially because the prognosis of lung infection is worse, and hospital stay is longer. Furthermore, the impact of COVID-19 on subjects with pre-existing liver diseases should be clarified. Position papers from scientific societies on the management of such patients are appearing, in this respect [86].

Declaration of Competing Interest

The authors have no financial or other interest in the product or distributor of the product. Furthermore, they have no other kinds of associations, such as consultancies, stock ownership, or other equity interests or patent-licensing arrangements.

Author Contribution

Each author contributed substantially to the work with access to all materials and data. PP and ADC wrote the initial draft. MK and AM provided systematic literature review. FL and PP reviewed the final version of the paper. The corresponding author had final responsibility for the decision to submit for publication.

References

- [1] World Health Organization. Coronavirus disease 2019 (COVID 19). Situation Report - 72. Geneva: World Health Organization; 2020.
- [2] World Health Organization. Coronavirus disease (COVID-19) Pandemic. Vol. 2020. Geneva: World Health Organization; 2020.
- [3] European Centre for Disease Prevention and Control. Novel coronavirus in China. Geneva: World Health Organization; 2020.
- [4] Verelst F, Kuylen E, Beutels P. Indications for healthcare surge capacity in European countries facing an exponential increase in coronavirus disease (COVID-19) cases, March 2020. *Euro Surveill* 2020;25.
- [5] Mannelli C. Whose life to save? Scarce resources allocation in the COVID-19 outbreak. *J Med Ethics* 2020.
- [6] Albano D, Bertagna F, Bertolia M, Bosio G, Lucchini S, Motta F, et al. Incidental Findings Suggestive of Covid-19 in Asymptomatic Patients Undergoing Nuclear Medicine Procedures in a High Prevalence Region. *J Nucl Med* 2020.
- [7] Gandhi M, Yokoe DS, Havlir DV. Asymptomatic Transmission, the Achilles' Heel of Current Strategies to Control Covid-19. *N Engl J Med* 2020.
- [8] Arons MM, Hatfield KM, Reddy SC, Kimball A, James A, Jacobs JR, et al. Presymptomatic SARS-CoV-2 Infections and Transmission in a Skilled Nursing Facility. *N Engl J Med* 2020.
- [9] Siddiqi HK, Mehra MR. COVID-19 illness in native and immunosuppressed states: a clinical-therapeutic staging proposal. *The Journal of Heart and Lung Transplantation* 2020.
- [10] Wang D, Hu B, Hu C, Zhu F, Liu X, Zhang J, et al. Clinical Characteristics of 138 Hospitalized Patients With 2019 Novel Coronavirus-Infected Pneumonia in Wuhan, China. *JAMA* 2020.
- [11] Gu J, Han B, Wang J. COVID-19: Gastrointestinal Manifestations and Potential Fecal-Oral Transmission. *Gastroenterology* 2020.
- [12] Gao QY, Chen YX, Fang JY. Novel coronavirus infection and gastrointestinal tract. *J Dig Dis* 2019;21:125–6. 2020.
- [13] Bangash MN, Patel J, Parekh D. COVID-19 and the liver: little cause for concern. *Lancet Gastroenterol Hepatol* 2020.
- [14] Li J, Fan JG. Characteristics and Mechanism of Liver Injury in 2019 Coronavirus Disease. *J Clin Transl Hepatol* 2020;8:13–7.
- [15] Rismanbaf A, Zarei S. Liver and Kidney Injuries in COVID-19 and Their Effects on Drug Therapy; a Letter to Editor. *Arch Acad Emerg Med* 2020;8:e17.
- [16] Jamil S, Mark N, Carlos G, Dela Cruz CS, Gross JE, Pasnick S. Diagnosis and

- Management of COVID-19 Disease. *Am J Respir Crit Care Med* 2020.
- [17] Loeffelholz MJ, Tang YW. Laboratory diagnosis of emerging human coronavirus infections - the state of the art. *Emerg Microbes Infect* 2020;9:747–56.
- [18] Zheng YY, Ma YT, Zhang JY, Xie X. COVID-19 and the cardiovascular system. *Nat Rev Cardiol* 2020;17:259–60.
- [19] Madjid M, Safavi-Naeini P, Solomon SD, Vardeny O. Potential Effects of Coronaviruses on the Cardiovascular System: A Review. *JAMA Cardiol* 2020.
- [20] Bonow RO, Fonarow GC, O'Gara PT, Yancy CW. Association of Coronavirus Disease 2019 (COVID-19) With Myocardial Injury and Mortality. *JAMA Cardiol* 2020.
- [21] Chen T, Wu D, Chen H, Yan W, Yang D, Chen G, et al. Clinical characteristics of 113 deceased patients with coronavirus disease 2019: retrospective study. *BMJ* 2020;368:m1091.
- [22] Maddaloni E and Buzzetti R. Covid-19 and diabetes mellitus: unveiling the interaction of two pandemics. *Diabetes Metab Res Rev* 2020:e33213321.
- [23] Guo W, Li M, Dong Y, Zhou H, Zhang Z, Tian C, et al. Diabetes is a risk factor for the progression and prognosis of COVID-19. *Diabetes Metab Res Rev* 2020:e3319.
- [24] Novel Coronavirus Pneumonia Emergency Response Epidemiology T. [The epidemiological characteristics of an outbreak of 2019 novel coronavirus diseases (COVID-19) in China]. *Zhonghua Liu Xing Bing Xue Za Zhi* 2020;41:145–51.
- [25] Redd WD, Zhou JC, Hathorn KE, McCarty TR, Bazarbashi AN, Thompson CC, et al. Prevalence and Characteristics of Gastrointestinal Symptoms in Patients with SARS-CoV-2 Infection in the United States: A Multicenter Cohort Study. *Gastroenterology* 2020.
- [26] Jin X, Lian JS, Hu JH, Gao J, Zheng L, Zhang YM, et al. Epidemiological, clinical and virological characteristics of 74 cases of coronavirus-infected disease 2019 (COVID-19) with gastrointestinal symptoms. *Gut* 2020.
- [27] Cheung KS, Hung IF, Chan PP, Lung KC, Tso E, Liu R, et al. Gastrointestinal Manifestations of SARS-CoV-2 Infection and Virus Load in Fecal Samples from the Hong Kong Cohort and Systematic Review and Meta-analysis. *Gastroenterology* 2020.
- [28] Zhang H, Kang Z, Gong H, Xu D, Wang J, Li Z, et al. The digestive system is a potential route of 2019-nCoV infection: a bioinformatics analysis based on single-cell transcriptomes. *BioRxiv* 2020.
- [29] Liang W, Feng Z, Rao S, Xiao C, Xue X, Lin Z, et al. Diarrhoea may be underestimated: a missing link in 2019 novel coronavirus. *Gut* 2020.
- [30] Lamers MM, Beumer J, van der Vaart J, Knoops K, Puschhof J, Breugem TI, et al. SARS-CoV-2 productively infects human gut enterocytes. *Science* 2020.
- [31] Wu Y, Guo C, Tang L, Hong Z, Zhou J, Dong X, et al. Prolonged presence of SARS-CoV-2 viral RNA in faecal samples. *Lancet Gastroenterol Hepatol* 2020;5:434–5.
- [32] Li Y, Hu Y, Yu Y, Zhang X, Li B, Wu J, et al. Positive result of Sars-Cov-2 in faeces and sputum from discharged patient with COVID-19 in Yiwu. China. *J Med Virol* 2020.
- [33] Wolfel R, Corman VM, Guggemos W, Seilmaier M, Zange S, Muller MA, et al. Virological assessment of hospitalized patients with COVID-2019. *Nature* 2020.
- [34] Nobel YR, Phipps M, Zucker J, Lebwohl B, Wang TC, Sobieszczyk ME, et al. Gastrointestinal Symptoms and COVID-19: Case-Control Study from the United States. *Gastroenterology* 2020.
- [35] Zou X, Chen K, Zou J, Han P, Hao J, Han Z. Single-cell RNA-seq data analysis on the receptor ACE2 expression reveals the potential risk of different human organs vulnerable to 2019-nCoV infection. *Front Med* 2020.
- [36] Qi F, Qian S, Zhang S, Zhang Z. Single cell RNA sequencing of 13 human tissues identify cell types and receptors of human coronaviruses. *Biochem Biophys Res Commun* 2020;526:135–40.
- [37] Li W, Moore MJ, Vasilieva N, Sui J, Wong SK, Berne MA, et al. Angiotensin-converting enzyme 2 is a functional receptor for the SARS coronavirus. *Nature* 2003;426:450–4.
- [38] Hoffmann M, Kleine-Weber H, Krüger N, Mueller MA, Drosten C, Pöhlmann S. The novel coronavirus 2019 (2019-nCoV) uses the SARS-coronavirus receptor ACE2 and the cellular protease TMPRSS2 for entry into target cells. *BioRxiv* 2020.
- [39] Hamming I, Timens W, Bulthuis ML, Lely AT, Navis G, van Goor H. Tissue distribution of ACE2 protein, the functional receptor for SARS coronavirus. A first step in understanding SARS pathogenesis. *J Pathol* 2004;203:631–7.
- [40] Pedersen SF, Ho YC. SARS-CoV-2: a storm is raging. *J Clin Invest* 2020;130:2202–5.
- [41] Mehta P, McAuley DF, Brown M, Sanchez E, Tattersall RS, Manson JJ, et al. COVID-19: consider cytokine storm syndromes and immunosuppression. *Lancet* 2020;395:1033–4.
- [42] Huang C, Wang Y, Li X, Ren L, Zhao J, Hu Y, et al. Clinical features of patients infected with 2019 novel coronavirus in Wuhan. China. *Lancet* 2020;395:497–506.
- [43] Han H, Yang L, Liu R, Liu F, Wu KL, Li J, et al. Prominent changes in blood coagulation of patients with SARS-CoV-2 infection. *Clin Chem Lab Med* 2020.
- [44] Tang N, Li D, Wang X, Sun Z. Abnormal coagulation parameters are associated with poor prognosis in patients with novel coronavirus pneumonia. *J Thromb Haemost* 2020;18:844–7.
- [45] Lillcrap D. Disseminated intravascular coagulation in patients with 2019-nCoV pneumonia. *J Thromb Haemost* 2020;18:786–7.
- [46] Henry BM, de Oliveira MHS, Benoit S, Plebani M, Lippi G. Hematologic, biochemical and immune biomarker abnormalities associated with severe illness and mortality in coronavirus disease 2019 (COVID-19): a meta-analysis. *Clin Chem Lab Med* 2020.
- [47] Uhlen M, Fagerberg L, Hallstrom BM, Lindskog C, Oksvold P, Mardinoglu A, et al. Proteomics. Tissue-based map of the human proteome. *Science* 2015;347:1260419.
- [48] Chen N, Zhou M, Dong X, Qu J, Gong F, Han Y, et al. Epidemiological and clinical characteristics of 99 cases of 2019 novel coronavirus pneumonia in Wuhan, China: a descriptive study. *Lancet* 2020;395:507–13.
- [49] Guan WJ, Ni ZY, Hu Y, Liang WH, Ou CQ, He JX, et al. Clinical Characteristics of Coronavirus Disease 2019 in China. *N Engl J Med* 2020;382:1708–20.
- [50] Liu Q, Wang RS, Qu GQ, Wang YY, Liu P, Zhu YZ, et al. Gross examination report of a COVID-19 death autopsy. *Fa Yi Xue Za Zhi* 2020;36:21–3.
- [51] Cai Q, Huang D, Yu H, Zhu Z, Xia Z, Su Y, et al. Characteristics of Liver Tests in COVID-19 Patients. *J Hepatol* 2020.
- [52] Guo T, Fan Y, Chen M, Wu X, Zhang L, He T, et al. Cardiovascular Implications of Fatal Outcomes of Patients With Coronavirus Disease 2019 (COVID-19). *JAMA Cardiol* 2020.
- [53] Lee IC, Huo TI, Huang YH. Gastrointestinal and Liver Manifestations in Patients with COVID-19. *J Chin Med Assoc* 2020.
- [54] Chen P, Lei J, Wu Y, Liu G, Zhou B. Liver impairment associated with disease progression in COVID-19 patients. *Liver Int* 2020.
- [55] Zhang C, Shi L, Wang FS. Liver injury in COVID-19: management and challenges. *Lancet Gastroenterol Hepatol* 2020;5:428–30.
- [56] Shi H, Han X, Jiang N, Cao Y, Alwalid O, Gu J, et al. Radiological findings from 81 patients with COVID-19 pneumonia in Wuhan, China: a descriptive study. *Lancet Infect Dis* 2020;20:425–34.
- [57] Xu Z, Shi L, Wang Y, Zhang J, Huang L, Zhang C, et al. Pathological findings of COVID-19 associated with acute respiratory distress syndrome. *Lancet Respir Med* 2020;8:420–2.
- [58] Xu L, Liu J, Lu M, Yang D, Zheng X. Liver injury during highly pathogenic human coronavirus infections. *Liver Int* 2020.
- [59] Yang X, Yu Y, Xu J, Shu H, Xia J, Liu H, et al. Clinical course and outcomes of critically ill patients with SARS-CoV-2 pneumonia in Wuhan, China: a single-centered, retrospective, observational study. *Lancet Respir Med* 2020.
- [60] Lei F, Liu YM, Zhou F, Qin JJ, Zhang P, Zhu L, et al. Longitudinal association between markers of liver injury and mortality in COVID-19 in China. *Hepatology* 2020.
- [61] Feng G, Zheng KI, Yan QQ, Rios RS, Targher G, Byrne CD, et al. COVID-19 and Liver Dysfunction: Current Insights and Emergent Therapeutic Strategies. *J Clin Transl Hepatol* 2020;8:18–24.
- [62] Fan Z, Chen L, Li J, Cheng X, Jingmao Y, Tian C, et al. Clinical Features of COVID-19-Related Liver Damage. *Clin Gastroenterol Hepatol* 2020.
- [63] Xu H, Zhong L, Deng J, Peng J, Dan H, Zeng X, et al. High expression of ACE2 receptor of 2019-nCoV on the epithelial cells of oral mucosa. *Int J Oral Sci* 2020;12:8.
- [64] Li R, Qiao S, Zhang G. Analysis of angiotensin-converting enzyme 2 (ACE2) from different species sheds some light on cross-species receptor usage of a novel coronavirus 2019-nCoV. *J Infect* 2020;80:469–96.
- [65] Chau TN, Lee KC, Yao H, Tsang TY, Chow TC, Yeung YC, et al. SARS-associated viral hepatitis caused by a novel coronavirus: report of three cases. *Hepatology* 2004;39:302–10.
- [66] Tan YJ, Fielding BC, Goh PY, Shen S, Tan TH, Lim SG, et al. Overexpression of 7a, a protein specifically encoded by the severe acute respiratory syndrome coronavirus, induces apoptosis via a caspase-dependent pathway. *J Virol* 2004;78:14043–7.
- [67] Duan ZP, Chen Y, Zhang J, Zhao J, Lang ZW, Meng FK, et al. [Clinical characteristics and mechanism of liver injury in patients with severe acute respiratory syndrome]. *Zhonghua Gan Zang Bing Xue Za Zhi* 2003;11:493–6.
- [68] Zhang Y, Zheng L, Liu L, Zhao M, Xiao J, Zhao Q. Liver impairment in COVID-19 patients: a retrospective analysis of 115 cases from a single center in Wuhan city, China. *Liver Int* 2020.
- [69] Lu H, Ai J, Shen Y, Li Y, Li T, Zhou X, et al. A descriptive study of the impact of diseases control and prevention on the epidemics dynamics and clinical features of SARS-CoV-2 outbreak in Shanghai, lessons learned for metropolis epidemics prevention. *medRxiv* 2020.
- [70] Li J, Li RJ, Lv GY, Liu HQ. The mechanisms and strategies to protect from hepatic ischemia-reperfusion injury. *Eur Rev Med Pharmacol Sci* 2015;19:2036–47.
- [71] Strnad P, Tacke F, Koch A, Trautwein C. Liver - guardian, modifier and target of sepsis. *Nat Rev Gastroenterol Hepatol* 2017;14:55–66.
- [72] Guan GW, Gao L, Wang JW, Wen XJ, Mao TH, Peng SW, et al. [Exploring the mechanism of liver enzyme abnormalities in patients with novel coronavirus-infected pneumonia]. *Zhonghua Gan Zang Bing Xue Za Zhi* 2020;28:E002.
- [73] Chai X, Hu L, Zhang Y, Han W, Lu Z, Ke A, et al. Specific ACE2 expression in cholangiocytes may cause liver damage after 2019-nCoV infection. *bioRxiv* 2020.
- [74] Dar WA, Sullivan E, Bynon JS, Eltzschig H, Ju C. Ischaemia reperfusion injury in liver transplantation: Cellular and molecular mechanisms. *Liver Int* 2019;39:788–801.
- [75] Prompetchara E, Ketloy C, Palaga T. Immune responses in COVID-19 and potential vaccines: Lessons learned from SARS and MERS epidemic. *Asian Pac J Allergy Immunol* 2020;38:1–9.
- [76] Tartey S, Takeuchi O. Pathogen recognition and Toll-like receptor targeted therapeutics in innate immune cells. *Int Rev Immunol* 2017;36:57–73.
- [77] Klimstra WB, Ryman KD, Bernard KA, Nguyen KB, Biron CA, Johnston RE. Infection of neonatal mice with sindbis virus results in a systemic inflammatory response syndrome. *J Virol* 1999;73:10387–98.
- [78] Adams DH, Hubscher SG. Systemic viral infections and collateral damage in the liver. *Am J Pathol* 2006;168:1057–9.
- [79] Simon AK, Hollander GA, McMichael A. Evolution of the immune system in humans from infancy to old age. *Proc Biol Sci* 2015;282:20143085.
- [80] Xie J, Yang L, Tian L, Li W, Yang L, Li L. Macrophage Migration Inhibitor Factor Upregulates MCP-1 Expression in an Autocrine Manner in Hepatocytes during Acute Mouse Liver Injury. *Sci Rep* 2016;6:27665.
- [81] Zhang XJ, Cheng X, Yan ZZ, Fang J, Wang X, Wang W, et al. An ALOX12-12-HETE-GPR31 signaling axis is a key mediator of hepatic ischemia-reperfusion injury. *Nat*

- Med 2018;24:73–83.
- [82] Nardo B, Grattagliano I, Domenicali M, Caraceni P, Catena F, Santoni B, et al. Mitochondrial oxidative injury in rat fatty livers exposed to warm ischemia-reperfusion. *Transplantation proceedings* 32. Elsevier; 2000. p. 51.
- [83] Caraceni P, Domenicali M, Vendemiale G, Grattagliano I, Pertosa A, Nardo B, et al. The reduced tolerance of rat fatty liver to ischemia reperfusion is associated with mitochondrial oxidative injury. *Journal of Surgical Research* 2005;124:160–8.
- [84] Centers for Disease Control and Prevention. People who are at higher risk for severe illness. 2020.
- [85] Huang Y-h, Gao Z-l. Study of the relationship SARS and hepatitis virus B. *Chinese Journal of Clinical Hepatology* 2003;10.
- [86] Boettler T, Newsome PN, Mondelli MU, Maticic M, Cordero E, Cornberg M, et al. Care of patients with liver disease during the COVID-19 pandemic: EASL-ESCMID position paper. *JHEP Rep* 2020;2:100113.
- [87] Wang FS, Fan JG, Zhang Z, Gao B, Wang HY. The global burden of liver disease: the major impact of China. *Hepatology* 2014;60:2099–108.
- [88] Xiao Y, Pan H, She Q, Wang F, Chen M. Prevention of SARS-CoV-2 infection in patients with decompensated cirrhosis. *Lancet Gastroenterol Hepatol* 2020.
- [89] Williams CD, Stengel J, Asike MI, Torres DM, Shaw J, Contreras M, et al. Prevalence of Nonalcoholic Fatty Liver Disease and Nonalcoholic Steatohepatitis Among a Largely Middle-Aged Population Utilizing Ultrasound and Liver Biopsy: A Prospective Study. *Gastroenterology* 2011;140:124–31.
- [90] Vernon G, Baranova A, Younossi ZM. Systematic review: the epidemiology and natural history of non-alcoholic fatty liver disease and non-alcoholic steatohepatitis in adults. *Aliment Pharmacol Ther* 2011;34:274–85.
- [91] Lazo M, Hernaez R, Eberhardt MS, Bonekamp S, Kamel I, Guallar E, et al. Prevalence of nonalcoholic fatty liver disease in the United States: the Third National Health and Nutrition Examination Survey, 1988-1994. *Am J Epidemiol* 2013;178:38–45.
- [92] Younossi ZM, Stepanova M, Afendy M, Fang Y, Younossi Y, Mir H, et al. Changes in the prevalence of the most common causes of chronic liver diseases in the United States from 1988 to 2008. *Clin Gastroenterol Hepatol* 2011;9:524-30 e1. quiz e60.
- [93] Molina-Molina E, Lunardi Baccetto R, Wang DQ, de Bari O, Krawczyk M, Portincasa P. Exercising the hepatobiliary-gut axis. The impact of physical activity performance. *Eur J Clin Invest* 2018;48:e12958.
- [94] Molina-Molina E, Krawczyk M, Stachowska E, Lammert F, Portincasa P. Non-Alcoholic Fatty Liver Disease in Non-Obese Individuals: Prevalence, Pathogenesis and Treatment. *Clin Res Hepatol Gastroenterol* 2019;43:638–45.
- [95] Zhou J, Zhou F, Wang W, Zhang XJ, Ji YX, Zhang P, et al. Epidemiological feature of NAFLD from 1999 to 2018 in China. *Hepatology* 2020. n/a.
- [96] Loomba R, Sanyal AJ. The global NAFLD epidemic. *Nat Rev Gastroenterol Hepatol* 2013;10:686–90.
- [97] Krawczyk M, Bonfrate L, Portincasa P. Nonalcoholic fatty liver disease. *Best Pract Res Clin Gastroenterol* 2010;24:695–708.
- [98] Krawczyk M, Grünhage F, Mihalache F, Acalovschi M, Lammert F. The common adiponutrin variant p. I148M, a common genetic risk factor for severe forms of NAFLD and ALD, in gallstone patients. *Zeitschrift für Gastroenterologie* 2010;48:P408.
- [99] Ji D, Qin E, Xu J, Zhang D, Cheng G, Wang Y, et al. Non-alcoholic fatty liver diseases in patients with COVID-19: A retrospective study. *J Hepatol* 2020.
- [100] Prins GH, Olinga P. Potential implications of COVID-19 in non-alcoholic fatty liver disease. *Liver Int* 2020.
- [101] Paizis G, Tikellis C, Cooper ME, Schembri JM, Lew RA, Smith AI, et al. Chronic liver injury in rats and humans upregulates the novel enzyme angiotensin converting enzyme 2. *Gut* 2005;54:1790–6.
- [102] Fricker ZP, Pedley A, Massaro JM, Vasan RS, Hoffmann U, Benjamin EJ, et al. Liver Fat Is Associated With Markers of Inflammation and Oxidative Stress in Analysis of Data From the Framingham Heart Study. *Clin Gastroenterol Hepatol* 2019;17:1157–64. e4.
- [103] Feldman A, Eder SK, Felder TK, Paulweber B, Zandanel S, Stechemesser L, et al. Clinical and metabolic characterization of obese subjects without non-alcoholic fatty liver: A targeted metabolomics approach. *Diabetes Metab* 2019;45:132–9.
- [104] Jarrar MH, Baranova A, Collantes R, Ranard B, Stepanova M, Bennett C, et al. Adipokines and cytokines in non-alcoholic fatty liver disease. *Aliment.Pharmacol.Ther* 2008;27:412–21.
- [105] Fix OK, Hameed B, Fontana RJ, Kwok RM, McGuire BM, Mulligan DC, et al. Clinical Best Practice Advice for Hepatology and Liver Transplant Providers During the COVID-19 Pandemic: AASLD Expert Panel Consensus Statement. *Hepatology* 2020.
- [106] Lleo A, Invernizzi P, Lohse AW, Aghemo A, Carbone M. Highlights for management of patients with Autoimmune Liver Disease during COVID-19 pandemic. *J Hepatol* 2020.
- [107] Tapper EB, Asrani SK. The COVID-19 pandemic will have a long-lasting impact on the quality of cirrhosis care. *J Hepatol* 2020.
- [108] Boeckmans J, Rodrigues RM, Demuyser T, Pierard D, Vanhaecke T, Rogiers V. COVID-19 and drug-induced liver injury: a problem of plenty or a petty point? *Arch Toxicol* 2020.
- [109] Li SQ, Wan XD, Zhu S, Han HM, Xu ZS, Lu HJ. Establishment of a new animal model of azithromycin-induced liver injury and study the molecular pathological change during the process. *Hum Exp Toxicol* 2016;35:511–25.
- [110] Ellison CA and Blackwell SB. Acute Hepatocellular Injury Associated With Azithromycin. *J Pharm Pract* 2020;897190019894428.
- [111] Yeh RF, Gaver VE, Patterson KB, Rezk NL, Baxter-Meheux F, Blake MJ, et al. Lopinavir/ritonavir induces the hepatic activity of cytochrome P450 enzymes CYP2C9, CYP2C19, and CYP1A2 but inhibits the hepatic and intestinal activity of CYP3A as measured by a phenotyping drug cocktail in healthy volunteers. *J Acquir Immune Defic Syndr* 2006;42:52–60.
- [112] Abdel Galil SM. Hydroxychloroquine-induced toxic hepatitis in a patient with systemic lupus erythematosus: a case report. *Lupus* 2015;24:638–40.
- [113] Lee JY, Vinayagamoorthy N, Han K, Kwok SK, Ju JH, Park KS, et al. Association of Polymorphisms of Cytochrome P450 2D6 With Blood Hydroxychloroquine Levels in Patients With Systemic Lupus Erythematosus. *Arthritis Rheumatol* 2016;68:184–90.
- [114] Utkarsh D, Loretz C, Li AP. In vitro evaluation of hepatotoxic drugs in human hepatocytes from multiple donors: Identification of P450 activity as a potential risk factor for drug-induced liver injuries. *Chem Biol Interact* 2016;255:12–22.
- [115] Bao Y, Wang P, Shao X, Zhu J, Xiao J, Shi J, et al. Acetaminophen-Induced Liver Injury Alters Expression and Activities of Cytochrome P450 Enzymes in an Age-Dependent Manner in Mouse Liver. *Drug Metab Dispos* 2020;48:326–36.
- [116] Wang M, Cao R, Zhang L, Yang X, Liu J, Xu M, et al. Remdesivir and chloroquine effectively inhibit the recently emerged novel coronavirus (2019-nCoV) in vitro. *Cell Res* 2020;30:269–71.
- [117] Holshue ML, DeBolt C, Lindquist S, Lofy KH, Wiesman J, Bruce H, et al. First Case of 2019 Novel Coronavirus in the United States. *N Engl J Med* 2020;382:929–36.
- [118] Kujawski SA, Wong KK, Collins JP, Epstein L, Killerby ME, Midgley CM, et al. 2020.
- [119] Makin AJ, Wendon J, Fitt S, Portmann BC, Williams R. Fulminant hepatic failure secondary to hydroxychloroquine. *Gut* 1994;35:569–70.
- [120] Liu J, Cao R, Xu M, Wang X, Zhang H, Hu H, et al. Hydroxychloroquine, a less toxic derivative of chloroquine, is effective in inhibiting SARS-CoV-2 infection in vitro. *Cell Discov* 2020;6:16.
- [121] Martinez MA, Vuppalachari R, Fontana RJ, Stolz A, Kleiner DE, Hayashi PH, et al. Clinical and histologic features of azithromycin-induced liver injury. *Clin Gastroenterol Hepatol* 2015;13:369-76 e3.
- [122] Fang L, Karakiulakis G, Roth M. Are patients with hypertension and diabetes mellitus at increased risk for COVID-19 infection? *The Lancet. Respiratory Medicine* 2020.
- [123] FitzGerald GA. Misguided drug advice for COVID-19. *Science* 2020;367:1434.
- [124] Deng SQ, Peng HJ. Characteristics of and Public Health Responses to the Coronavirus Disease 2019 Outbreak in China. *J Clin Med* 2020;9:575.
- [125] Gao B, Tsukamoto H. Inflammation in Alcoholic and Nonalcoholic Fatty Liver Disease: Friend or Foe? *Gastroenterology* 2016;150:1704–9.
- [126] Tian S, Xiong Y, Liu H, Niu L, Guo J, Liao M, et al. Pathological study of the 2019 novel coronavirus disease (COVID-19) through postmortem core biopsies. *Mod Pathol* 2020.