

Reliability of forced internal rotation and active internal rotation to assess lateral instability of the biceps pulley

PAOLO ARRIGONI¹, GIACOMO DELLE ROSE², RICCARDO D'AMBROSI¹, GIORGIO ROTUNDO³, VINCENZO CAMPAGNA³, PIERGIORGIO PIRANI⁴, MANLIO PANASCI⁴, DARIO PETRICCIOLI⁵, CELESTE BERTONE⁵, ANDREA GRASSO⁶, CARMINE LATTE⁶, ALBERTO COSTA⁷, GINO VIOLA⁷, SILVANA DE GIORGI⁸, ANTONELLO PANELLA⁹, ROBERTO PADUA², ALESSANDRO BECCARINI¹⁰, BARBARA SALCHER¹⁰, MATTEO OLIVIERI¹¹, MARCO MUGNAINI¹¹, ANTONELLO PANNONE¹², CHIARA CEOLDO¹², UMILE GIUSEPPE LONGO¹³, VINCENZO DENARO¹³, SIMONE CERCIELLO¹⁴, ALFREDO SCHIAVONE PANNI¹⁴, PAOLO AVANZI¹⁵, CLAUDIO ZORZI¹⁵, VINCENZA RAGONE¹, ALESSANDRO CASTAGNA², PIETRO RANDELLI¹

¹IRCCS Policlinico San Donato, San Donato Milanese, Milan, Italy

²IRCCS Istituto Clinico Humanitas, Rozzano, Italy

³Policlinico Militare di Roma Celio, Italy

⁴Maria Cecilia Hospital, Cotignola, Ravenna, Italy

⁵Istituto Clinico Città di Brescia, Italy

⁶Casa di Cura Villa Valeria, Rome, Italy

⁷Ospedale Orlandi, Bussolengo, Verona, Italy

⁸University of Bari, Italy

⁹Policlinico di Bari, Italy

¹⁰Clinica Lami, Perugia, Italy

¹¹Ospedale Valdelsa, Poggibonsi, Italy

¹²Casa di Cura Città di Udine, Udine, Italy

¹³Campus Bio-Medico University, Rome, Italy

¹⁴Università degli Studi del Molise, Campobasso, Italy

¹⁵Ospedale Sacro Cuore Don Calabria, Negrar, Verona, Italy

Abstract

Purpose: the aim of this study was to investigate the relationship between positive painful forced internal rotation (FIR) and lateral pulley instability in the presence of a pre-diagnosed posterosuperior cuff tear. The same investigation was conducted for painful active internal rotation (AIR).

Methods: a multicenter prospective study was conducted in a series of patients scheduled to undergo

arthroscopic posterosuperior cuff repair. Pain was assessed using a visual analog scale (VAS) and the Disabilities of the Arm, Shoulder and Hand questionnaire (DASH) was administered. The VAS score at rest, DASH score, and presence/absence of pain on FIR and AIR were recorded and their relationships with lesions of the lateral pulley, cuff tear patterns and shape of lesions were analyzed.

Results: the study population consisted of 115 patients (mean age: 55.1 years) recruited from 12 centers. The dominant arm was affected in 72 cases (62.6%). The average anteroposterior extension of the lesion was 1.61 cm. The mean preoperative VAS and DASH scores were 6.1 and 41.8, respectively. FIR and AIR were positive in 94 (81.7%) and 85 (73.9%) cases, respectively. The lateral pulley was compromised

Corresponding Author:

Paolo Arrigoni, MD
IRCCS Policlinico San Donato
Piazza Edmondo Malan 1,
20097 San Donato Milanese, Milan, Italy
E-mail: arrigoni.p@gmail.com

in 50 cases (43.4%). Cuff tears were partial articular in 35 patients (30.4%), complete in 61 (53%), and partial bursal in 19 (16.5%). No statistical correlation between positive FIR or AIR and lateral pulley lesions was detected. Positive FIR and AIR were statistically associated with complete lesions. Negative FIR was associated with the presence of partial articular tears.

Conclusions: painful FIR in the presence of a posterosuperior cuff tear does not indicate lateral pulley instability. When a cuff tear is suspected, positive FIR and AIR are suggestive of full-thickness tear patterns while a negative FIR suggests a partial articular lesion.

Level of evidence: level I, validating cohort study with good reference standards.

Key Words: shoulder arthroscopy, clinical test, internal rotation, biceps pulley, diagnostic accuracy.

Introduction

The long head of the biceps tendon (LHB) is surrounded by the coracohumeral ligament (CHL), which forms a superficial layer, and by the superior glenohumeral ligament (SGHL) as an internal reflection pulley. The two ligaments present a common insertion at the opening of the bicipital groove (1). Ruptures of the lateral pulley have been reported to be commonly associated with rotator cuff tears (2).

There is a lack of clinical tests able to identify a specific population with extension of a supraspinatus-infraspinatus tear into the lateral LHB pulley. Magnetic resonance arthrography (MRA) has generally been considered the gold standard to detect pulley lesions, but high costs and invasiveness are limitations to its extensive application (3).

The purpose of this study was to investigate the relationship of painful forced (passive) internal rotation (FIR) and painful active internal rotation (AIR) with LHB lateral pulley lesions, in the presence of posterosuperior cuff tears. The relationship between FIR and AIR and cuff tear subtypes was also studied. The hypothesis was that painful FIR is significantly associated with extension of the posterosuperior tear into the lateral pulley, causing LHB instability. The same hypothesis was tested for AIR.

Methods

Study design

A multicenter, prospective study was conducted to look for correlations between clinical and surgical findings in a series of consecutive patients treated for rotator cuff tears. An invitation to participate was sent by e-mail to all members of the Italian society of knee surgery, arthroscopy, sports traumatology, cartilage and orthopaedic technology (SIGASCOT). A selected pool of centers that expressed willingness to participate formed the network for the study. Two surgeons per center were identified. Patients were considered eligible for recruitment if they were scheduled for posterosuperior (supraspinatus/infraspinatus) arthroscopic cuff repair. Further inclusion criteria were: a preoperative physical examination and MR scan confirming a posterosuperior cuff tear; grade 1 or 2 fatty degeneration – defined according to the modified Goutallier's classification (4) – of the more affected muscle between the supraspinatus and infraspinatus; retraction of the tear by a maximum of 1 cm measured on the most central coronal MR-T2 view; ability of the patient to reach an internal rotation equal or superior to the 3rd lumbar vertebral body; age 70 years or under. Patients were excluded if degeneration of the intra-articular portion of the LHB tendon was estimated to correspond to more than 50% of the width of the tendon. Patients were also excluded in the case of isolated intrasubstance supraspinatus tears, revision surgery, systemic disease, subacromial bursitis, and tears extending to the medial pulley/subscapularis tendon or involving the teres minor. Prospective enrollment of the patients began on October 1, 2011 and finished on August 30, 2012.

Data collection

FIR evaluation was performed in all patients as shown in **Figure 1**. The examiner brought the patient's hand to the maximum possible internal rotation. The result of the test was considered positive if pain was present in the test position and was recorded using a binary code (1 – positive/0 – negative). Pain on AIR was also tested, asking the patient to reach for his/her wallet pocket with the back of his/her hand. Pain at rest was

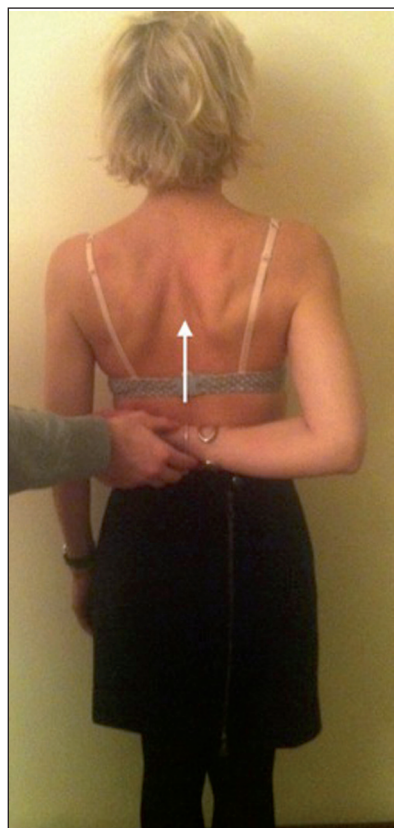


Fig. 1. Forced internal rotation (FIR) was performed in all patients. The examiner brings the patient's hand to the maximal possible internal rotation. The test is positive if the patient reports pain in the test position.

also investigated, using a visual analog scale (VAS). Finally, the Disabilities of the Arm, Shoulder and Hand (DASH) questionnaire was administered together with an optional DASH hobby and work set of questions. The DASH questionnaire consists of 30 items on disability/symptoms, scored on a scale of 0 to 5. The score ranges from 0 = best function/no symptoms to 100 = worst function/symptoms.

Arthroscopic evaluation

During the procedures all the centers were asked to record the tear patterns according to a predefined sequence: 1. Lateral pulley integrity or lesion (the latter meaning absence of intact tissue between the LHB tendon and the center of the posterosuperior cuff tear). 2. Cuff tear pattern (articular, bursal, complete), 3. Shape of the tear (L, reverse L, U, or crescent). All the data were collected using the same data form and e-mailed to the coordinating center for entry into a central database.

Statistical analysis

The statistical analysis was performed using dedicated statistical software (SPSS version 17, SPSS Inc., IBM, Chicago, IL, USA). The values of continuous variables were reported as means \pm standard deviations, whereas nominal values were reported as proportions. The association between clinical tests and tendon tears was studied using the chi-square test. For all the tests, p values less than 5% were considered statistically significant.

Results

Twelve centers agreed to participate in the study, providing information on a total of 115 patients who formed the study population. The mean age of these patients at the time of surgery was 55.1 years (range: 31-70 years). Fifty-nine were male (51.3%) and the dominant arm was affected in 72 cases (62.6%). The average extension of the anteroposterior lesion was 1.61 ± 0.87 cm). The mean preoperative VAS score was 6.1 ± 2.1 , while the mean preoperative DASH score was 41.8 ± 17.1 .

FIR and AIR were positive in 94 (81.7%) and 85 (73.9%) cases, respectively. The lateral pulley was compromised in 50 cases (43.4%). Cuff tear patterns were as follows: partial articular in 35 patients (30.4%), complete in 61 (53%), and partial bursal in 19 (16.5%). The shapes of the lesions are summarized in **Table 1**.

No significant association was found between a positive FIR or AIR and lateral pulley involvement. A positive FIR was significantly associated with the presence of a complete tear pattern ($p=0.01$). The sensitivity and specificity values were 66 and 62%, respectively. A negative FIR was significantly associated with

Table 1. Distribution and percentage of different types of rotator cuff tears.

Shape	Number	%
C-shaped	30	26.1
L-shaped	14	12.2
Reverse L-shaped	13	11.3
U-shaped	32	27.8
V-shaped	18	15.7
Not classifiable	8	7
Total	115	100

the presence of a partial articular tear pattern ($p=0.01$), with a sensitivity and specificity of 74 and 52%, respectively. FIR was not associated with the presence of bursal side lesion. A positive AIR was also significantly associated with a complete cuff lesion pattern ($p=0.006$), with a sensitivity and specificity of 83 and 60%, respectively. No significant correlations were found between a positive AIR and the presence of partial articular or bursal lesions.

Discussion

The main finding of this study was that positive FIR and AIR, in the presence of a posterosuperior cuff tear, do not correlate with a complete lesion of the lateral pulley (meaning absence of intact tissue between the center of the cuff tear and the LHB tendon). The study hypothesis was rejected.

Tears of the supraspinatus often begin from the lateral region of the bicipital groove, thus also causing an injury of the pulley system (1). Lesions of the pulley system are commonly associated with supraspinatus as well as subscapularis lesions (1). In a previous series, 15 out of 67 patients (22%) had associated extended posterosuperior lesions (supraspinatus and infraspinatus) (2) and pulley lesions. In our study population, there were 50 cases (43.4%) with complete involvement of the lateral pulley. This is a considerable percentage given that we had excluded cases with LHB degeneration corresponding to more than 50% of the width of the tendon, with subscapularis lesions and with medial pulley involvement.

A recent meta-analysis (5) focusing on clinical shoulder examination showed that the O'Brien test has a sensitivity of 38-68% in detecting LHB pathology, and a specificity of between 61 and 46% (6, 7). The same work found that Speed's test (5-8) had a sensitivity of 71% and a specificity of 85%. The limitation of this information is that the sensitivity and specificity of these tests generally refer to LHB pathology without providing further differentiation regarding the damaged areas and patterns. Our results focus on lateral instability in the presence of good quality tendon. A recent study analyzed the type and frequency of LHB instability in patients undergoing rotator cuff repair (9). Out of 200

patients with rotator cuff tears, LHB instability could be observed arthroscopically in 90 (45%) of the cases: 32 (16%) had anterior instability, 38 (19%) posterior instability, and 20 (10%) anterior and posterior instability. LHB instability was also associated with LHB lesions, with 15% of the LHB tendons having a normal appearance when unstable *versus* 70% when stable. In this series the O'Brien test showed a sensitivity of 36% for diagnosing LHB instability and a specificity of 50%. The Speed test gave similar results, with a sensitivity of 34% and a specificity of 50%. According to this series, neither the O'Brien nor the Speed test correlated with the observed LHB instability. The authors concluded that this is most likely because of the more distinct symptoms caused by rotator cuff lesions. This experience reflects our results, showing that in the presence of a rotator cuff tear the clinical evaluation, including AIR and FIR, cannot predict bicipital instability.

In the absence of a reliable clinical test, arthro-MRI remains the gold standard for diagnosing pulley lesions. A previous study (3) found a 100% correlation with arthroscopic findings in types 1 and 2 pulley instability, as well as a 71.4% correlation in type 3, defined according to the Habermayer's classification (1).

Our results also demonstrate that positive FIR and AIR are significantly associated with complete cuff lesions. Complete lesions lead to a connection between extra-articular and intra-articular spaces causing extensive inflammation in the shoulder. This inflammation can cause deep inflammatory pain in contrast to what happens with partial articular lesions. Furthermore, this inflammation can be responsible for increased pain and positivity on FIR and AIR (10). A complete lesion is definitely more prone than partial tears to torsional stresses on the remaining extremities of the tendon footprint (11). A significant correlation between partial articular lesions and negative FIR was also supported by our data. This strengthens the idea that a lesion with stable margins, such as a partial one, would cause less pain at terminal internal rotation than would a complete lesion.

The design of this study has limitations. The multi-

center nature is definitively one of them; the subjective judgement that each surgeon made when evaluating the type of lesions may have led to measurement errors between centers, introducing further bias. To mitigate this limitation, only complete communication between the supraspinatus tear and the biceps (and not pulley degeneration or minor incompetency or pure biceps degeneration) was taken to constitute a lateral pulley lesion. The presence of posterosuperior cuff tears as a baseline criterion was definitely another bias. To avoid this bias, a control group with lateral pulley lesions and no rotator cuff tears should have been included. However, by nature, a true complete lateral pulley lesion, excluding focal degeneration, will present continuity with, at least, a very anterior supraspinatus tear. We therefore believe it is probably almost impossible to eliminate this bias. Another limitation of this study was the absence of arthro-MRI pre-diagnosis, considered the gold standard for assessing injuries of the biceps pulley. The use of this type of imaging would have necessitated a considerable outlay, especially considering that not all the centers are able to provide this type of examination.

In conclusion, painful FIR in the presence of a posterosuperior cuff tear does not indicate lateral pulley instability. When a cuff tear is suspected, positive FIR and AIR are suggestive of full-thickness tear patterns while negative FIR suggests partial articular lesions.

References

1. Habermeyer P, Magosch P, Pritsch M, et al. Anterosuperior impingement of the shoulder as a result of pulley lesions: a prospective arthroscopic study. *J Shoulder Elbow Surg.* 2004; 13:5-12.
2. Braun S, Horan MP, Elser F, et al. Lesions of the biceps pulley. *Am J Sports Med.* 2011; 39:790-795.
3. Barile A, Lanni G, Conti L, et al. Lesions of the biceps pulley as cause of anterosuperior impingement of the shoulder in the athlete: potentials and limits of MR arthrography compared with arthroscopy. *Radiol Med.* 2013;118:112-122.
4. Goutallier D, Postel JM, Bernageau J, et al. Fatty muscle degeneration in cuff ruptures. Pre- and postoperative evaluation by CT scan. *Clin Orthop Relat Res.* 1994;(304):78-83.
5. Hegedus EJ, Goode AP, Cook CE, et al. Which physical examination tests provide clinicians with the most value when examining the shoulder? Update of a systematic review with meta-analysis of individual tests. *Br J Sports Med.* 2012; 46:964-978.
6. Ben Kibler W, Sciascia AD, Hester P, et al. Clinical utility of traditional and new tests in the diagnosis of biceps tendon injuries and superior labrum anterior and posterior lesions in the shoulder. *Am J Sports Med.* 2009;37:1840-1847.
7. Jia X, Petersen SA, Khosravi AH, et al. Examination of the shoulder: the past, the present, and the future. *J Bone Joint Surg Am.* 2009;91(Suppl 6):10-18.
8. Goyal P, Hemal U, Kumar R. High resolution sonographic evaluation of painful shoulder. *The Internet Journal of Radiology.* 2010;12:1.
9. Lafosse L, Reiland Y, Baier GP, et al. Anterior and posterior instability of the long head of the biceps tendon in rotator cuff tears: a new classification based on arthroscopic observations. *Arthroscopy.* 2007;23:73-80.
10. Chillemi C, Petrozza V, Garro L, et al. Rotator cuff re-tear or non-healing: histopathological aspects and predictive factors. *Knee Surg Sports Traumatol Arthrosc.* 2011;19:1588-1596.
11. Rodosky MW, Harner CD, Fu FH. The role of the long head of the biceps muscle and superior glenoid labrum in anterior stability of the shoulder. *Am J Sports Med.* 1994;22:121-130.