

# Primary Vaginal Carcinoma Arising on Cystocele Mimicking Vulvar Cancer



M. Dellino

Miriam Dellino, MD;<sup>1</sup> Carmine Carriero, MD;<sup>2</sup> Erica Silvestris, MD;<sup>1</sup> Teresa Capursi, MD;<sup>2</sup> Angelo Paradiso, MD;<sup>1</sup> Gennaro Cormio, MD<sup>3</sup>

<sup>1</sup>Gynecologic Oncology Unit, IRCCS Istituto Tumori Giovanni Paolo II, Bari, Italy

<sup>2</sup>Department of Interdisciplinary Medicine, Unit of Obstetrics and Gynecology, University of Bari, Bari, Italy

<sup>3</sup>Department of Biomedical Sciences and Human Oncology, Unit of Obstetrics and Gynecology, University of Bari Aldo Moro, Bari, Italy

## Abstract

**Background:** Primary vaginal carcinoma is a rare gynaecological tumour representing 1%–3% of all gynaecological cancers. Several studies report increased vaginal cancer risk associated with genital prolapse following the occurrence of inflammatory lesions or decubitus ulcers.

**Case:** We report the rare case of an 82-year-old woman with primary squamous cell carcinoma arising from vaginal wall prolapse. Vaginal carcinoma was suspected during gynaecological examination for vulvar bleeding. A wide local excision was performed and pathologic examination revealed a primary squamous cell carcinoma of the vagina.

**Conclusion:** Persistent genital prolapse may be at risk for vaginal carcinoma, and cytological and a colposcopic assessments are essential to identify patients who require diagnostic biopsy.

## Résumé

**Contexte :** Le carcinome vaginal primitif est une tumeur gynécologique rare qui représente de 1 % à 3 % de tous les cancers gynécologiques. Plusieurs études font état d'un risque accru de cancer du vagin associé au prolapsus génital à la suite de l'apparition de lésions inflammatoires ou d'escarres de décubitus.

**Cas :** Nous rapportons le cas rare d'une femme de 82 ans atteinte d'un carcinome épidermoïde primitif résultant d'une colpocèle. L'examen

gynécologique pour des saignements vulvaires a éveillé un soupçon de carcinome vaginal. Une exérèse locale large a été pratiquée; l'examen anatomopathologique a révélé un carcinome épidermoïde vaginal primitif.

**Conclusion :** Le prolapsus génital persistant est susceptible de mener à un carcinome vaginal; ainsi, les évaluations cytologique et colposcopique sont essentielles pour déterminer si une patiente requiert une biopsie diagnostique.

© 2020 The Society of Obstetricians and Gynaecologists of Canada/La Société des obstétriciens et gynécologues du Canada. Published by Elsevier Inc. This is an open access article under the CC BY-NC-ND license. (<http://creativecommons.org/licenses/by-nc-nd/4.0/>)

J Obstet Gynaecol Can 2020;000(000):1–3

<https://doi.org/10.1016/j.jogc.2020.03.007>

## INTRODUCTION

Primary vaginal carcinoma is a rare gynaecological tumour comprising 1% to 3% of all gynaecological cancers and with an inclination to metastasize to the cervix, vulva, endometrium, ovary, kidney, thyroid, and breast.<sup>1</sup> It typically occurs in older patients (aged 60–70 y) and is commonly located in the upper rear third of the vagina. Squamous cell carcinoma (SCC) accounts for about 85% of new cases of vaginal cancer, whereas 5% to 10% are adenocarcinoma.<sup>1</sup>

We report an unusual case of an SCC located on the prolapsed anterior vaginal wall (cystocele) and mimicking a vulvar cancer.

## CASE REPORT

An 82-year-old woman was referred to our gynaecology unit with a diagnosis of large vulvar cancer. The patient did not report any history of relevant gynaecological disease, apart from an abdominal hysterectomy about 30 years earlier for uterine fibroids and, more recently, a vaginal

**Keywords:** vulva, colposcopy, carcinoma, prolapse, vagina

Corresponding author: Miriam Dellino, [miriamdellino@hotmail.it](mailto:miriamdellino@hotmail.it)

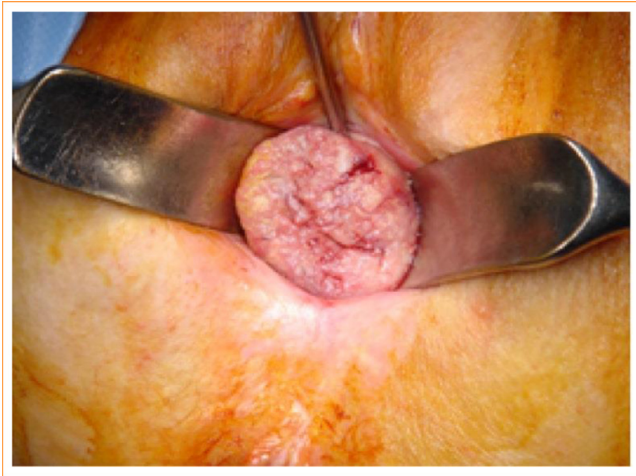
**Dislosures:** This research project has been supported in part by the Apulian Regional Project "Medicina di precisione." This work has also been supported by a grant (5 £ 1000) from the IRCCS Istituto Tumori Giovanni Paolo II in Bari, Italy (no. 332/2019) in the context of a scientific program exploring ovarian stem cell development to prevent infertility in oncology patients. The APC will be funded by IRCCS Istituto Tumori Giovanni Paolo II in Bari, Italy.

Each author has indicated that they meet the journal's requirements for authorship.

Received on February 7, 2020

Accepted on March 4, 2020

**Figure 1. Primary vaginal squamous cell carcinoma arising on prolapsed vaginal wall.**



bleeding mass. Pelvic examination revealed negative inguinal lymph nodes and a 3-cm lesion arising on the prolapsed anterior vaginal wall (cystocele; [Figure 1](#)). A biopsy was performed, and pathology examination revealed a primary SCC. Computed axial tomography was negative for distant metastatic disease, and cystoscopy revealed no bladder wall infiltration. A wide vaginal excision with bilateral groin lymph nodes dissection was performed, and pathology revealed a primary vaginal SCC with clear margins. The postoperative course was uneventful, and the patient was discharged on the fourth postoperative day. Subsequently, external beam radiotherapy followed by vaginal brachytherapy was administered. The patient died from a complication of preexisting cardiopathy in association with a recurrence of cancer in the bladder during the 2-year postoperative follow-up period. All procedures performed in this study were in accordance with the Declaration of Helsinki as revised in 2013. The patient was provided with a description of the study and was formally invited to participate in it. The patient agreed to participate in the study and gave informed consent.

## **DISCUSSION**

Cervical carcinoma combined with uterine prolapse is a rare condition, and a primary vaginal carcinoma arising in the setting of vaginal wall prolapse after hysterectomy is even more exceptional.<sup>2</sup> There is no clear explanation for the etiology of this rare association. In young patients, the disease appears to be related to human papillomavirus, whereas in older patients it may be associated with chronic inflammation due to prolapse and hormonal factors.<sup>3</sup>

Several authors report an increase in vaginal cancer risk associated with genital prolapse.<sup>1</sup> Clinical symptoms of vaginal cancer include loss of blood by external genitalia, foul-smelling leukorrhea, pelvic pain, and, in more advanced stages, urinary retention and bilateral hydronephritis.<sup>4</sup> When tumours arise from vaginal wall prolapse, the lesion is detected on objective examination and accompanied by ulcer and edema of the surrounding tissues. For this reason, it is important to note that vaginal colposcopic patterns do not have the same specificity as cervical colposcopic evaluation.<sup>5</sup> Therefore, in the case of a suspected vaginal lesion, biopsy under colposcopic guidance is indicated to check the histology and make a definitive diagnosis.<sup>6</sup>

The occurrence of inflammatory lesions or decubitus ulcers in patients with genital prolapse is quite common. Lesion histopathology reports showed chronic cervicitis in 97.9% of cases, cervical decubitus ulcers in 13.6%, and carcinoma in situ in 1%.<sup>7</sup> These findings support the need for diagnostic biopsy in all cervical or vaginal lesions located in uterine and/or vaginal prolapse to exclude a neoplastic transformation.<sup>7</sup> Because of the condition's rarity, the treatment of vaginal cancer in genital prolapse<sup>4</sup> is still difficult to standardize, and there are no treatment guidelines. Radiotherapy is associated with a reduction in morbidity and mortality,<sup>3</sup> with a better prognosis for stage I and II patients than surgery alone<sup>8</sup>; in the case of adenocarcinoma, which is usually resistant to radiotherapy, only surgery is recommended.<sup>9</sup> Exclusive radiotherapy may be suitable for more advanced stages or for early invasion of the bladder or rectum, particularly in older patients.<sup>7</sup>

Therefore, persistent genital prolapse may be considered a risk factor for vaginal carcinoma, in which case, cytological and colposcopic assessments are essential to evaluate those patients who will need a diagnostic biopsy.

## **ACKNOWLEDGEMENTS**

The woman whose story is told in this case report provided signed permission for its publication.

## **REFERENCES**

1. Kim HG, Song YJ, Na YJ, et al. A case of vaginal cancer with uterine prolapse. *J Menopausal Med* 2013;19:139–42.
2. Loizzi V, Cormio G, Selvaggi L, et al. Locally advanced cervical cancer associated with complete uterine prolapse. *Eur J Cancer Care* 2010;19:548–50.
3. Hellman K, Silfverswärd C, Nilsson B, et al. Primary carcinoma of the vagina: factors influencing the age at diagnosis. The Radiumhemmet series 1956–96. *Int J Gynecol Cancer* 2004;14:491–501.

4. Sheikh NK, Date SS, Darekar YS, et al. Vaginal carcinoma with third-degree uterine prolapse. *Int J Appl Basic Med Res* 2019;9:246–7.
5. Indraccolo U, Baldoni A. A simplified classification for describing colposcopic vaginal patterns. *J Low Genit Tract Dis* 2012;16:75–9.
6. Sonkusare S, Vishwanathb Shetty J, et al. Primary vaginal cancer complicating massive uterine prolapse: a case report. *J Cases Obstet Gynecol* 2016;3:92–5.
7. Meier HM, Schopohl B. Extensive vaginal carcinoma with total prolapse: a therapeutic problem. *Zentralbl Gynakol* 1995;117:160–3.
8. Samant R, Lau B, E C, et al. Primary vaginal cancer treated with concurrent chemoradiation using Cis-platinum. *Int J Radiat Oncol Biol Phys* 2007;69:746–50.
9. Slomovitz BM, Coleman RL, Di Saia PJ, et al. Invasive cancer of the vagina. *Clinical gynecologic oncology*, eighth ed. Philadelphia: Elsevier Saunders; 2012. p. 245–59.