

# Preliminary results of endovascular aneurysm sealing from the multicenter Italian Research on Nellix Endoprosthesis (IRENE) study



Bruno Gossetti, MD,<sup>a</sup> Ombretta Martinelli, MD,<sup>a</sup> Michelangelo Ferri, MD,<sup>b</sup> Roberto Silingardi, MD,<sup>c</sup> and Fabio Verzini, MD,<sup>d</sup> on behalf of the IRENE Group Investigators, Rome, Turin, Modena, and Perugia, Italy

## ABSTRACT

**Objective:** Because of advances in technology and experience of the operator, endovascular aneurysm repair (EVAR) has supplanted open repair to treat abdominal aortic aneurysm (AAA). The low 30-day mortality and morbidity of EVAR make the endovascular approach particularly suitable for patients at high surgical risk. However, endoleak or endograft migration requiring secondary intervention or open surgical conversion is a limitation of EVAR. The Nellix system (Endologix, Inc, Irvine, Calif) has been designed to seal the entire AAA to overcome these limitations with EVAR. We report the results of a retrospective, multicenter study with endovascular aneurysm sealing (EVAS) aimed to assess technical success, procedure-related mortality, complications, and reinterventions.

**Methods:** This study included patients selected for elective treatment with the Nellix device per the endovascular repair protocol at 16 Italian vascular centers. All patients were enrolled in a postoperative surveillance imaging program including duplex ultrasound investigations, computed tomography, and magnetic resonance controls following local standards of care.

**Results:** From 2013 to 2015, there were 335 patients (age,  $75.5 \pm 7.4$  years; 316 men) who underwent elective EVAS. In 295 cases (88.0%), EVAS was performed under standard instructions for use of the Nellix system. Preoperative aneurysm diameter was  $55.5 \pm 9.4$  mm (range, 46-65 mm). The inferior mesenteric artery and lumbar arteries emerging from the AAA were patent in 61.8% and 81.3% of cases, respectively. Chimney grafts were electively carried out in eight cases (2.4%). One (0.3%) intraprocedural type IB endoleak was observed and promptly corrected. Device deployment was successful in all patients, with no perioperative mortality. Early ( $\leq 30$  days) complications included 1 (0.3%) type IA endoleak, 2 (0.6%) type II endoleaks (0.6%), 2 (0.6%) stent occlusions (0.6%), 3 (0.9%) distal embolizations, and 2 (0.2%) femoral artery dissections. Six (2.9%) patients underwent reinterventions. At 1-year follow-up, complications included 3 (1.1%) type II endoleaks, 4 (1.4%) type IA endoleaks, 1 (0.3%) type IB endoleak, 2 (0.7%) distal stent migrations, 5 (1.8%) distal embolizations, and 1 (0.3%) stent occlusion. Twelve patients (3.7%) underwent reinterventions, including four (1.4%) surgical conversions due to aortoduodenal fistula (1), endograft infection (1), and type IA endoleak that was unsuccessfully treated percutaneously (2). Two AAA-related deaths occurred. Freedom from aneurysm-related reintervention was 98.3% at 1-month and 94.7% at 12-month follow-up.

**Conclusions:** The preliminary results of this real-world multicenter study showed that EVAS with Nellix for the management of AAAs appears feasible. This device platform is associated with acceptable procedure-related mortality and low overall complication and reintervention rates. Definitive conclusions on the value of this novel device await long-term follow-up data. (J Vasc Surg 2018;67:1397-403.)

From the Department of Vascular Surgery, "Sapienza" University of Rome, Rome<sup>a</sup>; the Vascular and Endovascular Surgery Unit, Umberto I Hospital, Turin<sup>b</sup>; the Department of Vascular Surgery, Baggiovara Hospital, Modena<sup>c</sup>; and the Unit of Vascular Surgery, University of Perugia, Hospital of Perugia, Perugia.<sup>d</sup>

Author conflict of interest: none.

Presented orally during the International Forum at the 2016 Vascular Annual Meeting of the Society for Vascular Surgery, National Harbor, Md, June 8-11, 2016.

Correspondence: Ombretta Martinelli, PhD, Department of Vascular Surgery, "Sapienza" University of Rome, Viale del Policlinico 144, Rome 00161, Italy (e-mail: ombretta.martinelli@uniroma1.it).

The editors and reviewers of this article have no relevant financial relationships to disclose per the JVS policy that requires reviewers to decline review of any manuscript for which they may have a conflict of interest.

0741-5214

Published by Elsevier Inc. on behalf of the Society for Vascular Surgery.

<https://doi.org/10.1016/j.jvs.2017.09.032>

Endovascular aneurysm repair (EVAR) is being increasingly used because of its lower perceived risk of early postoperative mortality and morbidity compared with open surgical repair.<sup>1</sup> Nonetheless, long-term data demonstrate high reintervention rates after EVAR, resulting in higher costs compared with surgical repair.<sup>2,3</sup> Endoleaks are one of the most common causes of reintervention after EVAR.<sup>4</sup> To prevent such complications, some authors suggest filling the aneurysm sac at the time of the primary standard EVAR procedure with coils and glue, reporting acceptable results.<sup>5,6</sup> Recently, a new model of endograft, the Nellix endograft (Endologix, Inc, Irvine, Calif), has been introduced, which is designed to seal the entire aneurysm sac with two polymer-filled endobags surrounding covered balloon-expandable stents. Endovascular aneurysm sealing (EVAS) with the

Nellix graft aims to minimize the risk of endoleaks and endograft migration. Early results with EVAS in multicenter registries in the United States and Europe have reported promising outcomes up to 1 year of follow-up.<sup>7,8</sup> The aim of this study was to determine the safety and efficacy of elective EVAS with the latest model of the CE-marked Nellix in a real-world experience of 16 high-volume, trained centers that participated in the Italian Research on Nellix Endoprosthesis (IRENE) study.

## METHODS

This retrospective multicenter study was performed to evaluate the Nellix endoprosthesis in the elective treatment of abdominal aortic aneurysm (AAA). This study complied with the principles of the Declaration of Helsinki, and when requested, the data collection and acquisition were approved by the local ethics committee and respective Institutional Review Boards from each site. Informed consent of the patients was obtained for the procedures but was not required for the study. Preoperative, procedural, and follow-up data were retrospectively obtained from hospital records.

Inclusion criteria for the study were juxtarenal or infrarenal aortic aneurysm requiring elective treatment, AAA diameter  $\geq 4.5$  cm, and AAA enlargement  $>1$  cm within the previous year. Preoperative computed tomography angiography (CTA) imaging assessed the characteristics of the abdominal aorta, aneurysmal sac, and iliac arteries. Aneurysm diameter, length, and volume were calculated with centerline measurements on CTA reconstructions for stent sizing. Baseline anatomic measurements were considered outside of the instructions for use (IFU) when the aortic neck length was  $<10$  mm, the aortic neck diameter was  $<18$  mm or  $>32$  mm, the infrarenal neck angulation was  $>60^\circ$ , or the blood lumen diameter was  $>60$  mm.

All patients were monitored postoperatively with clinical evaluation and duplex ultrasound or contrast-enhanced ultrasound examination before discharge and at 1 month, 6 months, 12 months, and 24 months. A 1-year control by magnetic resonance imaging (MRI) or CTA was performed in all cases per the standard surveillance program of each center. Complications that occurred during and after EVAS were classified per the reporting standards for endovascular aortic aneurysm repair.<sup>9</sup> Aneurysm sac enlargement was defined as an increase  $>5$  mm in maximum AAA diameter compared with the baseline computed tomography (CT) study. Endograft migration was defined as stent movement compared with the original location, either proximally at the infrarenal level or distally within the iliac arteries.

Continuous data were reported as mean, median, standard deviation, range (minimum-maximum), and interquartile range for continuous variables. Frequency and percentages were reported for categorical variables. Kaplan-Meier estimates reported freedom

## ARTICLE HIGHLIGHTS

- **Type of Research:** Multicenter retrospective cohort study
- **Take Home Message:** Endovascular aneurysm sealing using the Nellix device in 335 patients resulted in 4 (1.4%) type IA, 2 (0.7%) type IB, and 3 (1.1%) type II endoleaks at 1 year, with freedom from aneurysm-related reintervention in 94.7%.
- **Recommendation:** This study suggests that endovascular aneurysm sealing with the Nellix device has a low incidence of endoleaks and reinterventions at 1 year.

**Table 1.** Demographics: Age, gender, and American Society of Anesthesiologists (ASA) class

Total (N = 335)	No. (%)
Male	316 (94.3)
Female	19 (5.7)
Age, years, mean $\pm$ SD	75.5 $\pm$ 7.4
ASA class	
1	2 (0.59)
2	43 (12.83)
3	209 (62.40)
4	81 (24.18)

SD, Standard deviation.  
ASA class 1, normal healthy patient; ASA class 2, patient with mild systemic disease; ASA class 3, patient with severe systemic disease; ASA class 4, patient with severe systemic disease that is a constant threat to life.

from procedure-related complications. Statistical analysis was performed using SAS version 9.4 (SAS Institute, Cary, NC).

## RESULTS

From September 2013 to November 2015, there were 335 patients (mean age, 75.5  $\pm$  7.4 years; 316 men) who were treated with EVAS using the Nellix system at 16 Italian vascular centers. Characteristics and comorbidities of the patients are summarized in [Tables 1](#) and [II](#). In 295 (88.0%) cases, EVAS was performed within the device's IFU. Preoperative aneurysm diameter was 55.5  $\pm$  9.4 mm (range, 46-65 mm). Infrarenal aortic neck characteristics included length of 26.1  $\pm$  14.9 mm (range, 15-35 mm), diameter of 22.5  $\pm$  3.5 mm (range, 20.0-24.4 mm), and angle of 41.1  $\pm$  26.7° (range, 14.4-67.8°). The inferior mesenteric artery was patent in 61.8% of cases, and at least one pair of patent lumbar arteries emerging from the AAA was observed in 81.3% of cases. Aortic characteristics are displayed in [Table III](#), and the same parameters divided in different classes based on anatomic measurements of proximal aortic neck, aneurysmal sac, and common iliac arteries are reported in [Table IV](#). Preoperative CTA data

**Table II.** Comorbidities of the study population

Comorbidity	No. (%)
Smoke	227 (67.76)
Hypertension	211 (62.98)
Hyperlipidemia	204 (60.89)
Chronic obstructive lung disease	147 (43.88)
Coronary artery disease	134 (40.00)
Peripheral arterial disease	107 (31.94)
Myocardial infarction	97 (28.95)
Diabetes	84 (25.07)
Renal insufficiency	79 (23.58)
Angina	70 (20.89)
Coronary artery stent/bypass	64 (19.10)
Malignant disease	61 (18.20)
Transient ischemic attack/stroke	56 (16.71)
Thoracic aortic aneurysm	5 (1.49)

**Table III.** Anatomic features of the treated abdominal aortic aneurysms (AAAs)

Anatomic features <sup>a</sup>	Mean ± SD	Range
AAA diameter, mm	55.5 ± 9.4	45-65
Proximal neck diameter, mm	22.5 ± 3.5	20.0-24.4
Proximal neck length, mm	26.0 ± 14.9	15.0-35.0
Proximal neck angle, degrees	41.1 ± 26.7	14.4-67.8

*SD*, Standard deviation.  
<sup>a</sup>Data of noncompliant for Nellix use are included (aortic neck length <10 mm, aortic neck diameter <18 mm or >32 mm, infrarenal neck angulation >60°).

included the presence of proximal neck circumferential thrombus in 99 cases (29.5%), aneurysmal sac thrombus in 291 (86.9%) cases, and associated iliac artery aneurysms in 63 (18.8%) cases. Seven patients (2%) with common iliac diameters >35 mm were treated within the IFU without the need for hypogastric artery occlusion.

Local or locoregional anesthesia was used in 161 (48%) and 21 (6.3%) cases, respectively. The remaining 153 (45.7%) patients were operated on under general anesthesia per their clinical status and the anesthetic protocol for endovascular repair of each site (Table V). The choice of the different type of anesthesia was institution specific, given that several centers chose general anesthesia regardless of the access method. Femoral access was bilaterally surgical in 183 (54.7%) cases and bilaterally percutaneous in 146 (43.5%) patients. In six (1.8%) cases, femoral access was percutaneous on one side and surgical on the contralateral one. The length of Nellix stents ranged from 100 to 180 mm bilaterally, and stent graft lengths ranging from 140 to 180 mm were used in 90% of cases. A 7 atm simultaneous inflation of the balloons within the stents was used at deployment, and a

**Table IV.** Vascular characteristics of the proximal aortic neck, iliac arteries, and abdominal aortic aneurysms (AAAs)

Characteristic	No. (%)
Proximal neck diameter, mm	
<20	67 (20.0)
≥20-<25	191 (57.0)
≥25-<30	63 (19.0)
>30	14 (4.0)
Proximal neck length, mm	
<30	214 (63.9)
30-60	114 (34.0)
>60	7 (2.1)
Neck angle, degrees	
<60	322 (96.1)
61-90	13 (3.9)
Aneurysm sac diameter, mm	
<50	69 (20.7)
≥50-<60	182 (54.3)
≥60-<70	63 (18.8)
≥70	21 (6.2)
Right common iliac diameter, mm	
<15	187 (55.8)
≥15-<25	126 (37.6)
≥25-<35	16 (4.8)
≥35	6 (1.8)
Left common iliac diameter, mm	
<15	213 (63.6)
≥15-<25	105 (31.3)
≥25-<35	11 (3.3)
≥35	6 (1.8)

subsequent 30-second balloon inflation at 9 atm was performed after the filling. In all patients, the endobags were inflated with saline before filling to assess the required polymer volume. Angiography was carried out at the end of prefill. A secondary fill was performed in 16 (4.7%) cases. Polymer volume and fill pressure values are reported in Table VI. Mean operating time was 101 minutes. A planned chimney technique was employed in eight (2.4%) cases with juxtarenal aneurysms. The parallel grafts of the chimney complex were inserted in one renal artery in 4 cases, in both renal arteries in 2 cases, and in the superior mesenteric artery plus renal arteries in the remaining 2 cases.

The Nellix device was successfully deployed all cases. No type IA or type II endoleaks were detected at completion angiography. One periprocedural type IB endoleak due to the inability of an endobag to reach one of the common iliac arteries was observed. This endoleak was successfully treated with a covered stent (Advanta V12 balloon-expandable covered stent; Atrium Medical

**Table V.** Types of anesthesia employed for Nellix implant

Anesthesia	No. (%)
Epidural	3 (0.9)
General	153 (45.7)
Local	161 (48.0)
Spinal	15 (4.5)
Subarachnoid	3 (0.9)

**Table VI.** Procedural characteristics

Operative data	No.	Mean $\pm$ SD	Range
Polymer volume, mL	335	71.6 $\pm$ 30.1	20.0-205.0
Secondary filling volume, mL	16 (4.7%)	15 $\pm$ 10.9	5.0-30.0
Filling pressure, mm Hg	335	196.7 $\pm$ 15.4	170.0-270.0
Secondary filling pressure, mm Hg	16	197.0 $\pm$ 4.4	190.0-200.0

*SD*, Standard deviation.

Corporation, Hudson, NH). Two incidental hypogastric artery occlusions occurred without subsequent buttock claudication. Of the 335 patients, 329 (98.2%) recovered from the implant procedure uneventfully.

There were no deaths within 30 days of the index procedure. Through 1 year, 19 (5.6%) deaths were reported, including two deemed procedure related. At 1 year, 49 patients were lost or overdue at follow-up. There were 335 (100%) patients with 1-month follow-up data, 323 (96.4%) with 6-month data, and 267 (79.4%) with 1-year data. All patients were submitted to duplex ultrasound (74%) or contrast-enhanced ultrasound (26%) examination. At 1 month from Nellix implantation, a CT control was carried out in 147 (44%) cases and an MRI study in 32 (9.5%) cases. One-year CT and MRI data were available for 242 and 25 cases, respectively. Follow-up imaging demonstrated widely patent endograft lumens and intact endobags. There have been no aortic ruptures.

Surgical correction of access-related femoral pseudoaneurysm was needed at the level of percutaneous access in two (0.6%) cases. Eight (2.3%) patients had a distal embolization successfully treated with thromboembolism, including three cases in the first 30 days. Three (0.9%) stent occlusions were identified and treated with thrombolysis combined with subsequent dual antiplatelet therapy in one case and with adjunctive stent placement in the other two. Among these, two occlusions occurred within the first month and the other occurred 6 months after device implantation. Two (0.6%) stent migrations in the caudal direction were observed. One migration of 4 mm was associated with a type IA endoleak, which was corrected. The other migration (>5 mm) was treated with a Nellix-in-Nellix procedure

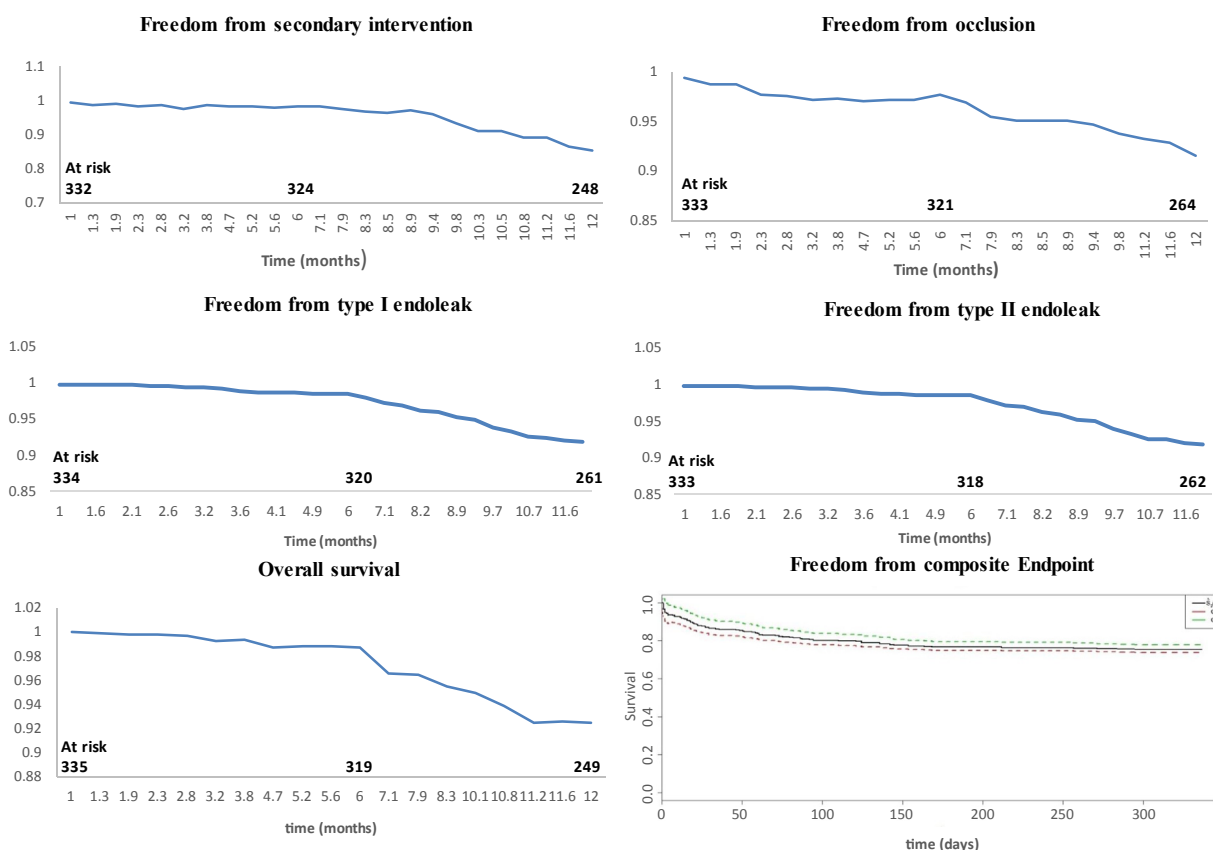
combined with chimney stenting in the left renal artery. Follow-up imaging investigations revealed five type IA endoleaks (1.5%); three were successfully treated using catheter-directed embolization (coils and glue); two were unsuccessfully treated percutaneously and required open conversion because of a significant aneurysmal sac enlargement (>5 mm). Among the type IA endoleaks, one was evident at 1 month and four during subsequent follow-up. One type IB endoleak was identified on 12-month follow-up imaging and was treated by deployment of covered stents to distally extend the Nellix stent lumen (Advanta V12 balloon-expandable covered stent). There were 5 (1.5%) type II endoleaks, 2 observed at 1 month, 2 at 6 months, and 1 at 1 year. Among these, four spontaneously resolved and one remained under surveillance at 1 year.

Open surgical conversion was required in four (1.4%) cases. Reasons for conversion included aortoduodenal fistula (1), endograft infection (1), and significant aneurysm sac enlargement due to type IA endoleak previously unsuccessfully treated through percutaneous access (2). Overall, 18 patients (5.3%) underwent aneurysm-related reinterventions, six performed within 30 days and 12 performed after 30 days. Secondary interventions were carried out for distal embolization (8), stent occlusion (3), stent migration (1), and endoleak (6), including five type IA and one type IB. Freedom from aneurysm-related reintervention was 98.3% at 1-month and 94.7% at 1-year follow-up. Kaplan-Meier estimates of freedom from secondary interventions, Nellix occlusion, and type I and type II endoleaks are shown in the Fig. Of all complications, 1 stent migration, 2 proximal type IA endoleaks, and 1 type IB endoleak occurred in the subset of 40 patients treated outside the IFU. The frequency of endograft-related complications was higher in patients treated outside (10% [4/40]) than inside (6% [18/295]) the IFU.

## DISCUSSION

The IRENE study was designed to analyze the results of EVAS with the Nellix device in a real-world scenario in a wide number of centers with experience in aortic endografting. To the best of our knowledge, this study reports the early results of the widest experience so far collected with this new aortic endovascular device. The preliminary data on EVAS in Italy suggest that this procedure is safe and effective. Nellix technology appears to be widely applicable to patients with infrarenal AAA. The greater number of procedures performed in male patients was related to the higher epidemiologic incidence of aneurysmal disease and not related to a different morphologic applicability of this device between genders.

Most patients in this series were operated on under locoregional anesthesia with a mean operating time of 101 minutes, highlighting the ability of the Nellix system to achieve expeditious aneurysm sac exclusion. This



**Fig.** Kaplan-Meier curves of the secondary intervention, stent occlusion, type I endoleaks, type II endoleaks, and composite end point. The composite end point was defined as the occurrence of distal embolism, stent occlusion, stent migration, type I or type II endoleak, or aneurysm-related reintervention. The discontinuous curves refer to the confidence interval with 95% confidence level. Follow-up data were available for 335 patients at 1 month, 323 at 6 months, and 267 at 1 year. During follow-up, 8 patients and 49 patients were lost at 6 months and 12 months, respectively.

also suggests a shorter fluoroscopy time as confirmed by Antoniou et al,<sup>10</sup> who reported a mean operating time of 121 minutes after EVAS compared with 162 minutes for EVAR, with a resultant shorter fluoroscopy time. Although it is to be confirmed, this finding can represent another added advantage of EVAS to minimize the potential risks of radiation exposure of both patients and operating staff that is related to the increasing use and complexity of endovascular procedures.

A differentiating feature of Nellix is its limited number of different modules that are needed for complete sac sealing of all potential different anatomies. Thus, in the IRENE registry, five different stent graft lengths were used for treatment of 90% of the patients. A practical benefit of this finding is that hospitals would need to store fewer grafts, even in case of uncommon aneurysm anatomy or in emergency settings. In addition, the single diameter of Nellix stents allows effective treatment of a wide range of aortoiliac diameters as demonstrated by 2% of patients in the current study who had an AAA - associated with common iliac artery diameters >35 mm that were treated within the IFU of the Nellix device without embolization of the ipsilateral hypogastric artery.

These data are consistent with those published by Youssef et al,<sup>11</sup> who treated 33 patients with extensive iliac aneurysms with the Nellix endobag to cover the ostium of the hypogastric artery without the need for its preventive embolization using the Nellix-in-Nellix technique if necessary. The mere coverage of the hypogastric artery origin without embolization may reduce the risk of buttock claudication by preserving its collateral branches.

The early unilateral Nellix stent occlusions that occurred in the current series were likely due to the distal landing of the stents in angulated or narrow iliac arteries. Whereas this complication was not attributed to device failure, careful selection of patients, correct evaluation on final angiography, and eventual adjunctive stent placement may avoid such complications.<sup>12</sup> The 2.3% incidence of distal embolization was not associated with particular difficulties encountered in performing the procedures. The most likely cause of distal embolization may have been mobilization of mural thrombus at the time of the dual bag inflation during the original EVAS procedure in patients with particularly fragile sac thrombus. This suggests that greater attention should

be given to device stabilization during polymer filling. The use of other devices may be appropriate to treat aneurysms presenting with a large amount of inhomogeneous mural thrombus.

Landing in tortuous iliac arteries may increase the risk of graft occlusion, especially with a rigid device like the balloon-expandable stent graft of the Nellix device. This may explain the 0.9% incidence of limb occlusion found in the current series and suggests the use of adjunctive iliac stenting if needed. This is consistent with the experience of St. George's Vascular Institute of London, in which adjunctive iliac stenting was required in 59% of the 105 patients undergoing EVAS. These authors stated that when extensive iliac stenting was employed, no graft occlusion occurred.<sup>13</sup>

Unlike conventional endografts, the Nellix system uses polymer-filled endobags that obliterate the aneurysm lumen to achieve a seal, thus allowing aneurysm exclusion and sealing. The polymer-filled endobags of the Nellix device can adapt to an irregular or noncircular aortic neck. The sac-anchoring mechanism of Nellix can also minimize potential longitudinal and lateral movements and subsequently prevent type I Nellix endoleaks, stent migrations, and fractures. This potential seems to be confirmed by the low incidence of stent migrations and type I endoleaks in this study compared with EVAR.

The management of type I endoleaks after Nellix implantation is still debated because there are not yet enough data about their natural history. When endoleak occurs after EVAS, it may fill either the virtual space between the Nellix endobags and the sac or the limited space between the endobags. It follows that the endobags can stem the leakage by reducing the amplitude and trend of pressurization and lowering risk of AAA rupture. As in one of our cases, a type I endoleak can also have an outflow through the inferior mesenteric artery or lumbar arteries, which further reduces the pressurization of the aneurysmal sac and the risk of AAA rupture. Nevertheless, it is intuitive to predict that type I endoleaks after EVAS can cause sac enlargement and ultimately aneurysm rupture. This justifies the choice to treat all type I endoleaks in the current study even without a significant aneurysm enlargement.

Type II endoleaks, which represent approximately half of all endoleaks after EVAR, occur in 10% to 44% of patients. Opinion has been divided about their significance in EVAR because most of these endoleaks are innocuous and transient. However, some may be associated with aneurysm sac enlargement requiring endovascular reintervention or even conversion to open repair. Sac enlargement may accompany persistent type II endoleaks, and enlargement prompts reinterventions and associated incremental health care costs. Even in the absence of sac enlargement, the mere presence of a type II endoleak requires a more rigorous imaging surveillance with additional cost. In addition, Nellix allows

complete sac sealing, thus preventing type II endoleaks originating from the patent collateral branches into the aneurysmal sac, mainly in those cases of AAA without mural thrombus. The 1.5% incidence of type II endoleaks is significantly lower than after EVAR. In addition, most of these endoleaks resolved spontaneously, and the others did not cause sac enlargement. This supports the hypothesis that the Nellix system can reduce the frequency of type II endoleaks and promote their thrombosis when they occur.

The low incidence of any type of endoleak in the current study is consistent with the data from the multicenter experience of the EVAS FORWARD Global Registry, which reported 1-year freedom from type I and type II endoleak of 96% and 98%, respectively.<sup>14</sup> In the current series, there was a higher percentage of type I endoleaks observed in patients treated outside of IFU recommendations. These data suggest that selection of patients and deployment techniques were likely to be associated with some of the clinical failures, principally endoleaks. Those cases with juxtarenal aneurysms with neck lengths ranging from 2 to 5 mm have better results from chimney technique combined with Nellix implantation. In these cases, no endoleaks were detected, even after a triple chimney procedure that is considered at highest risk of the so-called gutter endoleak when it is combined with any other EVAR procedure. However, the preliminary results of the IRENE study cannot prove any possible long-term evolution of Nellix sac sealing.

The current analysis is limited by the short length of follow-up and by the site report of adverse events. The retrospective nature of the collected data may have increased the risk of selection bias. In addition, the study population is not homogeneous and includes juxtarenal aneurysms with use of chimney grafts. This limitation may also represent an additional value of this study as all centers agreed to include all consecutive cases operated on with EVAS in the study period, giving a realistic picture of the use of the Nellix device in a real-world experience. Still, the use of the Nellix device was compliant with the IFU criteria in 88% of the cases, reflecting a tendency to follow the standard indications at most of the centers. Follow-up imaging protocols differed from center to center; therefore, imaging follow-up data were not homogeneous. However, most of the patients had at least one CT or MRI study at 1 year from the procedure, and complications detected by duplex ultrasound were always confirmed by CTA or MRI. Finally, the lack of a centralized and external imaging review may increase the risk of missing complications. Nevertheless, the experience of all participating centers may have mitigated such risk.

## CONCLUSIONS

The preliminary results of this real-world multicenter study demonstrate that EVAS with Nellix for the

management of AAAs appears feasible. This device platform provides acceptable procedure-related mortality with low overall complication and reintervention rates. Definitive conclusions on the value of this novel device await long-term follow-up data.

This study is based on the data collected by all IRENE Group Investigators: Domenico Angiletta, Dimitri Apostoulo, Guido Bellandi, Raffaella Berchiolli, Roberta Ficarrelli, Paolo Frigatti, Giuseppe Galzerano, Luca Garriboli, Rocco Giudice, Raimondo Grossi, Arnaldo Ippoliti, Antonio Maria Jannello, Gaetano La Barbera, Antonio Lauricella, Filippo Maioli, Wassim Mansour, Michele Marconi, Claudio Novali, Gianbattista Parlani, Giovanni Pratesi, Raffaele Pulli, Paolo Scrivere, Carlo Setacci, Francesco Speciale, Francesco Talarico, Maurizio Taurino, Andrea Viazzo

### AUTHOR CONTRIBUTIONS

Conception and design: BG, OM, FV, RS, MF  
Analysis and interpretation: BG, OM, FV  
Data collection: BG, OM, FV, RS, MF  
Writing the article: BG, OM, FV, RS, MF  
Critical revision of the article: BG, OM, FV  
Final approval of the article: BG, OM, FV, RS, MF  
Statistical analysis: BG, OM  
Obtained funding: Not applicable  
Overall responsibility: OM  
BG and OM contributed equally to this article and share first authorship.

### REFERENCES

1. Lederle FA, Freischlag JA, Kyriakides TC, Padberg FT, Matsumura JS, Kohler TR, et al. Outcomes following endovascular vs open repair of abdominal aortic aneurysm, a randomized trial. *JAMA* 2009;302:1535-42.
2. Greenhalgh RM, Brown LC, Powell JT, Thompson SG, Epstein D, Sculpher MJ. Endovascular versus open repair of abdominal aortic aneurysm. *N Engl J Med* 2010;362:1863-71.
3. Prinssen M, Buskens E, de Jong SE, Buth J, Mackaay AJ, van Sambeek MR, et al. Cost-effectiveness of conventional and endovascular repair of abdominal aortic aneurysms: results of a randomized trial. *J Vasc Surg* 2007;46:883-90.
4. Drury D, Michaels JA, Jones L, Ayiku L. Systematic review of recent evidence for the safety and efficacy of elective endovascular repair in the management of infrarenal abdominal aortic aneurysm. *Br J Surg* 2005;92:937-46.
5. Piazza M, Squizzato F, Zavatta M, Menegolo M, Ricotta JJ, Lepidi S, et al. Outcomes of endovascular aneurysm repair with contemporary volume-dependent sac embolization in patients at risk for type II endoleak. *J Vasc Surg* 2016;63:32-8.
6. Piazza M, Frigatti P, Scrivere P, Bonvini S, Noventa F, Ricotta JJ 2nd, et al. Role of aneurysm sac embolization during endovascular aneurysm repair in the prevention of type II endoleak-related complications. *J Vasc Surg* 2013;57:934-41.
7. England A, Torella F, Fisher RK, McWilliams RG. Migration of the Nellix endoprosthesis. *J Vasc Surg* 2016;64:306-12.
8. Carpenter JP, Cuff R, Buckley C, Healey C, Hussain S, Reijnen MM, et al. Results of the Nellix system investigational device exemption pivotal trial for endovascular aneurysm sealing. *J Vasc Surg* 2016;63:23-31.
9. Chaikof EL, Blankensteijn JD, Harris PL, White GH, Zarins CK, Bernhard VM, et al. Ad Hoc Committee for standardized reporting practices in vascular surgery of the Society for Vascular Surgery/American Association for Vascular Surgery. Reporting standards for endovascular aortic aneurysm repair. *J Vasc Surg* 2002;35:1048-60.
10. Antoniou GA, Senior Y, Iazzolino L, England A, McWilliams RG, Fisher RK, et al. Endovascular aneurysm sealing is associated with reduced radiation exposure and procedure time compared with standard endovascular aneurysm repair. *J Endovasc Ther* 2016;23:285-9.
11. Youssef M, Nurzai Z, Zerwes S, Jakob R, Dünschede F, Dorweiler B, et al. Initial experience in the treatment of extensive iliac artery aneurysms with the Nellix aneurysm sealing system. *J Endovasc Ther* 2016;23:290-6.
12. Böckler D, Holden A, Thompson M, Hayes P, Krievins D, de Vries JP, et al. Multicenter Nellix Endovascular Aneurysm Sealing system experience in aneurysm sac sealing. *J Vasc Surg* 2015;62:290-8.
13. Brownrigg JR, de Bruin JL, Rossi L, Karthikesalingam A, Patterson B, Holt PJ, et al. Endovascular aneurysm sealing for infrarenal abdominal aortic aneurysms: 30-day outcomes of 105 patients in a single centre. *Eur J Vasc Endovasc Surg* 2015;50:157-64.
14. Thompson MM, Heyligers JM, Hayes PD, Reijnen MM, Böckler D, Schelzig H, et al. Endovascular aneurysm sealing: early and midterm results from the EVAS FORWARD Global Registry. *J Endovasc Ther* 2016;23:685-92.

Submitted Nov 11, 2016; accepted Sep 18, 2017.