

ISSN : 2231-0762

Vol 9 / Issue 4 / July-August 2019

# Journal of International Society of Preventive & Community Dentistry

Publication of International Society of Preventive and Community Dentistry

# JISPCD

[www.jispcd.org](http://www.jispcd.org)

# Case Report

## Removable Prosthetic Treatment in Oral Pemphigus Vulgaris: Report of Three Cases

Massimo Corsalini<sup>1</sup>, Biagio Rapone<sup>2</sup>, Daniela Di Venere<sup>1</sup>, Massimo Petruzzi<sup>1</sup>

<sup>1</sup>Interdisciplinary Department of Medicine, Section of Dentistry, “Aldo Moro” University of Bari, <sup>2</sup>Department of Basic Medical Sciences, Neurosciences and Sense Organs, “Aldo Moro” University of Bari, Bari, Italy

### ABSTRACT

Pemphigus vulgaris (PV) is the most common clinical phenotype affecting the oral mucosa. Although rare, this vesicular disease may represent a severe complication in the management of edentulous or partially dentate patients because of the priority of care in handling the oral tissues. Analysis of the dental literature indicated a lack of evidence about the possibility of rehabilitating PV patients with removable prosthesis. Our study aimed to evaluate and describe the possibility of rehabilitating three patients who suffered from oral PV with removable prosthesis, although the friction of the prosthesis on oral soft tissues is one of the causes of the development of vesicular lesions which could break, causing oral mucosal pain and erosion. Three patients, referred to the Oral Pathology and Medicine section of the Dental School in Bari University, underwent biopsy, direct and indirect immunofluorescence tests, and enzyme-linked immunosorbent assay to confirm the diagnosis of oral PV. For each patient, a systemic corticosteroid therapy was planned. After the clinical remission of the PV signs, the patients were planned for an oral rehabilitation with removable prosthesis. As long as certain precautions are followed, patients with PV in a phase of clinical remission, induced by treatment, can be treated successfully with removable prosthesis. Although some authors have previously cautioned about the use of removable prosthesis for the treatment of patients with oral pemphigus, it is our view that, if patients follow the rigorous and periodic follow-up as discussed above, along with a corticosteroid immunosuppressive therapy, they may not show any deterioration of their clinical symptoms.

**KEYWORDS:** *Pemphigus vulgaris, prosthodontic rehabilitation, removable prosthesis, vesicular -bullous disease*

Received: 03-12-18.  
Accepted: 17-04-19.  
Published: 19-06-19.

### INTRODUCTION

Pemphigus is a serious autoimmune disease characterized by acantholysis (i.e., the loss of the intercellular connections between epidermal cells) and subsequent blistering of the skin and oral mucosa, mediated by autoantibodies directed against intercellular antigens such as desmoglein-3 and desmoglein-1.<sup>[1]</sup> There are three immunologic forms of pemphigus, namely, pemphigus foliaceus, pemphigus vulgaris (PV), and paraneoplastic pemphigus. PV, the most common subset of pemphigus diseases, accounts for 70% of the total cases.<sup>[2]</sup> The disease is rare with potentially fatal consequences and has a reported incidence of 0.1–0.5 cases per 100,000 individuals worldwide per

year.<sup>[2]</sup> PV is seen worldwide with a predilection of Mediterranean people and Ashkenazi Jews. It is slightly predominant in women and primarily manifests in adults during the fifth and sixth decades of life.<sup>[2]</sup>

Oral mucosa is most often the initial site and, in many cases, the only site of disease penetration. PV is an antibody-mediated disorder characterized by autoantibodies directed against proteins of the desmosome (desmogleins 1 and 3), leading histologically

**Address for correspondence:** Dr. Biagio Rapone, Piazza Giulio Cesare 10, Bari 70121, Italy. E-mail: biagiorapone79@gmail.com

This is an open access journal, and articles are distributed under the terms of the Creative Commons Attribution-NonCommercial-ShareAlike 4.0 License, which allows others to remix, tweak, and build upon the work non-commercially, as long as appropriate credit is given and the new creations are licensed under the identical terms.

For reprints contact: reprints@medknow.com

**How to cite this article:** Corsalini M, Rapone B, Di Venere D, Petruzzi M. Removable prosthetic treatment in oral pemphigus vulgaris: Report of three cases. J Int Soc Prevent Communit Dent 2019;9:423-6.

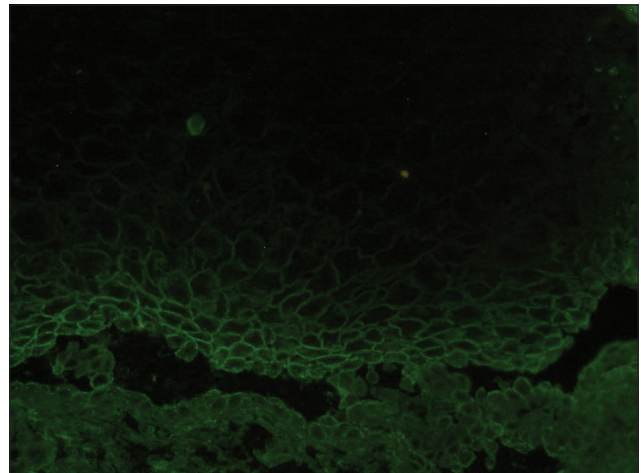
Access this article online	
Quick Response Code: 	Website: <a href="http://www.jispcd.org">www.jispcd.org</a>
	DOI: <a href="https://doi.org/10.4103/jispcd.JISPCD_421_18">10.4103/jispcd.JISPCD_421_18</a>

to intraepithelial cleavage and clinically to vesicles and erosions on the epithelium of the mucous membranes and the skin. Oral signs are characterized by erosions or flaccid bullae, which are extremely fragile when subjected to the slightest mechanical irritation.<sup>[3]</sup> Any site in the mouth may be involved, but the soft palate and buccal, gingival, and lower-lip mucosae usually predominate. Gingival involvement may manifest as desquamative gingivitis.<sup>[4]</sup> Affected oral tissues are highly friable with a tendency to bleed and shear when subjected to minor trauma. Patients affected by these chronic, painful ulcers often complain of discomfort while eating spicy or sour foods and performing daily oral functions, including routine oral hygiene.<sup>[4]</sup> Because development of oral lesions may precede skin lesions, it is not common for a patient having this disease to seek care first from a dentist. The clinical pathognomonic sign of this disease is the Nikolsky's sign: gentle lateral pressure applied to an area adjacent to the affected site forms a blister. The definitive diagnosis of PV cannot be based solely on clinical examination, as several other oral vesiculobullous and ulcerative lesions have a similar appearance such as lichen planus, pemphigoid, and erythema multiforme.<sup>[4-7]</sup> An incisional, perilesional biopsy containing intact epithelium is required for a definitive diagnosis. Deposits of autoantibodies are evidenced by direct immunofluorescence. Indirect immunofluorescence and enzyme-linked immunosorbent assay (ELISA) quantify the circulating amount of autoantibodies.<sup>[5]</sup> The main treatment consists of administering corticosteroid and immunosuppressive drugs<sup>[5]</sup> and in case of resistance, rituximab is the preferred choice. Patients with oral PV require prosthodontic treatment with removable prosthesis. Vesicular-bullous disease may represent a severe complication in the management of patients, for necessary care in handling the oral tissues.<sup>[8-10]</sup>

Our study aimed to evaluate and describe the possibility of rehabilitating three patients who suffered from oral PV with a removable prosthesis, although the friction of the same prosthesis on soft tissues is one of the causes of the development of bullous lesions which could break, causing oral mucosal pain and erosion.

### CASE SERIES

Three patients (2 males and 1 female), treated at the Oral Pathology and Medicine Section of the Dental School of the University of Bari, underwent biopsy, direct immunofluorescence [Figure 1], and ELISA to confirm the diagnosis of PV<sup>[11]</sup> [Figure 2]. Age of the three patients at the first presentation was 64, 62, and 60 years; one of them was also affected by lingual Kaposi's sarcoma. Initial treatment consisted of oral



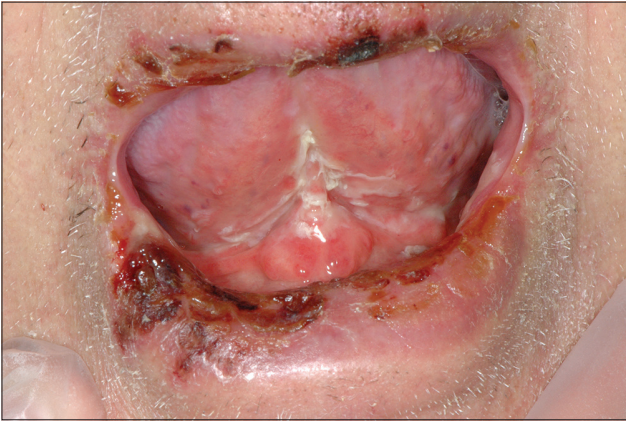
**Figure 1:** Direct immunofluorescence test in pemphigus vulgaris: There is evidence of intraepithelial cleavage

prednisone (1 mg/kg die), the dosage of which was decreased gradually according to clinical improvement. After the oral lesion's remission, during the minimal dosage maintenance phase, we took a primary impression with an irreversible hydrocolloid impression material, by using a complete tray; we used dental plaster to obtain a primary cast, and we realized individual trays using acrylic resin material; after border the molding, we took the final impressions. The baseplates were prepared for the realization of a removable acrylic resin prosthesis in the upper and lower jaws. The patients were treated with total removable upper and lower acrylic prostheses. The treatment of all the three patients took place between February and July 2011. After treatment, they underwent periodic quarterly checks to assess any complications and/or worsening on the diseased oral mucosa of the foreign body represented by the removable prosthesis. The follow-up was 87 months on an average. This study was conducted in accordance to the principles of the Declaration of Helsinki, and all the patients signed an informed consent.

### DISCUSSION

The typical clinical feature of PV consists in flaccid, thin-walled vesicles and bullae that usually arise on normal skin or mucosa.<sup>[4]</sup> The lesions in the oral cavity are superficial and rupture easily, leaving painful, coalesced ulcers with ragged borders. It is difficult for patients to perform adequate oral home care because of pain and discomfort. With early diagnosis and aggressive treatment, between 50% and 80% patients with PV achieve complete remission.<sup>[12]</sup>

The medical management of PV involves topical, intralesional, or systemic use of steroids and other immunosuppressive agents. Systemic corticosteroids are



**Figure 2:** Clinical presentation in one of the patients of the study (there are only oral lesions)

the first line of therapy for the treatment of PV. In case of resistance, rituximab is the preferred choice.<sup>[6]</sup>

The lack of anomalies in the oral mucosa affected by PV during the 7-year follow-up is reassuring.

Patients with a history of pemphigus must be recalled periodically to examine the prosthesis and the oral mucosa. Some authors suggest to use a prosthesis with soft denture liner with good resilience, color stability, chemical resistance, good bonding to the denture, low water sorption, and resistance to dimensional change.<sup>[8]</sup> We paid great attention cutting the acrylic resin dentures, by using rubber wheels on high-speed angle handpieces, as opposed to carbide burs.<sup>[8]</sup> It is crucial to obtain a very smooth, highly polished denture, to avoid any mechanical irritation of the mucosa. Careful attention to occlusal harmony and smooth, rounded borders which are molded precisely are vital to successful treatment. Gentle handling of the oral mucosa is necessary so as not to cause further injury. The use of soft liner materials may be recommended as a temporary solution when bullae or other lesions are present.<sup>[8]</sup>

Therefore, according to some authors in the literature, wearing tissue-borne removable prosthesis can be difficult with PV lesions; meanwhile, fixed prosthesis is preferred wherever possible and great care should be taken to create optimal gingival contours to prevent inflammation and facilitate hygiene.<sup>[13-16]</sup>

In our opinion, if patients follow rigorous and periodic follow-up as discussed above, along with a corticosteroid immunosuppressive therapy, they may not show any deterioration of their clinical symptoms in wearing removable prosthesis.

Patients with PV should receive regular and frequent dental examinations (every 2–3 months) until extended intervals can be justified. Therefore, the presented

patient has been called for follow-up recalls every 3 months.

The most important aspect of PV is its early recognition, diagnosis, and treatment. The dental clinician and health-care team play a critical role in the quality of life for these patients. It is essential to monitor the patient in collaboration with a dermatologist. Although the dental problems in PV can be challenging, a strategic and comprehensive dental planning will have positive outcomes. Patients have tolerated their removable prosthesis well by using it comfortably since the beginning of rehabilitation procedures.

## CONCLUSIONS

PV typically runs a chronic course, causing blisters, erosions, and ulcers on the mucosa and skin. Oral problems such as blister formation with minimal trauma are usually encountered in patients with PV. Ill-fitting dentures can cause vesiculobullous and ulcerative lesions.

In literature, several researchers revealed that the use of implant-supported prosthesis is the better choice in patients affected by PV.<sup>[17,18]</sup> According to the current experience, caution must be exercised about the use of removable prosthesis in these patients. In our experience, if patients follow rigorous and periodic follow-up as discussed above, along with a corticosteroid immunosuppressive therapy, they may not show any deterioration of their clinical symptoms by using removable acrylic resin prosthesis in the upper and lower jaws.

The improvement of the methods of diagnosis and prosthetic treatment of patients with acantholytic pemphigus using removable dentures is promising.

## DECLARATION OF PATIENT CONSENT

The authors certify that they have obtained all appropriate patient consent forms. In the form, the patients have given their consent for their images and other clinical information to be reported in the journal. The patients understand that their names and initials will not be published and due efforts will be made to conceal their identity, but anonymity cannot be guaranteed.

## ACKNOWLEDGMENTS

The authors thank Dr. Marilina Tampoia for Figure 1 (direct immunofluorescence test).

## FINANCIAL SUPPORT AND SPONSORSHIP

Nil.

## CONFLICTS OF INTEREST

There are no conflicts of interest.



## REFERENCES

- Kridin K. Pemphigus group: Overview, epidemiology, mortality, and comorbidities. *Immunol Res* 2018;66:255-70.
- Silva SC, Nasser R, Payne AS, Stoopler ET. Pemphigus vulgaris. *J Emerg Med* 2019;56:102-4.
- Vodo D, Sarig O, Sprecher E. The genetics of pemphigus vulgaris. *Front Med (Lausanne)* 2018;5:226.
- Shamim T, Varghese VI, Shameena PM, Sudha S. Pemphigus vulgaris in oral cavity: Clinical analysis of 71 cases. *Med Oral Patol Oral Cir Bucal* 2008;13:E622-6.
- Buonavoglia A, Leone P, Dammacco R, Di Lernia G, Petruzzi M, Bonamonte D, *et al.* Pemphigus and mucous membrane pemphigoid: An update from diagnosis to therapy. *Autoimmun Rev* 2019;18:349-58.
- Robinson JC, Lozada-Nur F, Frieden I. Oral pemphigus vulgaris: A review of the literature and a report on the management of 12 cases. *Oral Surg Oral Med Oral Pathol Oral Radiol Endod* 1997;84:349-55.
- Banerjee I, Bhowmik B, Maji A, Sinha R. Pemphigus vulgaris – A report of three cases and review of literature. *J Family Med Prim Care* 2018;7:1109-12.
- Tolentino AT. Prosthetic management of patients with pemphigus vulgaris. *J Prosthet Dent* 1977;38:254-60.
- Henyk B, Rozhko M. Study of the state of denture-supporting tissues in patients with pemphigus vulgaris. *Arch Clin Med* 2017;23:1-4.
- Corsalini M, Rapone B, Grassi FR, Di Venere D. A study on oral rehabilitation in stroke patients: Analysis of a group of 33 patients. *Gerodontology* 2010;27:178-82.
- Van AT, Nguyen TV, Huu SN, Thi LP, Minh PP, Huu N, *et al.* Improving treatment outcome of pemphigus vulgaris on Vietnamese patients by using desmoglein Elisa test. *Open Access Maced J Med Sci* 2019;7:195-7.
- González-Serrano J, Paredes VM, López-Pintor RM, de Arriba L, Hernández G. Successful treatment of oral pemphigus vulgaris in an insulin-dependant geriatric patient. *Gerodontology* 2016;33:569-72.
- Rapone B, Nardi GM, Di Venere D, Pettini F, Grassi FR, Corsalini M. Oral hygiene in patients with oral cancer undergoing chemotherapy and/or radiotherapy after prosthesis rehabilitation: Protocol proposal. *Oral Implantol (Rome)* 2016;9:90-7.
- Di Venere D, Pettini F, Nardi GM, Laforgia A, Stefanachi G, Notaro V, *et al.* Correlation between parodontal indexes and orthodontic retainers: Prospective study in a group of 16 patients. *Oral Implantol (Rome)* 2017;10:78-86.
- Quaglia E, Moscufo L, Corsalini M, Coscia D, Sportelli P, Cantatore F, *et al.* Polyamide vs. silk sutures in the healing of postextraction sockets: A split mouth study. *Oral Implantol* 2018;11:115-20.
- Grassi FR, Rapone B, Scarano Catanzaro F, Corsalini M, Kalemaj Z. Effectiveness of computer-assisted anesthetic delivery system (sta™) in dental implant surgery: A prospective study. *Oral Implantol (Rome)* 2017;10:381-9.
- Strietzel FP, Schmidt-Westhausen AM, Neumann K, Reichart PA, Jackowski J. Implants in patients with oral manifestations of autoimmune or mucocutaneous diseases – A systematic review. *Med Oral Patol Oral Cir Bucal* 2019;24:e217-e230.
- Altin N, Ergun S, Katz J, Sancakli E, Koray M, Tanyeri H. Implant-supported oral rehabilitation of a patient with pemphigus vulgaris: A clinical report. *J Prosthodont* 2013;22:581-6.