

HELMINTHOLOGIA, 53, 3: 276 - 280, 2016

## Case Report

***Crenosoma vulpis* infection in a four-month old puppy**B. MATOS<sup>1</sup>, V. COLELLA<sup>2</sup>, A. M. ALHO<sup>1\*</sup>, D. OTRANTO<sup>2</sup>, R. DOYLE<sup>3</sup>, L. MADEIRA DE CARVALHO<sup>1</sup><sup>1</sup>CIISA, Faculty of Veterinary Medicine, ULisboa, Portugal, \*E-mail: [margaridaalho@fmv.ulisboa.pt](mailto:margaridaalho@fmv.ulisboa.pt); <sup>2</sup>Department of Veterinary Medicine, University of Bari, Italy; <sup>3</sup>The Wylie Veterinary Centre, Upminster, Essex, UK

## Article info

Received May 2, 2016  
Accepted June 8, 2016

## Summary

Here we report the case of a diagnostic and treatment challenge in a four-month old dog from England, presented with one-month history of unproductive cough. Antigen blood test for *Angiostrongylus vasorum* infection was negative. Thoracic radiographs revealed a generalised bronchointerstitial pattern and bronchoscopy showed moving nematodes in the mucus of the bronchial wall. Additionally, Baermann technique revealed a high burden of larvae per gram of faeces. Morphological and molecular analyses confirmed that they were first stage larvae of *Crenosoma vulpis*. The infection was firstly treated with a spot-on solution containing 10% imidacloprid + 2.5% moxidectin, but the dog was still positive after 13 days. Therefore, a seven-day course of fenbendazole was prescribed. This represents one of the youngest dogs ever reported naturally infected by *C. vulpis*. The scant number of reported cases of crenosomosis has led practitioners to consider it as a rare parasitic disease in dogs, delaying a correct and targeted on-time diagnosis. Further studies are needed to perceive the real prevalence of this lungworm and to understand if it is a rare parasite or just rarely diagnosed.

**Keywords:** *Crenosoma vulpis*; puppy; Baermann technique; morphologic identification; molecular identification; England

## Introduction

Nematodes parasitising the respiratory tract of mammals, commonly referred as lungworms, are increasingly reported in Europe as a cause of infection in animals and humans (Traversa *et al.*, 2010). Among these nematodes, *Crenosoma vulpis*, also known as the fox lungworm, is a metastrongylid that affects the bronchi, bronchioles and trachea of wild and domestic canids (Bihl & Conboy, 1999). This parasite is endemic in the red fox population in Europe (Sréter *et al.*, 2003; Saeed *et al.*, 2006), including Great Britain (Taylor, 2015), and it was reported for the first time in dogs in 1992 in the UK (Cobb & Fisher, 1992). Adult nematodes inhabit the lungs of the definitive hosts and release larvated eggs that hatch to first-stage larvae (L1) and are coughed up and swallowed.

L1 are passed in the faeces (Anderson, 1992) and once in the environment, infect gastropod intermediate hosts, developing into infective third-stage larvae (L3) in approximately 17 days (Wetzel & Mueller, 1935). In the common garden snail *Cornu aspersum* (syn *Helix aspersa*) for example, L3 have been detected after 10 days post-infection (Colella *et al.*, 2016). Caniids acquire the infection via the ingestion of infected terrestrial snails or slugs (Stockdale & Hülland, 1970), however alternative routes of infection for the definitive and intermediate hosts have also been reported for metastrongyles infecting cats and dogs (Barçante *et al.*, 2003; Colella *et al.*, 2015; Giannelli *et al.*, 2015).

Canine crenosomosis is typically characterised by bronchitis with a dry, unproductive cough that can be elicited by tracheal palpation, with occasional gagging (Cobb & Fisher, 1992). High parasite

burdens may induce mucoid or mucopurulent discharge from the airways along with a chronic and productive cough, which could detrimentally affect dogs' quality of life (Conboy, 2009). In most cases, mild to moderate bronchial patterns with a diffuse interstitial component (more evident at the diaphragmatic lobes) is observed on radiographs (Unterer *et al.*, 2002). Indeed, the diagnosis of crenosomosis is challenging as the clinical presentation closely mimics other respiratory diseases, characterised by minor to mild respiratory signs, such as bronchitis with mucopurulent discharge and chronic cough (Conboy, 2009). Occasionally, small animal practitioners fail to consider *C. vulpis* infection in dogs suffering from chronic cough, misdiagnosing and treating the condition as an allergic respiratory disease (Traversa *et al.*, 2010). In addition, crenosomosis frequently presents with no specific radiographic or haematological abnormalities (Traversa *et al.*, 2010), making critical a timely and reliable diagnosis, based on correct procedures and methodologies (Foster *et al.*, 2004). Here we report the clinical presentation and diagnostic approach carried out in a puppy from England.

### Material and Methods

A four-month old, entire female, wirehaired Dachshund was referred to The Wylie Veterinary Centre, Upminster, Essex UK, in November 2015 with a one-month history of unproductive coughing, refractory to non-steroidal anti-inflammatory drugs (NSAIDs) and several broad spectrum antibiotic therapies (including cefo-

vecin, metronidazole, amoxicillin and clavulanic acid). The patient lived with another dog in a semi-rural area in Essex (UK). In mid-October, she was core vaccinated against canine distemper, hepatitis, parvovirus, parainfluenza and leptospirosis and treated with a topical parasiticide containing 10 % imidacloprid + 2.5 % moxidectin.

After a physical examination, blood was collected from the jugular vein for a complete blood count (CBC), serum chemistry profile and an antigen blood test specific for the detection of *Angiostrongylus vasorum* infection (IDEXX Angio Detect™ Test).

In order to assess the lungs, heart and chest wall, the dog was premedicated with acepromazine and butorphanol, and general anaesthesia was induced with propofol and maintained with isoflurane after tracheal intubation. Lateral and dorso-ventral radiographic projections of the thorax were taken at full inspiration. A flexible bronchoscopy was performed, as well as, a bronchoalveolar lavage (BAL) with 15 mL of warm sterile saline instilled and aspirated five seconds later. The BAL was stored in sterile tubes for cytological evaluation.

A qualitative floatation analysis with a sucrose solution, a sedimentation test and a Baermann technique were performed with fresh faecal samples collected through an enema. Larvae were stored in 70 % ethanol and sent to the Parasitology Unit at the Faculty of Veterinary Medicine, ULisboa (Portugal) and to the Department of Veterinary Medicine, University of Bari (Italy) for morphological and molecular parasitological identification. In order to perform molecular characterization, larvae were isolated from the sus-

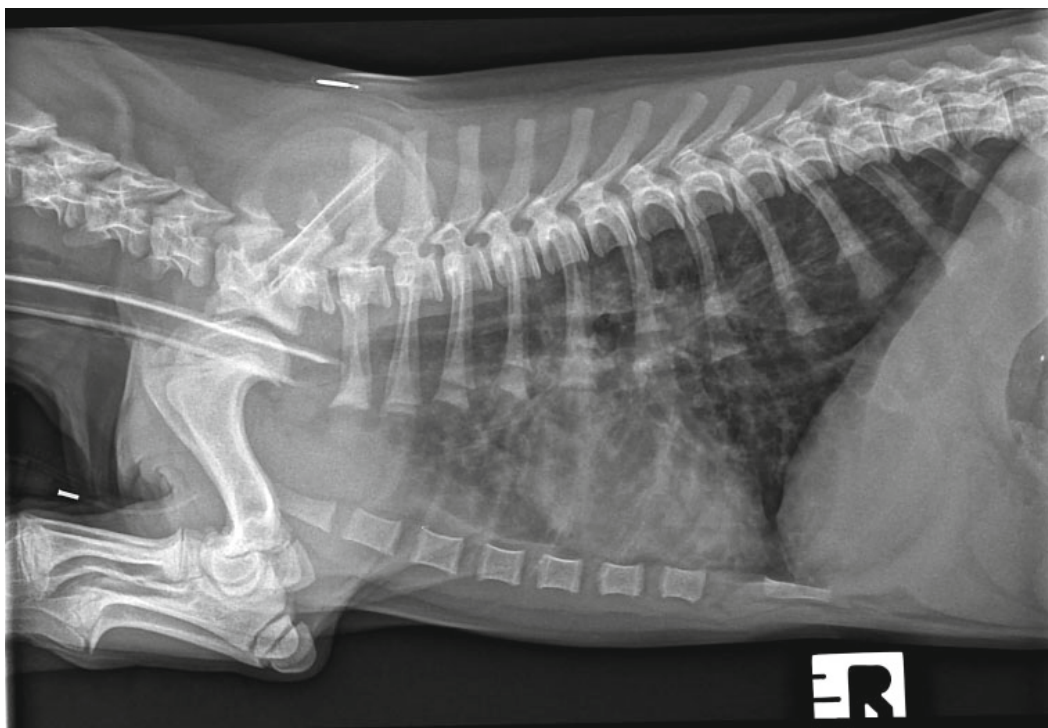


Fig. 1. Right lateral thoracic radiograph of the dog showing thickening of the bronchial walls into the periphery of the lung fields and a diffuse increase in pulmonary opacity throughout the lungs

pension using a 10 µl micropipette and stored in phosphate buffer saline (PBS) solution. Genomic DNA was extracted using a commercial kit (DNeasy Blood & Tissue Kit, Qiagen, GmbH, Hilden, Germany), in accordance with the manufacturer's instructions, and partial mitochondrial 12S rRNA (~330 bp) and nuclear 18S rRNA (~1700 bp) genes were amplified as previously described (Latrofa *et al.*, 2015).

## Results

On physical examination the dog was bright, alert and responsive with a body condition score of 3/9. Her inspiratory effort was increased and an unproductive cough with terminal retch was noticed during the consultation, although there was no response on tracheal pinch. On thoracic auscultation, normal respiratory sounds were slightly exaggerated over the entire lung field, although there were no adventitious lung sounds. Her heart sounds were normal with synchronous femoral pulses. Her rectal temperature was within normal limits and no enlarged lymph nodes were noticeable. CBC revealed eosinophilia, with no other abnormalities and serum chemistry was unremarkable. The antigen blood test specific for the detection of *A. vasorum* (IDEXX Angio Detect™ Test) revealed a negative result.

Lateral and dorso-ventral radiographic projections of the thorax were taken at full inspiration, revealing a normal cardiac silhouette, enhancement and thickening of the bronchial walls spreading into the periphery of the lung fields, and a diffuse increase in pulmonary opacity throughout the lungs (Fig. 1). Flexible bronchoscopy was performed and visualization of the trachea and bronchioles revealed a moderate quantity of mucous and absence of foreign bodies, nodules or masses. After inspection of all primary and secondary bronchioles, a bronchoalveolar lavage (BAL) was performed. During the instillation, a single motile white worm was observed on the mucus of the bronchial wall and cytological evaluation of the BAL showed the presence of a non-septic exudate with marked eosinophilic infiltration.

After the visualization of the nematode in the respiratory tract, an enema was performed to collect fresh faecal samples. Qualitative floatation analysis and sedimentation test were negative. The sediment collected from the Baermann apparatus revealed the presence of several motile larvae under light microscopy. A quantitative Baermann was performed, revealing 6066 larvae per gram of faeces (LPG). Several filiform C-shaped larvae were visualized, 260 – 290 µm long and 12 – 14 µm wide, consistent with *C. vulpis* L1 (Fig. 2). Regarding the molecular identification, the 12S rDNA sequences obtained from the collected larvae (accession no.



Fig. 2. *Crenosoma vulpis* first stage larvae detected at the Baermann technique, 40x magnification. Note the filiform C-shaped larvae with conical tail, consistent with *C. vulpis*



KR920039) revealed 100 % identity to the nucleotide sequences of *C. vulpis* available in GenBank®.

The patient was treated with a second administration of 10 % imidacloprid + 2.5 % moxidectin spot-on. However, at a re-examination 13 days after the spot-on application, L1 of *C. vulpis* were still present in the dog faeces. Therefore, an alternative approach using fenbendazole (50 mg/kg, PO, q 24 hours) was prescribed for seven days. One month later, thoracic radiographs and Baermann analysis, using faeces from three successive days were performed. Radiographs showed a normal lung pattern, no first stage larvae were detected in faeces and the cough resolved after the fourth day of treatment.

## Discussion

Here we report a case of natural infection by *C. vulpis* in a very young puppy, one of the earliest cases of infection ever reported for this lungworm. Since the first report of this nematode in a domestic dog from the UK (Cobb & Fisher, 1992), only sporadic cases have been diagnosed in the last decade, including reports from Ireland (Reilly *et al.*, 2000), Switzerland (Unterer *et al.*, 2002), Germany (Barutzki & Schaper, 2003), Italy (Rinaldi *et al.*, 2007) and Belgium (Caron *et al.*, 2014). The scant number of reported cases has led practitioners to consider crenosomosis as a rare parasitic disease in dogs. *C. vulpis* is recognized as the primary cause of pulmonary infections in foxes (Magi *et al.*, 2009), with 10.8 % of foxes scoring positive for this parasite in Great Britain (Taylor *et al.*, 2015). This high prevalence in foxes may suggest that this animal species may act as a reservoir host for the infection of dogs living in the UK and that it may also be prevalent in dogs despite the low evidence in the UK (Cobb & Fisher, 1992; Reilly *et al.*, 2000). Indeed, temperature and the high relative humidity in this country represent optimal conditions for the lifecycle of this lungworm (Ferdushy and Hasan 2010). In addition, the free-roaming behaviour of foxes has been considered as one of the major drivers for the geographical dispersal of lungworms (Otranto *et al.*, 2015). Further studies are needed to investigate long term effects and potential complications when other concomitant infections are present. Clinicians should be mindful that *C. vulpis* can cause chronic respiratory signs refractory to several first line treatments, leading to irresponsible use of medicaments and client frustration due to lack of resolution of troublesome symptoms. Besides, towards a negative *A. vasorum* antigen blood test and the presence of respiratory signs, other techniques must be performed to exclude other lungworm infections in dogs. In fact, *C. vulpis* cannot be easily diagnosed with standard faecal flotation techniques commonly carried out at most veterinary clinics, but by using the Baermann technique, a coprological test considered the gold standard for the diagnosis of lungworm infections (Conboy, 2009). This is a simple, non-invasive, inexpensive diagnostic tool (Koch & Willeßen, 2009), which allows lungworm detection and identification based on the morphological characteristics of L1 (McGarry & Morgan,

2009; Colella *et al.*, 2016). Multiple faecal examinations should be performed to improve detection rates and avoid false negatives (Foster *et al.*, 2004; Koch & Willeßen, 2009). However, this technique is not commonly used in current practice, particularly in patients with respiratory signs, prior to a presumptive diagnosis of allergic respiratory disease and the administration of long-term corticosteroid therapy (Bihl & Conboy, 1999). Considering the time before the patency period (i.e. 18 – 21 days), this dog acquired the infection in a very early age, at approximately three-months old, and the cases available in the literature exclusively report natural infections in dogs older than one year (Reilly *et al.*, 2000; Rinaldi *et al.*, 2007; Caron *et al.*, 2014). Hence, canine crenosomosis should also be taken into account in very young patients suffering from respiratory disease.

Successful treatments in naturally infected dogs have been reported with the use of febantel, fenbendazole, ivermectin, milbemycin oxime (Bihl & Conboy, 1999) and moxidectin (Colella *et al.*, 2016). In two studies, milbemycin oxime (Conboy *et al.*, 2013) and moxidectin (Conboy *et al.*, 2009) showed 98.7 and 100 % efficacy in the treatment of experimentally infected dogs, respectively. In the case here reported, the treatment with a spot-on solution containing 10 % imidacloprid + 2.5 % moxidectin was unsuccessful in treating *C. vulpis* infection. However, this dog had a larger larval shedding (i.e. 6066 LPG) than those of experimentally infected dogs (i.e. 0 – 152.5 LPG) (Conboy *et al.*, 2009). This could explain why contrarily to the efficacy showed 7 days after the administration of the same spot-on association in experimentally infected animals (Conboy *et al.*, 2009), the dog herein examined was still positive at the re-examination after 13 days. Following the second treatment with fenbendazole on day 13, the dog cured *C. vulpis* infection on day 43, though it was not possible to determine which of the two treatments was efficacious.

Baermann tests should be performed more routinely to perceive the real prevalence of this lungworm and to understand if it is a rare parasite or just rarely diagnosed. Besides, practitioners should include crenosomosis in the differential diagnosis of respiratory diseases in dogs, particularly in areas where foxes are present, and should foster targeted preventive therapy against this lungworm infection.

## Acknowledgement

To The Wylie Veterinary Centre team, Upminster, Essex UK for their invaluable help, to Angela Doyle for their precious help in English review and to CIISA, Faculty of Veterinary Medicine, ULisboa, Portugal, reference UID/CVT/00276/2013. Ana Margarida Alho holds a PhD fellowship reference SFRH/BD/85427/2012.

## References

ANDERSON, R.C. (1992): *Nematode parasites of vertebrates, their development and transmission*. Oxon: CAB International.

- BARÇANTE, T.A., BARÇANTE, J.M., DIAS, S.R., LIMA W DOS, S. (2003): *Angiostrongylus vasorum* (Baillet, 1866) Kamensky, 1905: emergence of third-stage larvae from infected *Biomphalaria glabrata* snails. *Parasitol. Res.*, 91: 471 – 475
- BARUTZKI, D., SCHAPER, R. (2003): Endoparasites in dogs and cats in Germany 1999 – 2002. *Parasitol. Res.*, 90: 148 – 150
- BIHR, T., CONBOY, G.A. (1999): Lungworm (*Crenosoma vulpis*) infection in dogs on Prince Edward Island. *Can. Vet. J.*, 40: 555 – 559
- CARON, Y., MERVEILLE, A.C., LOSSON, B., BILLEN, F. (2014): *Crenosoma vulpis* infection in two young dogs in Belgium. *Vet. Rec. Case Report*, 2: e000098
- COBB, M.A., FISHER, M.A. (1992): *Crenosoma vulpis* infection in a dog. *Vet. Rec.*, 130: 452
- COLELLA, V., GIANNELLI, A., BRIANTI, E., RAMOS, R.A., CANTACESSI, C., DANTAS-TORRES, F., OTRANTO, D. (2015): Feline lungworms unlock a novel mode of parasite transmission. *Sci. Rep.*, 5: 13105
- COLELLA, V., MUTAFCHIEV, Y., CAVALERA, M.A., GIANNELLI, A., LIA, R.P., DANTAS-TORRES, F., OTRANTO, D. (2016): Development of *Crenosoma vulpis* in the common garden snail *Cornu aspersum*: implications for epidemiological studies. *Parasit. Vectors.*, 9(1): 208
- CONBOY, G. (2009): Helminth parasites of the canine and feline respiratory tract. *Vet. Clin. North. Am. Small Anim. Pract.*, 39: 1109 – 1126
- CONBOY, G., BOURQUE, A., MILLER, L., SEEWALD, W., SCHENKER, R. (2013): Efficacy of Milbemax (milbemycin oxime + praziquantel) in the treatment of dogs experimentally infected with *Crenosoma vulpis*. *Vet. Parasitol.*, 198: 319 – 324
- CONBOY, G., HARE, J., CHARLES, S., SETTJE, T., HEINE, J. (2009). Efficacy of a single topical application of Advantage Multi (=Advocate) Topical Solution (10 % imidocloprid + 2.5 % moxidectin) in the treatment of dogs experimentally infected with *Crenosoma vulpis*. *Parasitol. Res.*, 105: 49 – 54
- FERDUSHY, T., HASAN, M.T. (2010): *Angiostrongylus vasorum*: the 'French heartworm'. *Parasitol. Res.*, 107: 765 – 771
- FOSTER, S.F., MARTIN, P., BRADDOCK, J.A., MALIK, R. (2004): A retrospective analysis of feline bronchoalveolar lavage cytology and microbiology (1995 – 2000). *J. Fel. Med. Surg.*, 6: 189 – 198
- GIANNELLI, A., COLELLA, V., ABRAMO, F., NASCIMENTO RAMOS, R.A., FALSONE, L., BRIANTI, E., VARCASIA, A., DANTAS-TORRES, F., KNAUS, M., FOX, M.T., OTRANTO, D. (2015): Release of lungworm larvae from snails in the environment: potential for alternative transmission pathways. *PLoS Negl. Trop. Dis.*, 9, e0003722
- KOCH, J., WILLESEN, J.L. (2009): Canine pulmonary angiostrongylosis: An update. *Vet. J.*, 179: 348 – 359
- LATROFA, M.S., LIA, R.P., GIANNELLI, A., COLELLA, V., SANTORO, M., D'ALESSIO, N., CAMPBELL, B.E., PARISI, A., DANTAS-TORRES, F., MUTAFCHIEV, Y., VENEZIANO, V., OTRANTO, D. (2015): *Crenosoma vulpis* in wild and domestic carnivores from Italy: a morphological and molecular study. *Parasitol. Res.*, 114: 3611 – 3617
- MAGI, M., MACCHIONI, F., DELL'OMODARME, M., PRATI, M.C., CALDERINI, P., GABRIELLI, S., IORI, A., CANCRINI, G. (2009): Endoparasites of red fox (*Vulpes vulpes*) in central Italy. *J. Wildl. Dis.*, 45: 881 – 885
- MCGARRY, J.W., MORGAN, E.R. (2009): Identification of first-stage larvae of metastrongyles from dogs. *Vet. Rec.*, 165: 258 – 261
- OTRANTO, D., CANTACESSI, C., DANTAS-TORRES, F., BRIANTI, E., PFEFFER, M., GENCHI, C., GUBERTI, V., CAPELLI, G., DEPLAZES, P. (2015): The role of wild canids and felids in spreading parasites to cats and dogs in Europe. Part II: Helminths and arthropods. *Vet. Parasitol.*, 213: 24 – 37
- REILLY, G.A., MCGARRY, J.W., MARTIN, M., BELFORD, C. (2000): *Crenosoma vulpis*, the fox lungworm, in a dog in Ireland. *Vet. Rec.*, 146: 764 – 765
- RINALDI, L., CALABRIA, G., CARBONE, S., CARRELA, A., CRINGOLI, G. (2007): *Crenosoma vulpis* in dog: first case report in Italy and use of the FLOTAC technique for copromicroscopic diagnosis. *Parasitol. Res.*, 101: 1681 – 1684
- SAEED, I., MADDOX-HYTTEL, C., MONRAD, J., KAPEL, C.M. (2006): Helminths of red foxes (*Vulpes vulpes*) in Denmark. *Vet. Parasitol.*, 139: 168 – 179
- SRÉTER, T., SZÉLL, Z., MARUCCI, G., POZIO, E., VARGA, I. (2003): Extraintestinal nematode infections of red foxes (*Vulpes vulpes*) in Hungary. *Vet. Parasitol.*, 115: 329 – 334
- STOCKDALE, P.H.G., HULLAND, T.J. (1970): The pathogenesis, route of migration, and development of *Crenosoma vulpis* in a dog. *Pathol. Vet.*, 7, 28 – 42
- TAYLOR, C.S., GARCIA GATO, R., LEARMOUNT, J., AZIZ, N.A., MONTGOMERY, C., ROSE, H., COULTHWAIT, C.L., MCGARRY, J.W., FORMAN, D.W., ALLEN, S., WALL, R., MORGAN, E.R. (2015): Increased prevalence and geographic spread of the cardiopulmonary nematode *Angiostrongylus vasorum* in fox populations in Great Britain. *Parasitology*, 142: 1190 – 1195
- TRAVERSA, D., DI CESARE, A., CONBOY, G. (2010): Canine and feline cardiopulmonary parasitic nematodes in Europe: emerging and underestimated. *Parasit. Vectors*, 3: 62
- UNTERER, S., DEPLAZES, P., ARNOLD, P., FLUCKIGER, M., REUSCH, C.E., GLAUS, T.M. (2002): Spontaneous *Crenosoma vulpis* infection in 10 dogs: laboratory, radiographic and endoscopic findings. *Schweiz Arch. Tierheilkd.*, 144: 174 – 179
- WETZEL, Z., MUELLER, R. (1935): The life cycle of *Crenosoma vulpis*, the lung worm of foxes, and ways and means of combat. *Fur Trade J. Can.*, 13: 16 – 17