

Bone Metastases as Presenting Sign of Mammary-like Vulvar Adenocarcinoma

Del Vecchio V*; Resta L; Mastromauro M; Loizzi V; Cicinelli E; Cormio G

***Vittoria Del Vecchio**

Department of Biomedical and Human Oncological Sciences (DIMO), 2nd Unit of Obstetrics and Gynecology, University of Bari, Piazza Giulio Cesare, 70124 Bari, Italy

Email: vittoria.delvecchiomd@gmail.com

Abstract

Mammary-like vulvar adenocarcinoma represents an extremely rare disease. Breast tissue develops from the embryonic ectoderm on the so called “milk-line”. During embryogenesis, this tissue undergoes spontaneous regression except in the chest region, where it gives rise to breasts in adults. When regression of “milk line” remnants fails to occur in the vulva, accessory breast structures may arise and could be susceptible to the physiologic, dysplastic and malignant changes seen in normal breast parenchyma.

We report a 52-years old woman who had pelvic bone metastases (left ischiopubic ramus and the homolateral femur trochanter and acetabulum) as presenting sign of small primary vulvar apocrine adenocarcinoma. She received surgery, chemotherapy and radiotherapy but died of disseminated disease 18 months after diagnosis.

Keywords

vulva; adenocarcinoma; bone; metastasis

Introduction

While over 90% of vulvar malignancies are squamous cell carcinomas, other histologic types include melanomas, basal cell carcinomas, sarcomas, different types of adenocarcinoma such as sweat gland carcinoma, extramammary Paget's disease and Bartholin gland adenocarcinomas. Although rare, adenocarcinoma arising from *mammary-like glands* in the vulva can also have malignant potential [1,2].

Breast tissue is derived from the embryonic ectoderm. The so-called “milk line” extends from the axilla to the medial aspect of the groin. During embryogenesis, this tissue undergoes spontaneous regression except in the chest region, where it gives rise to breasts in adults. When regression of “milk line” remnants fails to occur outside the pectoral region, accessory breast structures may arise. These are observed most frequently in the axillary region and only rarely at a vulvar site [3]. Furthermore, based on human embryologic studies, the mammary ridges could not involve the anogenital area, as at the height of the formation of the mammary ridges in 9 mm and 10 mm embryos, the labia majora are still far from their first appearance (van der Putte, 1994). However, ectopic breast tissue has been described in the vulva, as well as in any other area of the body. Both ectopic breast tissue and mammary-like glands are susceptible to the physiologic, dysplastic and malignant changes seen in normal breast parenchyma [1,4].

The histogenesis of primary vulvar adenocarcinomas is still not fully understood and the question of whether these neoplasms arise from the native apocrine sweat glands or from anogenital mammary-like glands is still debatable [5,6].

In this report, we present a case of a 52 years old female with a diagnosis of metastatic lesion involving the left iliac bone as the first manifestation of a rare apocrine carcinoma of the vulva.

Case Presentation

A 52-years old Caucasian nulliparous female complained of persistent and deep pelvic pain that arose 3 months before. She was asthenic, her appetite decreased and she referred to feel stabs of pain on her left leg. Blood test results were absolutely normal and a general examination showed that she was afebrile, not pale and that flexion movement of the left thigh provoked an immediate ache. For this reason she had undergone different diagnostic procedures. Pelvic MRI showed multiple osteolytic lesions and a bone scan revealed the presence of an intense radiolabeling area involving left ischiopubic ramus and the homolateral femur trochanter and acetabulum. Biopsy under CT guidance was made and pathologic examination revealed the presence of undifferentiated metastatic adenocarcinoma.

The patient underwent intensive staging with pelvic examination, transvaginal ultrasound and total body CT scan that revealed a large heterogeneous solid encapsulated lesion, with a diameter of about 7.5 cm, involving the uterine fundus, and a small nodule on the left surface of the vulvar labia maiora. Tumor markers (CA125, CA15.3, CA19.9 and α FP) were all within normal ranges.

The patient was referred to our Department with diagnosis of suspected uterine neoplasm with bone metastases. Total Abdominal *Hysterectomy* and Bilateral *Salpingo-Oophorectomy* with resection of the left vulvar lesion was performed. The uterus was distorted by the presence of a solid lesion involving the fundus, ovaries and fallopian tubes were normal. The vulvar lesion measured 3x2x2 cm, it was whitish and hard to touch. Pathologic diagnosis revealed an uterine myoma and a vulvar adenocarcinoma.

Microscopic examination showed the presence of basaloid epithelial cells into a basophilic stroma. These cells were characterized by an adenoma-like morphology because of the presence of “parietal splits” (figure A). Their peculiarity was the infiltration and the destruction of skeletal muscle (figure A) and of perineural space (figure B).

The adenocarcinoma cells expressed cytokeratin-pool (CK-pool), S-100 protein and were negative for estrogen (ER), carcinoembryonic antigen (CEA) and for complement regulatory protein Cd46.

The patient underwent chemotherapy with carboplatin, taxol and Zoledronic Acid for a total of 6 cycles followed by radiotherapy to the pelvis but died one year after for disseminated disease.

Discussion

Special types of sweat glands of the vulva reveal a specific histology that is different from eccrine, apocrine and mammary glands but, at the same time, they share features with each of them. They are named “anogenital mammary-like glands” because of their microscopic features that were similar to that of the breast tissue and are located in a high concentration in the interlabial sulcus of the vulva.

Apocrine carcinoma of the vulva can arise from the native apocrine sweat glands but also from the anogenital mammary-like glands. The presence of normal mammary-like glands in the vicinity of the

tumor, of a transition zone with variable malignant changes between the tumor and the normal mammary-like glands with positive immunostaining for ER and PR, and the demonstration of typical breast-like morphology are helpful features to classify vulvar adenocarcinoma as a mammary-like one, according to the recent literature. However, the absence of normal anogenital breast-like glands in the vicinity of the tumor or their lack of expression of hormone receptors doesn't definitely exclude them as the source of vulvar adenocarcinoma [3,5]. Histologically, carcinoma of anogenital mammary-like glands includes mammary-type ductal carcinoma, mammary-type lobular carcinoma, mammary-type mixed ductal and lobular carcinoma, tubulolobular carcinoma, mucinous carcinoma and vulvar adenoid cystic-like carcinoma [7]. The histopathological diagnosis is based on the presence of morphological and immunophenotypical features of the homologous mammary disease. Although rare, mammary-like ductal carcinoma is the most representative subtype of mammary-like glandular tumors of the vulva [8,9].

The prognosis of apocrine carcinoma of the vulva is poorly understood due to its rarity.

Primary vulvar apocrine adenocarcinomas can be *in situ* and confined to the vulvar sweat glands, or invasive [5]. Invasive vulvar apocrine adenocarcinoma has a potential for regional lymph node metastases but also metastases to distant organs have been described. Widespread metastases to the heart, lungs, abdominal organs, and bone have been reported. The presence of extensive lymphovascular invasion and metastases is associated with poor prognosis [5,10].

In the present case, the first manifestation of the neoplasm was a metastatic lesion involving the left iliac bone, without any lymph node involvement. However, bone metastases are frequently observed in women with advanced mammary tumors, but rarely in vulvar ones.

There is no consensus regarding classification, surgical management, and postoperative adjuvant therapy administration. In our case, the patient underwent chemotherapy with the association of Taxol, Carboplatin and Zoledronic Acid. She died one year after the termination of the treatment.

Figures

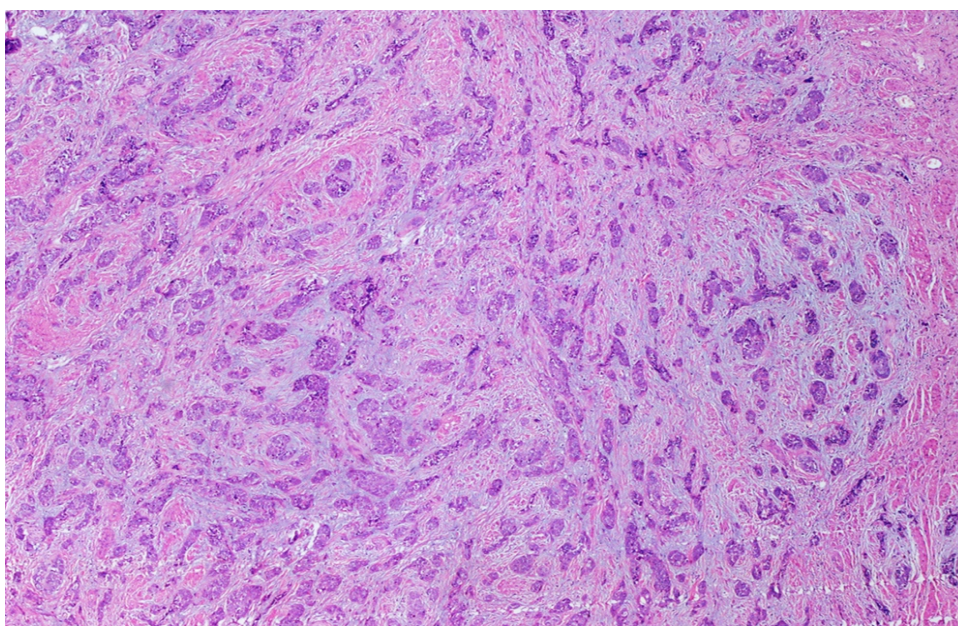


Figure A: H&E staining, 100x magnification.

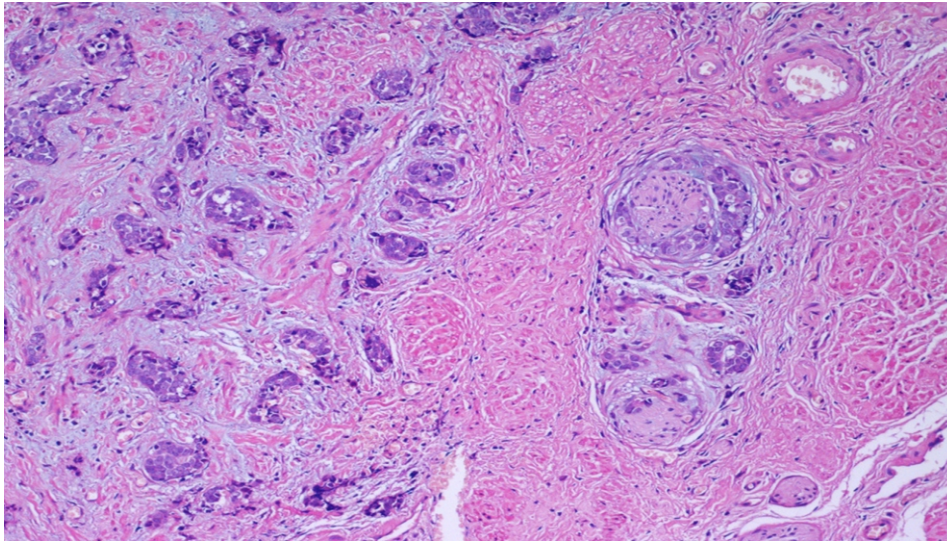


Figure B: H&E staining, 200x magnification.

Conclusion

Mammary-like carcinoma of the vulva is an extremely rare histological subtype of vulvar cancer that can appear in an absolute unconventional way. Before making the definite diagnosis of primary apocrine carcinoma of vulva, clinical examination and imaging studies are mandatory in order to exclude adenocarcinoma from other primary sites such as breast, alimentary and female reproductive tract. In the reported case, the extraordinary first manifestation of a primary apocrine carcinoma of the vulva was a bone metastatic disease.

References

1. Brandy Butler, Charles A. Leath, Jason C. Barnett. Primary invasive breast carcinoma arising in mammary-like glands of the vulva managed with excision and sentinel lymph node biopsy. *Gynecologic Oncology Case Reports* Volume 7 January 2014 Pages 7–9.
2. Sui Y Zou J, Batchu N, Lv S, Sun C, DU J, Wang Q, et al. Primary mucinous adenocarcinoma of the vulva: A case report and review of the literature. *Mol Clin Oncol*. 2016 Apr;4(4):545-548. Epub 2016 Feb 4.
3. E. Godoy-Gijón, M. Yuste-Chaves, Á. Santos-Briz, C. Esteban-Velasco, P. de Unamuno-Pérez. Accessory Breast on the Vulva. *Actas Dermosifiliogr*.2012;103:229-32 - Vol. 103 Num.3 DOI: 10.1016/j.adengl.2012.04.001.
4. Baykal C, Dündar I, Turkmen IC, Ozyar E. An unusual case of mammary gland-like carcinoma of vulva: case report and review of literature. *Eur J Gynaecol Oncol*. 2015;36(3):333-4.
5. Khaled O. Alsaad, Nidal Obaidat, Valerie Dube, William Chapman, Danny Ghazarian. Vulvar apocrine adenocarcinoma: A case with nodal metastasis and intranodal mucinous differentiation. *Pathology Research and Practice* Volume 205, Issue 2, 15 February 2009, Pages 131–135.
6. Benito V, Arribas S, Martínez D, Medina N, Lubrano A, Arencibia O. Metastatic adenocarcinoma of mammary-like glands of the vulva successfully treated with surgery and hormonal therapy. *J Obstet Gynaecol Res*. 2013 Jan;39(1):450-4. doi: 10.1111/j.1447-0756.2012.01937.x. Epub 2012 Jul 6.
7. Abbott JJ, Ahmed I. Adenocarcinoma of mammary-like glands of the vulva: Report of a case and review of the literature. *Am J Dermatopathol*. 2006 Apr;28(2):127-33.
8. Bogani G, Uccella S, Cromi A, Casarin J, Donadello N, Ghezzi F. Primary Mammary-like Ductal Carcinoma of the Vulva: A Case Report and Analysis of the Literature. *Am J Dermatopathol* 2013;35:685.

9. William P. Irvin, Helen P. Cathro, William W. Grosh, Laurel W. Rice, Willie A. Andersen. Primary Breast Carcinoma of the Vulva: A Case Report and Literature Review. *Gynecologic Oncology* Volume 73, Issue 1, April 1999, Pages 155–159.
10. Babita Kajal, Hetal Talati, Dean Daya, Salem Alowami. Apocrine adenocarcinoma of the vulva. *Rare tumors* 2013; volume 5:e40.

Manuscript Information: Received: Aug 17, 2016; Accepted: November 01, 2016; Published: November 03, 2016

Authors Information: Del Vecchio V^{1*}; Resta L³; Mastromauro M³; Loizzi V^{1,2}; Cicinelli E¹; Cormio G^{1,2}

¹Department of Biomedical and Human Oncological Sciences (DIMO), 2nd Unit of Obstetrics and Gynecology, University of Bari, Italy

²Gynecologic Oncology Unit, National Institute for Research and Treatment of Cancer “Giovanni Paolo II”, Bari, Italy

³Department of Pathology, University of Bari, Italy

Citation: Del Vecchio V, Resta L, Mastromauro M, Loizzi V, Cicinelli E, Cormio G. Bone metastases as presenting sign of mammary-like vulvar adenocarcinoma. *Open J Clin Med Case Rep.* 2016; 1182

Copy right statement: Content published in the journal follows Creative Commons Attribution License (<http://creativecommons.org/licenses/by/4.0>). © Del Vecchio V 2016

Journal: Open Journal of Clinical and Medical Case Reports is an international, open access, peer reviewed Journal focusing exclusively on case reports covering all areas of clinical & medical sciences.

Visit the journal website at www.jclinmedcasereports.com

For reprints & other information, contact editorial office at info@jclinmedcasereports.com