ACTA OTORHINOLARYNGOLOGICA ITALICA 2023;43(SUPPL.1):S41-S47; doi: 10.14639/0392-100X-suppl.1-43-2023-05

Otology section

Recurrent tympanic perforation after myringoplasty: a narrative literature review and personal experience

La perforazione timpanica recidivante dopo miringoplastica: revisione narrativa della letteratura ed esperienza personale

Vito Pontillo, Giada Cavallaro, Francesco Barbara, Mauro Mastrodonato, Alessandra Murri, Nicola Quaranta

Otorinolaringoiatria Universitaria, Dipartimento di Biomedicina Traslazionale e Neuroscienze, Università di Bari, Bari, Italy

SUMMARY

The aim of the work is to review the current literature concerning recidivism of tympanic perforation after myringoplasty and to give some tips to improve the chance of success and manage the possible scenario of failure. An analysis of the existing literature is presented and, based on it and on our experience, an algorithm of management of tympanic perforation recidivism is proposed.

KEY WORDS: myringoplasty, tympanic membrane perforation, recidivism, recurrent, residual, graft failure, unsuccess

RIASSUNTO

Questo studio si propone di analizzare i dati presenti in letteratura riguardanti la recidiva di perforazione timpanica dopo miringoplastica e di fornire degli utili suggerimenti per aumentare le possibilità di successo e gestire il possibile scenario dell'insuccesso. Infatti, verrà presentata la nostra proposta di un algoritmo di gestione delle riperforazioni dopo miringoplastica.

PAROLE CHIAVE: *miringoplastica, perforazione timpanica, recidiva, riperforazione, fallimento*

Received: January 15, 2023
Accepted: January 22, 2023

Correspondence
Vito Pontillo
Otorinolaringoiatria Universitaria
Policlinico di Bari, Università di Bari, piazza Giulio Cesare 11, 70124 Bari, Italy
Tel. +39 080 5592299
E-mail: pontillovito@gmail.com

How to cite this article: Pontillo V, Cavallaro G, Barbara F, et al. Recurrent tympanic perforation after myringoplasty: a narrative literature review and personal experience. Acta Otorhinolaryngol Ital 2023;43(SUPPL.1):S41-S47. https://doi.org/10.14639/0392-100X-suppl.1-43-2023-05

© Società Italiana di Otorinolaringoiatria e Chirurgia Cervico-Facciale

OPEN ACCESS

This is an open access article distributed in accordance with the CC-BY-NC-ND (Creative Commons Attribution-Non-Commercial-NoDerivatives 4.0 International) license. The article can be used by giving appropriate credit and mentioning the license, but only for non-commercial purposes and only in the original version. For further information: https://creativecommons.org/licenses/by-nc-nd/4.0/deed.en

Definitions and historical background

Tympanic membrane (TM) perforation is one of the most common conditions that otologists have to deal with in daily clinical practice [1]. TM may result from recurrent middle ear infections, trauma, or iatrogenic causes [2]. The majority (up to 80%) of these perforations have tendency to heal spontaneously. The remaining cases may be addressed to surgery, especially when patients experience major discomfort due to recurrent otorrhea, conductive hearing loss, or interdiction to water activities.

TM repair was first introduced by Berthold in 1878 [3] with the term of 'myringoplasty', and further developed by Zollner [4] and Wullstein [5] in the 50s, when it acquired the name of 'type I tympanoplasty'. The two terms are often used interchangeably, even if a theorical difference exists, in that tympanoplasty requires the elevation of a tympanomeatal flap while myringoplasty does not [6]. To avoid any misunderstanding, both these concepts will be referred as myringoplasty throughout the rest of this manuscript.

The main aim of myringoplasty is to eradicate the disease and create an intact TM, thus preventing recurrent or chronic middle ear infection. Secondly, continuity of the air-conduction mechanism from TM to inner ear should be ensured when possible [7].

Surgical techniques

Myringoplasty can be performed microscopically or endoscopically with an endomeatal, retroauricolar, or transmeatal approach. The surgeon's preferences and site of perforation determines the approach.

The use of autologous grafting material such as temporal fascia, perichondrium, cartilage, fat, periosteum, or vein is preferrable when available [8]. Two main techniques are currently in use based on the positioning of the graft with regards to the remnants of the tympanic membrane, the underlay and the overlay.

In our institution, the underlay technique, with the graft placed entirely medial to the TM remnants, is preferably performed as long as the fibrous annulus is preserved between 2 and 4 o'clock. It is quite easy and quick to perform, and the healing process is usually fast. However, in case of anterior perforations a good visualisation and steady anterior support on the bony annulus cannot be ensured.

In these cases, an underlay variant with anterior anchorage is performed: an accessory horizontal 3-4 mm incision is made approximately 4 mm lateral to the anterior annulus at about 10 o'clock and a subcutaneous tunnel is made to create an anterior window to the middle-ear; the antero-superior edge of the graft is then pulled through this window and allocated beneath the anterior flap; after graft placement, the anterior angle of the middle ear cavity should be packed with absorbable gelatine sponge to ensure further stability.

In anterior or subtotal perforations where the fibrous annulus is absent between 2 and 4 o'clock, the overlay technique is mandatory, thus allowing excellent visualisation of the anterior meatal recess. In our institution, the TM remnants and the skin of the EAC are always completely removed to reduce the risk of iatrogenic cholesteatoma, and the graft is then placed onto the bony annulus with a minimal overriding onto the canal wall. The anterior wall is then covered with the residual skin flap or, in rare cases, with a Tiersch graft [9], and then the anterior angle is carefully packed with small pieces of gelatine sponge. The main disadvantages of this technique are the risk of blunting of the anterior recess and the lateralisation of the graft; moreover, the healing process can be laborious and often longer.

Recidivism of tympanic membrane perforation

Myringoplasty can be a challenging procedure, and great variation in outcomes has been reported among different institutions and surgeons. In particular, the reported closure rates widely vary between 46% and 100% [9], depending on different factors which are often multiple and interconnected (Tab. I).

Recidivism of the perforation is one of the major complications after myringoplasty. Specifically, a distinction must be made between late re-perforation of a completely healed neotympanum, caused by a new trauma or infection or resulting from a progressive graft atrophy, and immediate post-operative graft failure, due to septic or aseptic graft necrosis, or inadequate anterior graft adaptation [10,11]. To avoid any confusion, late re-perforation will be referred as 'recurrent perforation' and immediate graft failure as 'residual perforation' throughout the rest of the manuscript.

Risk factors for recidivism

Several prognostic factors, often interconnected, can affect the results of myringoplasty.

Demographic and social factors

Age

Myringoplasty has historically been thought to be less successful in children than in adults, due to the immaturity of immune system and Eustachian tube (ET), prominent adenoid tissue and frequency of upper respiratory tract infections [12,13]. In fact, mean paediatric closure rates have been found to be slightly lower than in adults in both

Table I. Metanalysis of success rates after myringoplasty in different conditions (from Tan et al., 2016, mod.) [17].

Variables		No. patients	Success rate (%)	P
Age	Children (≤ 17)	4136	83.42	**0.017**
	Adults (> 17)	2049	89.25	
Perforation cause	Otitis media	8597	83.86	0.86
	Traumatic	472	87.25	
Perforation size	≤ 50%	5859	85.56	**0.019**
	> 50%	3374	79.44	
Perforation location	Central	4948	86.03	0.822
	Anterior	1268	85.42	
	Posterior	479	88.72	
Ear status	Dry	13048	87.02	0.155
	Wet	741	83.44	
Approach	Endaural	5341	86.02	0.112
	Postaural	8188	88.06	
Technique	Underlay	13359	86.71	0.712
	Overlay	2745	86.83	
	Inlay	1593	85.39	
Graft material	Fascia	14806	88.00	**0.048**
	Cartilage	1746	90.80	

Legend. In bold: statistically significant results.

single studies [13-16] and in a recent meta-analysis by Tan et al. [17] (Tab. I).

Socioeconomic level

Lower success rates have been reported in patients with low socioeconomic levels, probably due to poor post-operative care, low attendance of control dates, frequent airway infections and worse middle ear conditions [18].

Smoking

A recent systematic review [19] has demonstrated the negative impact of smoking on graft uptake rates after myringoplasty (77% of smokers *vs* 89% of non-smokers).
The effects of smoking on the middle ear physiology can be divided into 3 categories:

- local effects include those on middle ear and ET mucociliary clearance, by changing the amount and viscosity of the mucus, disrupting the ciliated cells and unsyncing ciliary activity [20]. Moreover, the vasoconstriction and thrombosis promoted by nicotine and the reduced tissue oxygenation induced by carbon monoxide increase the risk of graft necrosis [21];
- regional effects consist in causing eustachian tube obstruction by nasal chemical irritation [22];
- systemic effects are immunosuppressive and chemoallergic properties that may increase the susceptibility to infections [21].

Pathological factors

Size and location of the perforation

The highest failure rates have been recorded in total or near-total perforations [17,23-25] (Tab. I) and in case of involvement of the anterior half of the TM [18,26-27]. This is likely due to the reduced visibility, small area of overlap between the graft and residual TM, poor anterior support for the graft, and lower vascular perfusion of anterior quadrants [28,29].

Middle ear mucosa conditions

Higher failure rates have been reported in pre-operative discharging ears [15,25,30-32], and in the presence of intratympanic granulation tissue or tympanosclerotic plaques [33]. All these factors are thought to interfere with the normal healing process by affecting the vascularisation of the TM remnants, impairing the scaffold for epithelisation and displacing the graft.

Other pathological conditions

Poorer outcomes have been found in patients with contralateral chronic otitis media [11,23,34] and in children with no history of adenoidectomy or with craniofacial disorders [24,35], confirming the role of ET function in middle ear physiology.

Anatomical factors

Relevant technical issues can be caused by anterior wall prominence, exostosis or EAC stenosis, thus determining poor visualisation of the anterior angle [36].

Technical factors

No consensus exists about the best technique, which is often chosen based on the surgeon's skills and preference. The vast ambiguity of the results of various studies that compared the different procedures is probably due to the different technical variations and skills, selection methods, definitions of favourable outcome and follow-up.

Posterior vs endaural approach

Higher closure rates have been found using a retroauricolar approach compared to an endaural one in two studies [37,38]. This is probably due to improved visualisation of the anterior angle, limiting the indication of the endaural approach to small posterior perforations. However, this was not confirmed in the meta-analysis by Tan et al. [17].

Microscopic vs endoscopic myringoplasty

Transcanal endoscopic ear surgery has been proposed as an alternative to the microscopic retroauricolar approach. Several endoscopic series have shown success rates greater than 80% that is fully comparable to the microscopic rates [7], although other authors have shown better results for their microscopic cases (1-year failure rate 5.7% *vs* 12.5% with endoscopy) [36].

Primary vs revision myringoplasty

There is consensus that revision surgery is associated with slight lower success rates compared to primary surgeries [39-41]. This is probably due to altered anatomic landmarks and the necessity to use unusual graft materials.

Temporalis fascia vs cartilage

Within the full gamut of graft materials, from autologous to xenograft, no evidence exists with respect to the most effective grafting material for a given location, size, or type. Although temporalis fascia has been the material of choice for a long time, the use of tragal or conchal chondroperichondral grafts has recently been proposed, with the theoretical advantages of providing a rigid support against negative middle ear pressures and having minimal aesthetic consequences [11]. Although fascia provides adequate closure rates (nearly 90%) [42,43], cartilage has shown slightly better results in the meta-analysis by Tan et al. (Tab. I) [17], especially in high-risk perforations such as in case of ET dysfunction, diffuse tympanosclerosis, atelectasis, revision surgery, anterior perforations, purulent discharge at the time of surgery, and larger perforations [18,25,44-47].

Underlay vs overlay

No univocal evidence about the superiority of one technique over the other has been demonstrated in literature so far [2,48-51]. However, higher rates of residual perforation have been found in cases where an underlay technique was performed to treat anterior perforations [2]. In addition, overlay myringoplasty is inevitably associated with longer healing times [2].

Surgeon's experience

While several authors have reported statistically better graft success rates when myringoplasty was performed by experienced surgeons [16,31,52], others asserted that technical skills and attention to some details could be more relevant than the experience of the surgeon [53].

How to prevent recidivism

From the aforementioned analysis of risk factors for residual or recurrent perforation according to our experience and the literature, we next present some tips and tricks in order to increase the chances of success.

Indication and timing

Paediatric closure rates are not so low as to contraindicate myringoplasty in children [23], although some authors have suggested to delay surgery until the age of 8 [54-56]. One of the drawbacks of delayed surgery is the potential evolution to cholesteatoma or permanent inner ear damage in case of recurrent infections [57]. In our experience, myringoplasty can be performed in children, regardless of the age in case of cholesteatoma, preferably after age 6 in chronic otitis media (COM) with no evidence of cholesteatoma, and in the presence of dry ear and stable rhino-pharyngeal conditions.
A decisive factor in the success of myringoplasty is the incidence of post-operative infections. The management and timing of chronically discharging perforations is never simple, but every effort should be made to perform ear surgery only after appropriate drying by the aid of antibiotic-steroid ear drops and acetic acid solutions. When this is not possible, this should not be a restrictive factor in performing myringoplasty, because middle ear normalisation may be promoted by closure of the middle ear cavity, as suggested by the literature [11]. However, in these cases the use of peri- and post-operative systemic antibiotics may help in reducing the risk of infection and thus graft displacement. In fact, even though a Cochrane review found no difference in graft failure rates when comparing intra-operative antibiotics with placebo [58], a prospective double-blind placebo-controlled randomised study did demonstrate decreased infectious risk when intra-operative antibiotics were used in perforations with pre-operative discharge [59].

Technical precautions

As mentioned, two of the main risk factors for residual perforation after myringoplasty are the presence of tympanosclerotic plaques and involvement of the anterior half of the TM, conditions that may require several adjustments to the technique.
Removal of tympanosclerotic plaques should be always performed before each TM reconstruction, especially in the anterior remnant of the drum, to facilitate the epithelisation process. This can be done by gently dissection using a sharp needle.
Three main methods have been proposed to prevent weak anterior adaptation in case of anterior perforations: the overlay technique [2], the underlay with anterior anchoring [60], and the circumferential flap method. The latter requires that the fibrous annulus be elevated 360°, thus completely exposing the bony anulus all around, on which the graft is placed [61]. No significant difference between the three techniques have been found in terms of graft uptake rates, hearing results and post-operative complications [60,61]. In our institution, the anterior anchoring technique is usually performed in anterior perforations with satisfying results (success rate 95%), while the overlay myringoplasty is reserved for cases when the fibrous annulus is not maintained between 2 and 4 o'clock.
Additionally, some authors have proposed cartilage reinforcement myringoplasty as a reliable technique in anterior perforations, especially in revision cases, demonstrating good closure rates with no effect on hearing results [47].
Regardless of the chosen technique, adequate drilling of the anterior bulge of the external auditory canal is the first precaution to take in case of anterior perforation, thus improving the exposure of the anterior angle [2,62]. Some authors claim that endoscopic techniques can help manage the issue of anterior wall overhang by providing a more detailed and broader surgical view compared to the microscope [63].
In order to maximise the results, some surgeons opt to perform simultaneous canal-wall up cortical mastoidectomy in chronically discharging ears, especially in case of hyperplastic and polypoid chronic otitis media and in ET dysfunctions [64]. The opening of abnormal mastoid cells and the resection of granulations will both remove a future source of infection that may result in graft failure and improve middle ear aeration [65,66]. However, conflicting evidence exists regarding the benefit of this additional procedure [64,67].

Our management algorithm proposal

Despite all the forementioned technical precautions, graft failure with consequent recidivism of the perforation is still a possibility to take into account after myringoplasty. Based on our experience and the literature review we have

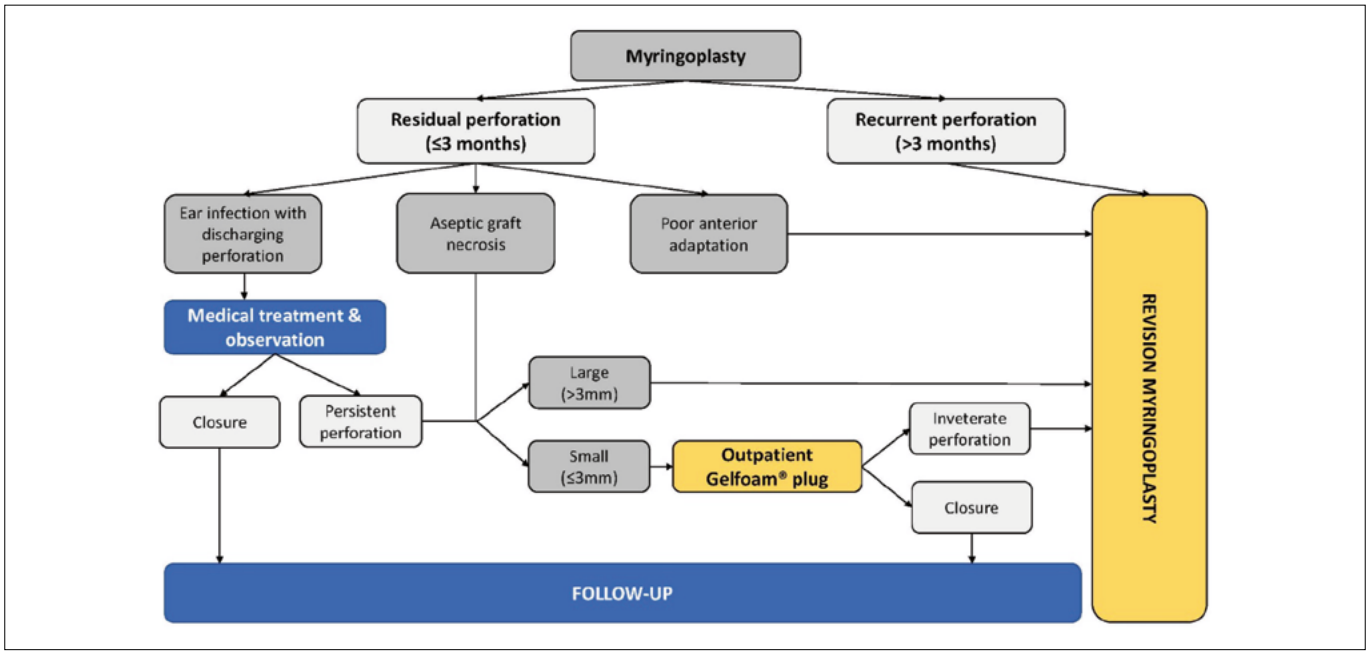

Figure 1. Proposed algorithm for the management of recidivism of MT perforation after myringoplasty.

proposed an algorithm for management of graft failure (Fig. 1).

While in case of late re-perforation of a healed neotympanum revision myringoplasty is often necessary, in the case of a residual perforation in the first three months after surgery a careful analysis of the issue should be made. When an ear infection is thought to be the reason for graft displacement, prompt medical treatment with systemic and local antibiotics can reduce ear discharge and promote healing. When this precaution is still not effective, or when the graft necrosis does not result from an infection, a surgical option must be taken into consideration. In case of small perforations, an outpatient Gelfoam® plug procedure [68] can be attempted after proper freshening of the margins. In case of failure or large perforations, revision myringoplasty should be performed. When residual perforation is assumed to be the consequence of a technical fault resulting in a poor anterior adaptation of the graft, revision myringoplasty with correction of the defects is often proposed to the patient.

Revision myringoplasty

Revision myringoplasty for residual or recurrent TM perforation is often more challenging than the primary procedure which is due to the altered anatomy and distorted surgical landmarks [10,69] and to the restricted availability of autologous grafting materials, making the use of bovine xenografts or human allografts compulsory [70]. The main aim of revision myringoplasty is to avoid and correct the technical faults made in primary surgery.

Conclusions

Myringoplasty is one of the most common surgeries performed by an otologist, but can be a challenging procedure. Recidivism of tympanic membrane perforation after myringoplasty can result from different causes. Understanding the factors that can have an effect on outcomes can help the surgeon to prevent failure, while a prompt analysis of the causes or faults of unsuccessful myringoplasty can minimise the sequelae of the complication. In this paper, contemporary literature results and our experience were analysed in order to help the otologist facing this scenario.

Acknowledgements

We would like to show our gratitude to the University of Bari for the support and for providing all the scientific material for the research.

All data and material are available and can be provided if requested.

Conflict of interest statement

The authors declare no conflict of interest.

Funding
This research did not receive any specific grant from funding agencies in the public, commercial, or not-for-profit sectors.

Author contributions
VP and NQ have conceived, designed, written and revised the work. GC, FB, MM and AM have taken part to the writing of the present paper.
VP, NQ, GC, FB, MM and AM have contributed to the diagnostic and therapeutic processes and to the writing of the present paper.

Ethical consideration
Not applicable.

References

1 Dolhi N, Weimer AD. Tympanic membrane perforations. 2022 Aug 8. In: StatPearls [Internet]. Treasure Island (FL): StatPearls Publishing; 2022 Jan.

2 Sergi B, Galli J, De Corso E, et al. Overlay versus underlay myringoplasty: report of outcomes considering closure of perforation and hearing function. Acta Otorhinolaryngol Ital 2011;31:366-371.

3 Berthold E. Ueber myringoplastik. Wier Med Bull 1878;1:627-627.

4 Zollner F. The principles of plastic surgery of the sound-conducting apparatus. J Laryngol Otol 1955;69:637-652.

5 Wullstein H. Theory and practice of tympanoplasty. Laryngoscope 1956;66:1076-1093. https://doi.org/10.1288/00005537-195608000-00008

6 Mudry A. History of myringoplasty and tympanoplasty type I. Otolaryngol Head Neck Surg 2008;139:613-614. https://doi.org/10.1016/j.otohns.2008.07.014

7 Schwam ZG, Cosetti MK. Endoscopic myringoplasty and type i tympanoplasty. Otolaryngol Clin North Am 2021;54:75-88. https://doi.org/10.1016/j.otc.2020.09.010

8 Berglund M, Suneson P, Florentzson R, et al. Tinnitus and taste disturbances reported after myringoplasty: data from a national quality registry. Laryngoscope 2019;129:209-215. https://doi.org/10.1002/lary.27325

9 Xu H, Pollak N, Paparella MM. Thiersch skin grafting in otologic surgery. Ear Nose Throat J 2013;92:348-356. https://doi.org/10.1177/014556131309200808

10 Berger G, Ophir D, Berco E, et al. Revision myringoplasty. J Laryngol Otol 1997;111:517-520. https://doi.org/10.1017/s0022215100137818

11 Nardone M, Sommerville R, Bowman J, et al. Myringoplasty in simple chronic otitis media: critical analysis of long-term results in a 1,000-adult patient series. Otol Neurotol 2012;33:48-53. https://doi.org/10.1097/MAO.0b013e31823dbc26

12 Berger G, Shapira A, Marshak G. Myringoplasty in children. J Otolaryngol1983;12:228-230.

13 Raine CH, Singh SD. Tympanoplasty in children. A review of 114 cases. J Laryngol Otol 1983;97:217-221. https://doi.org/10.1017/s0022215100094032

14 Van Baarle PW, Huygen PL, Brinkman WF. Findings in surgery for chronic otitis media. A retrospective data-analysis of 2225 cases followed for 2 years. Clin Otolaryngol Allied Sci 1983;8:151-158. https://doi.org/10.1111/j.1365-2273.1983.tb01419.x

15 Pignataro L, Grillo Della Berta L, Capaccio P, et al. Myringoplasty in children: anatomical and functional results. J Laryngol Otol 2001;115:369-373. https://doi.org/10.1258/0022215011907893

16 Emir H, Ceylan K, Kizilkaya Z, et al. Success is a matter of experience: type 1 tympanoplasty: influencing factors on type 1 tympanoplasty. Eur Arch Otorhinolaryngol 2007;264:595-599. https://doi.org/10.1007/s00405-006-0240-6

17 Tan HE, Santa Maria PL, Eikelboom RH, et al. Type I tympanoplasty meta-analysis: a single variable analysis. Otol Neurotol 2016;37:838-846. https://doi.org/10.1097/MAO.0000000000001099

18 Tek A, Karaman M, Uslu C, et al. Audiological and graft take results of cartilage reinforcement tympanoplasty (a new technique) versus fascia. Eur Arch Otorhinolaryngol 2012;269:1117-1126. https://doi.org/10.1007/s00405-011-1779-4

19 Visvanathan V, Vallamkondu V, Bhimrao SK. What effect does smoking have on the surgical closure of tympanic membrane perforations? A review. Otol Neurotol 2018;39:1217-1221. https://doi.org/10.1097/MAO.0000000000002011

20 Gulya AJ. Environmental tobacco smoke and otitis media. Otolaryngol Head Neck Surg 1994;111:6-8. https://doi.org/10.1177/019459989411100103

21 Dangol K, Shrivastav RP. Study of various prognostic factors affecting successful myringoplasty in a Tertiary Care Centre. Int Arch Otorhinolaryngol 2017;21:250-254. https://doi.org/10.1055/s-0036-1593818

22 Becvarovski Z, Kartush JM. Smoking and tympanoplasty: implications for prognosis and the Middle Ear Risk Index (MERI). Laryngoscope 2001;111:1806-1811. https://doi.org/10.1097/00005537-200110000-00026

23 Hardman J, Muzaffar J, Nankivell P, et al. Tympanoplasty for chronic tympanic membrane perforation in children: systematic review and meta-analysis. Otol Neurotol 2015;36:796-804. https://doi.org/10.1097/MAO.0000000000000767

24 Foulon I, Philips D, Lichtert E, et al. Pediatric myringoplasty: a study of effectiveness and influencing factors. Int J Pediatr Otorhinolaryngol 2022;153:110990. https://doi.org/10.1016/j.ijporl.2021.110990

25 Dispenza F, Battaglia AM, Salvago P, et al. Determinants of failure in the reconstruction of the tympanic membrane: a case-control study. Iran J Otorhinolaryngol 2018;30:341-346.

26 Hosamani P, Ananth L, Medikeri SB. Comparative study of efficacy of graft placement with and without anterior tagging in type one tympanoplasty for mucosal-type chronic otitis media. J Laryngol Otol 2012;126:125-130. https://doi.org/10.1017/S0022215111002659

27 Onal K, Arslanoglu S, Songu M, et al. Functional results of temporalis fascia versus cartilage tympanoplasty in patients with bilateral chronic otitis media. J Laryngol Otol 2012;126:22-25. https://doi.org/10.1017/S0022215111002817

28 Vartiainen E, Kärjä J, Karjalainen S, et al. Failures in myringoplasty. Arch Otorhinolaryngol 1985;242:27-33. https://doi.org/10.1007/BF00464402

29 Applebaum EL, Deutsch EC. An endoscopic method of tympanic membrane fluorescein angiography. Ann Otol Rhinol Laryngol 1986;95:439-443. https://doi.org/10.1177/000348948609500501

30 Vartiainen E, Nuutinen J. Success and pitfalls in myringoplasty: follow-up study of 404 cases. Am J Otol 1993;14:301-305.

31 Onal K, Uguz MZ, Kazikdas KC, et al. A multivariate analysis of otological, surgical and patient-related factors in determining success in myringoplasty. Clin Otolaryngol 2005;30:115-120. https://doi.org/10.1111/j.1365-2273.2004.00947.x

32 Pinar E, Sadullahoglu K, Calli C, et al. Evaluation of prognostic factors and middle ear risk index in tympanoplasty. Otolaryngol Head Neck Surg 2008;139:386-390. https://doi.org/10.1016/j.otohns.2008.05.623

33 Migirov L, Volkov A. Influence of coexisting myringosclerosis on myringoplasty outcomes in children. J Laryngol Otol 2009;123:969-972. https://doi.org/10.1017/S0022215109005520

34 Faramarzi M, Shishegar M, Tofighi SR, et al. Comparison of grafting success rate and hearing outcomes between primary and revision tympanoplasties. Iran J Otorhinolaryngol 2019;31:11-17.

35 Duval M, Grimmer JF, Meier J, et al. The effect of age on pediatric tympanoplasty outcomes: a comparison of preschool and older children. Int J Pediatr Otorhinolaryngol 2015;79:336-341. https://doi.org/10.1016/j.ijporl.2014.12.017

36 Dündar R, Kulduk E, Soy FK, et al. Endoscopic versus microscopic approach to type 1 tympanoplasty in children. Int J Pediatr Otorhinolaryngol 2014;78:1084-1089. https://doi.org/10.1016/j.ijporl.2014.04.013

37 Labatut Pesce T, Sierra Grañon C, Mora Rivas E, et al. Primary myringoplasties. Results after a 2 year follow-up period. Acta Otorrinolaringol Esp 2009;60:79-83.

38 Albera R, Ferrero V, Lacilla M, et al. Tympanic reperforation in myringoplasty: evaluation of prognostic factors. Ann Otol Rhinol Laryngol 2006;115:875-879. https://doi.org/10.1177/000348940611501202

39 Gibb AG, Chang SK. Myringoplasty (a review of 365 operations). J Laryngol Otol 1982;96:915-930. https://doi.org/10.1017/s0022215100093270

40 Packer P, Mackendrick A, Solar M. What's best in myringoplasty: underly or overlay, dura or fascia? J Laryngol Otol 1982;96:25-41. https://doi.org/10.1017/s0022215100092203

41 Phillips JS, Yung MW, Nunney I. Myringoplasty outcomes in the UK. J Laryngol Otol 2015;129:860-864. https://doi.org/10.1017/S002221511500198X

42 Gerber MJ, Mason JC, Lambert PR. Hearing results after primary cartilage tympanoplasty. Laryngoscope 2000;110:1994-1999. https://doi.org/10.1097/00005537-200012000-00002

43 Dornhoffer JL. Hearing results with cartilage tympanoplasty. Laryngoscope 1997;107:1094-1099. https://doi.org/10.1097/00005537-199708000-00016

44 Kerr AG, Byrne JE, Smyth GD. Cartilage homografts in the middle ear: a long-term histological study. J Laryngol Otol 1973;87:1193-1199. https://doi.org/10.1017/s0022215100078166

45 Buckingham RA. Fascia and perichondrium atrophy in tympanoplasty and recurrent middle ear atelectasis. Ann Otol Rhinol Laryngol 1992;101:755-758. https://doi.org/10.1177/000348949210100907

46 Glasscock ME 3rd, Jackson CG, Nissen AJ, et al. Post-auricular undersurface tympanic membrane grafting: a follow-up report. Laryngoscope 1982;92:718-727. https://doi.org/10.1288/00005537-198207000-00002

47 Uslu C, Tek A, Tatlipinar A, et al. Cartilage reinforcement tympanoplasty: otological and audiological results. Acta Otolaryngol 2010;130:375-383. https://doi.org/10.3109/00016480903145346

48 Glasscock ME 3rd. Tympanic membrane grafting with fascia: overlay vs undersurface technique. Laryngoscope 1973;83:754-770. https://doi.org/10.1288/00005537-197305000-00011

49 Sheehy JL, Anderson RG. Myringoplasty. A review of 472 cases. Ann Otol Rhinol Laryngol 1980;89:331-334. https://doi.org/10.1177/000348948008900407

50 Rizer FM. Overlay versus underlay tympanoplasty. Part II: the study. Laryngoscope 1997;107:26-36. https://doi.org/10.1097/00005537-199712001-00002

51 Wang WH, Lin YC. Minimally invasive inlay and underlay tympanoplasty. Am J Otolaryngol 2008;29:363-366. https://doi.org/10.1016/j.amjoto.2007.11.002

52 Vartiainen E. The results of chronic ear surgery in a training programme. Clin Otolaryngol Allied Sci 1998;23:177-180. https://doi.org/10.1046/j.1365-2273.1998.00127.x

53 Palva T, Ramsay H. Myringoplasty and tympanoplasty – results related to training and experience. Clin Otolaryngol Allied Sci 1995;20:329-335. https://doi.org/10.1111/j.1365-2273.1995.tb00053.x

54 Sheahan P, O'Dwyer T, Blayney A. Results of type 1 tympanoplasty in children and parental perceptions of outcome of surgery. J Laryngol Otol 2002;116:430-434. https://doi.org/10.1258/0022215021911211

55 Kessler A, Potsic WP, Marsh RR. Type 1 tympanoplasty in children. Arch Otolaryngol Head Neck Surg 1994;120:487-490. https://doi.org/10.1001/archotol.1994.01880290005001

56 Isaacson G. Tympanoplasty in children. Otolaryngol Clin North Am 1994;27:593-605.

57 Knapik M, Saliba I. Pediatric myringoplasty: a study of factors affecting outcome. Int J Pediatr Otorhinolaryngol 2011;75:818-823. https://doi.org/10.1016/j.ijporl.2011.03.015

58 Verschuur HP, de Wever WW, van Benthem PP. Antibiotic prophylaxis in clean and clean-contaminated ear surgery. Cochrane Database Syst Rev 2004;2004:CD003996. https://doi.org/10.1002/14651858.CD003996.pub2

59 Govaerts PJ, Raemaekers J, Verlinden A, et al. Use of antibiotic prophylaxis in ear surgery. Laryngoscope 1998;108:107-110. https://doi.org/10.1097/00005537-199801000-00020

60 Visvanathan V, Vallamkondu V, Bhimrao SK. Achieving a successful closure of an anterior tympanic membrane perforation: evidence-based systematic review. Otolaryngol Head Neck Surg 2018;158:1011-1015. https://doi.org/10.1177/0194599818764335

61 Dhanapala N, Hussain SM, Reddy LS, et al. Comparative study of clinical and audiological outcome between anterior tucking and circumferential flap methods of type I tympanoplasty in large central perforation. Indian J Otol 2018;24:190-193.

62 Heermann H. Tympanoplasty with fascial tissue taken from the temporal muscle after straightening the anterior wall of the auditory meatus. HNO 1961;9:136-137.

63 Ayache S. Cartilaginous myringoplasty: the endoscopic transcanal procedure. Eur Arch Otorhinolaryngol 2013;270:853-860. https://doi.org/10.1007/s00405-012-2056-x

64 Karunaratne D, Violaris N. Myringoplasty outcomes from a 5-year single surgeon's experience and important surgical technical aspects. J Audiol Otol 2021;25:224-229. https://doi.org/10.7874/jao.2021.00311

65 Tos M. Manual of middle ear surgery. First edition. New York: Thieme; 1993.

66 McGrew BM, Jackson CG, Glasscock ME 3rd. Impact of mastoidectomy on simple tympanic membrane perforation repair. Laryngoscope 2004;114:506-511. https://doi.org/10.1097/00005537-200403000-00023

67 Albu S, Trabalzini F, Amadori M. Usefulness of cortical mastoidectomy in myringoplasty. Otol Neurotol 2012;33:604-609. https://doi.org/10.1097/MAO.0b013e31825368f2

68 Niklasson A, Tano K. The Gelfoam® plug: an alternative treatment for small eardrum perforations. Laryngoscope 2011;121:782-784. https://doi.org/10.1002/lary.21451

69 Prinsley P. Results of revision myringoplasty: are they different to those of primary myringoplasty?. J Laryngol Otol 2017;131:316-318. https://doi.org/10.1017/S0022215117000202

70 Declau F, Karen KVdG, Wuyts FL. Uncomplicated type 1 tympanoplasty with bovine xenografts versus human allografts: functional results and prognostic factors for graft success. B-ENT 2017;13:167-176.