

# Coronary-specific quantification of myocardial deformation by strain echocardiography may disclose the culprit vessel in patients with non-ST-segment elevation acute coronary syndrome

Andrea Igoeren Guaricci <sup>1,\*</sup>, Giuseppina Chiarello<sup>1</sup>, Elisa Gherbesi<sup>2</sup>, Laura Fusini<sup>3</sup>, Nicolo' Soldato<sup>1</sup>, Paola Siena<sup>1</sup>, Raffaella Ursi<sup>1</sup>, Roberta Ruggieri<sup>1</sup>, Marco Guglielmo<sup>3</sup>, Giuseppe Muscogiuri<sup>3</sup>, Andrea Baggiano<sup>3</sup>, Mark G. Rabbat<sup>4</sup>, Riccardo Memeo<sup>1</sup>, Mario Lepera<sup>1</sup>, Stefano Favale<sup>1</sup>, and Gianluca Pontone<sup>3</sup>

<sup>1</sup>Department of Emergency and Organ Transplantation, University Cardiology Unit, Policlinic University Hospital, Piazza Giulio Cesare 11, Bari 70124, Italy; <sup>2</sup>Department of Clinical Sciences and Community Health, University of Milan, Milan, Italy; and <sup>3</sup>Perioperative Cardiology and Cardiovascular Imaging Department, Centro Cardiologico Monzino, IRCCS, Milan, Italy; and <sup>4</sup>Loyola University of Chicago, Chicago, IL, USA

Received 6 October 2021; revised 6 December 2021; editorial decision 4 January 2022; online publish-ahead-of-print 25 February 2022

Handling Editor: Alessia Gimelli

This study refers to A.I. Guaricci, N. Soldato, G. Chiarello, and G. Pontone. Territorial longitudinal strain discloses the culprit vessel in a patient with non-ST-segment elevation acute coronary syndrome. *European Heart Journal - Case Reports* 2022; doi: [10.1093/ehjcr/ytac097](https://doi.org/10.1093/ehjcr/ytac097). <https://doi.org/10.1093/ehjcr/ytac097>.

## Aims

To compare the diagnostic accuracy of speckle tracking echocardiography technique using territorial longitudinal strain (TLS) for the detection of culprit vessel vs. vessel-specific wall motion score index (WMSI) in non-ST-segment elevation–acute coronary syndrome (NSTEMI-ACS) patients scheduled for invasive coronary angiography (ICA).

## Methods and results

One hundred and eighty-three patients (mean age:  $66 \pm 12$  years, male: 71%) diagnosed with NSTEMI-ACS underwent echocardiography evaluation at hospital admission and ICA within 24 h. Culprit vessels were left anterior descending (LAD), left circumflex (CX), and right coronary arteries (RCAs) in 38.5%, 39.6%, and 21.4%, respectively. An increase of affected vessels [1-, 2-, and 3-vessel coronary artery disease (CAD)] was associated with increased WMSI and TLS values. There was a statistically significant difference of both WMSI-LAD, WMSI-CX, WMSI-RCA and TLS-LAD, TLS-CX, TLS-RCA of myocardial segments with underlying severe CAD compared to no CAD ( $P = 0.001$  and  $P < 0.001$ , respectively). Moreover, a significant difference of TLS-LAD, TLS-CX, TLS-RCA, and WMSI-CX of myocardial segments with an underlying culprit vessel compared to non-culprit vessels ( $P < 0.001$ ,  $P < 0.001$ ,  $P = 0.022$ , and  $P < 0.001$ , respectively) was identified. WMSI-LAD and WMSI-RCA did not show statistical significant differences. A regression model revealed that the combination of WMSI + TLS was more accurate compared to WMSI alone in detecting the culprit vessel (LAD,  $P = 0.001$ ; CX,  $P < 0.001$ ; and RCA,  $P = 0.019$ ).

## Conclusion

Territorial longitudinal strain allows an accurate identification of the culprit vessel in NSTEMI-ACS patients. In addition to WMSI, TLS may be considered as part of routine echocardiography for better clinical assessment in this subset of patients.

## Keywords

2D speckle tracking echocardiography • Territorial longitudinal strain • Non-ST-elevation myocardial infarction • Culprit lesion

\* Corresponding author. Tel: +39 080 5592740, Email: [andrea.guaricci@gmail.com](mailto:andrea.guaricci@gmail.com)

© The Author(s) 2022. Published by Oxford University Press on behalf of the European Society of Cardiology.

This is an Open Access article distributed under the terms of the Creative Commons Attribution-NonCommercial License (<https://creativecommons.org/licenses/by-nc/4.0/>), which permits non-commercial re-use, distribution, and reproduction in any medium, provided the original work is properly cited. For commercial re-use, please contact [journals.permissions@oup.com](mailto:journals.permissions@oup.com)

## Introduction

Acute coronary syndromes affect ~800 000 patients per year in the USA, of whom two-thirds are diagnosed as non-ST-segment elevation–acute coronary syndrome (NSTEMI). Over a period of 20 years, the proportion of non-ST-segment elevation myocardial infarction (NSTEMI) grew as high as four-fold in comparison to ST-segment elevation myocardial infarction (STEMI). This phenomenon is most likely due to both a reduced rate of STEMI and to a more prompt diagnostic process of NSTEMI.<sup>1,2</sup> Non-ST-segment elevation–acute coronary syndrome occurs primarily as a consequence of a sudden drop of myocardial blood flow due to acute plaque rupture or plaque erosion leading to partially occluding thrombosis.<sup>3,4</sup> Recently, novel cardiac imaging techniques have developed in the field of myocardial ischaemic injury.<sup>5–9</sup> Specifically, in the setting NSTEMI patients, conventional echocardiographic assessment may reveal regional myocardial wall motion abnormality of the left ventricle as well as absence of kinetic alteration (25–76% of cases).<sup>10–12</sup> Speckle tracking echocardiography (STE) is a validated and accurate technique able to detect subtle changes of the regional systolic left ventricular (LV) function.<sup>13–15</sup> Previous reports showed that global and regional LV two-dimensional (2D) strain may non-invasively predict multivessel coronary artery disease (CAD) in patients with NSTEMI.<sup>16–18</sup> Early evaluation of these patients is crucial in order to choose the appropriate treatment strategy including the timing of reperfusion therapy. The aim of our study was to evaluate the ability of STE to predict the culprit vessel in patients with NSTEMI-ACS as compared to visual assessment of LV kinesis and, in particular, to the wall motion score index (WMSI).

## Material and methods

### Study population

We studied consecutive symptomatic patients diagnosed with NSTEMI-ACS admitted in our tertiary referral hospital from September 2018 to September 2020. Non-ST-segment elevation–acute coronary syndrome was defined as an increase or decrease of cardiac biomarker with at least one value above the 99 percentile of the URL according to the recent international Guidelines.<sup>12</sup> Twelve-lead surface EKG was performed at admission and myocardial ischaemia was defined as any ST-deviation >0.5 mm or symmetric T-wave inversion >3 mm in two or more contiguous leads. Serial high-sensitivity Troponin sampling was assessed to detect the peak level before and after invasive coronary angiography (ICA). Exclusion criteria were age <18 years, history of previous myocardial infarction and/or myocardial revascularization (PTCA and/or coronary artery by-pass graft), severe valvular heart disease, persistent ST-elevation or complete bundle branch block on surface EKG at hospital admission and/or during hospitalization, atrial fibrillation with heart rate faster than 100 b.p.m., and inadequate echocardiographic acoustic windows. A scoring system predicting in-hospital mortality in patients with ACS was performed. We used the GRACE risk score which includes age, heart rate, systolic blood pressure, Killip class, cardiac arrest on admission, ST-segment deviation, serum, and cardiac biomarker levels.<sup>19</sup> Written informed consent was obtained from all patients, and the institutional ethics committee approved the study protocol.

### Echocardiography and two-dimensional strain

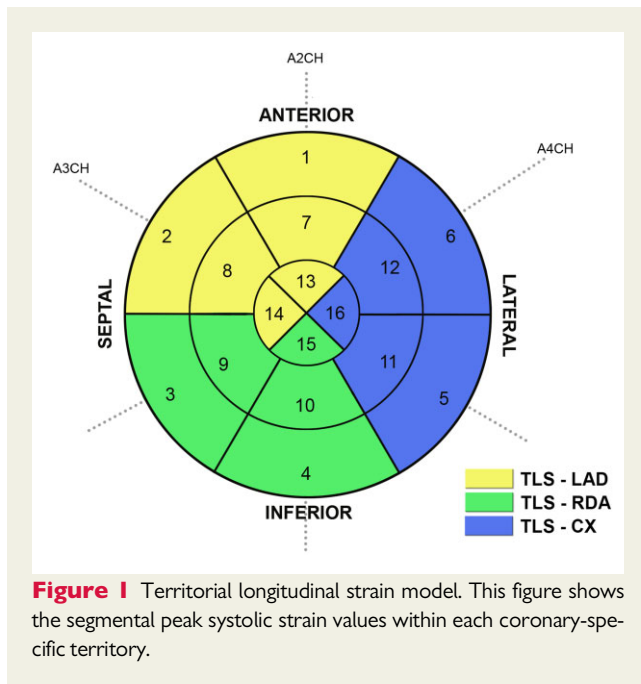
All patients underwent echocardiography immediately prior to ICA. Both conventional echocardiography and longitudinal strain imaging were performed by two experienced readers, who were blinded to patient characteristics. All images were obtained using EPIQ equipment (Philips, Erlangen, Germany) and videotaped in standard windows. Parasternal long-axis and short-axis, apical two-chamber and four-chamber views were acquired recording EKG tracings. We used the peak of the R-wave to identify end-diastole, while end-systole was defined as closure of the aortic valve. Echocardiographic measurements were calculated according to the current American Society of Echocardiography guidelines and LV mass was obtained using the Devereux formula.<sup>20</sup> We measured LV end-systolic and end-diastolic volumes in the apical four-chamber and two-chamber view, and calculated the LV ejection fraction (LVEF) using the modified Simpson's rule. A 16-segment model of the left ventricle was used to calculate WMSI.<sup>21</sup> Two readers classified segmental wall motion using the following score: (1) normal; (2) hypokinetic; (3) akinetic; and (4) dyskinesic. Imaging data were analysed and WMSI<sup>22</sup> was calculated as the average value of the studied segments. Myocardial function was assessed by evaluating the deformation of the myocardium using 2D STE and endocardial borders were detected at 2D end-systole. The IE33 QLAB-CMQ software was used to analyse obtained values. All peak strain values were automatically recorded. Whenever auto-tracking failed to outline correctly, the two readers independently manually repeated the 2D speckle-tracking measurements. Untraceable segments were excluded from the analysis. A total of 16 segments were investigated, and we used apical four-chamber, apical two-chamber, and apical three-chamber views to calculate the global strain. The obtained mean value of all segmental strain was used to define the global longitudinal strain (GLS). The territorial longitudinal strain (TLS) was calculated based on the perfusion territories of left anterior descending coronary artery (LAD), circumflex artery (Cx), and right coronary artery (RCA) in a 16 segments LV model, grouping and averaging the segmental peak systolic strain values within each territory (Figure 1).<sup>21,23,24</sup>

### Coronary angiography and treatment strategy

Patient medical management was performed in agreement with current Guidelines.<sup>12</sup> All patients underwent ICA within the first 24 h from hospital admission. Coronary artery lesions were assessed by two skilled invasive cardiologists (more than 10 years of experience). Significant CAD was defined as any luminal stenosis more than 70% in a major epicardial coronary vessel and the culprit lesion was identified and treated with PTCA at the discretion of the operators.

### Statistical analysis

Continuous data are presented as mean  $\pm$  standard deviation and categorical variables as absolute frequencies (percentages), as appropriate. Group comparisons were performed using unpaired Student's *t*-test for continuous variables, and  $\chi^2$  test or Fisher's exact test for categorical variables, as appropriate. Wall motion score index and TLS were tested in univariate and multivariate logistic regression analysis for the identification of independent



variables predicting the culprit vessel. The incremental value in predicting culprit lesion by inclusion of TLS in addition to WMSI was assessed by the  $\chi^2$  using Omnibus test of model coefficients. To assess the reproducibility of the strain measurements, intra- and interobserver variability were evaluated in a subset of 30 randomly selected patients. Each parameter was re-evaluated  $\geq 2$  weeks later on the same echocardiographic dataset by the main investigator and by a second investigator who was blinded to the results obtained by the main investigator. Both intra- and interobserver variability are reported in terms of intraclass correlation coefficients and coefficients of variation (percentages). All results were considered significant with  $P$ -values  $< 0.05$ . Statistical analysis was performed using SPSS 26 (SPSS Inc., Chicago, IL, USA).

## Results

According to the pre-specified inclusion and exclusion criteria, the study population consisted of 183 patients [age  $66 \pm 12$  years, male 130 (71%)]. Baseline characteristics of the population are listed in [Table 1](#). Risk factors more represented were overweight and obesity (mean body mass index  $26.9 \pm 3.9$ ), followed by hypertension (60%) and dyslipidaemia (50%). High-sensitivity Troponin T median range values were  $921 \pm 3741$  pg/mL, and GRACE risk score was  $112 \pm 27$ . Most of patients were diagnosed with non-ST-segment elevation myocardial infarction (NSTEMI) (86%), while the remaining patients presented with unstable angina. Culprit vessel was more frequently represented by LAD and Cx and less by RCA (38.5%, 39.6%, and 21.4%, respectively). The majority of patients had a preserved LVEF ( $54 \pm 9\%$ ) and normal tricuspid annular plane systolic excursion values ([Table 2](#)). [Table 3](#) showed the differences of WMSI and GLS/TLS values according to the severity of CAD (1-, 2-, and 3-vessel disease).

Both WMSI and GLS values worsened in patients with multivessel disease. A significant difference of WMSI was noted for 3-vessel vs. 1-vessel CAD, except for WMSI-LAD ( $P$ -value 0.076). There was a statistically significant difference of TLS-LAD, TLS-RCA and TLS-Cx values ( $P$ -value  $< 0.001$ ) both in 3-vessel vs. 1-vessel and in 2-vessel vs. 1-vessel disease. We also found a significant difference of TLS-RCA values in 3-vessel vs. 2-vessel disease. [Table 4](#) showed changes of WMSI and TLS with respect to the territorial distribution of each diseased coronary artery, both when the vessel was significantly stenotic and when it represented the culprit vessel. We found a statistically significant difference of WMSI-LAD, WMSI-CX, and WMSI-RCA of myocardial segments with underlying CAD compared to normal vessels. However, this statistical difference was not reported when RCA represented the culprit vessels. Changes of TLS-LAD, TLS-CX, and TLS-RCA were statistically significant both when the territorial tributary artery was severely stenotic and when the artery represented the culprit vessel vs. normal vessels. [Figure 2](#) shows the discriminatory strength of the TSL in relation to the vessel culprit. [Figure 3](#) and [Table 5](#) showed the incremental value of WMSI + TLS in predicting the culprit vessel when compared with the model including WMSI alone for each vessel (for LAD,  $P = 0.001$ ; for CX,  $P < 0.001$ ; and for RCA,  $P = 0.019$ ).

## Reproducibility

A total of 30 patients were randomly chosen for the inter- and intra-observer variability analysis. Intraobserver and interobserver intraclass correlation agreement for GLS, TLS-LAD, TLS-RCA, and TLS-CX were 0.94, 0.89, 0.88, 0.89 and 0.97, 0.99, 0.99, 0.98, respectively ([Table 6](#)).

## Discussion

This study involving an NSTEMI-ACS population with no history of CAD demonstrated a number of important findings: (i) a direct correlation between WMSI, GLS and TLS values and the increasing number of diseased vessels; (ii) a direct correlation between regional WMSI and TLS with vessel-specific CAD findings; (iii) good accuracy of TLS in detecting the culprit vessel; and (iv) the incremental value of a model including WMSI + TLS compared to WMSI alone in detecting the culprit vessel.

Previous experimental studies have demonstrated the value of 2D STE in detecting CAD in NSTEMI patients. [Eek et al.](#)<sup>25</sup> demonstrated that GLS had higher predictive power than LVEF and WMSI to identify an acute coronary occlusion (ACO) in NSTEMI-ACS patients. They showed the correlation between the number of segments with reduced strain values and the presence of total occlusion. [Mghaieth Zghal et al.](#)<sup>26</sup> evaluated 70 NSTEMI patients and reported the utility of TLS for prediction of ACO. [Atici et al.](#)<sup>27</sup> reported GLS and TLS values were significantly different between CAD patients and the control group. They showed that an increase in severity of CAD resulted in a decrease of TLS-LAD, TLS-CX, and TLS-RCA values in NSTEMI patients.

In our study, we corroborate the above-mentioned results and demonstrated that GLS and TLS values show a significant difference ( $P$ -value  $< 0.001$ ) between 3- and 2-vessel CAD compared to

**Table 1** Baseline characteristics of study population

Clinical characteristics	n = 183
Age (years)	66 ± 12
Female, n (%)	53 (29)
BSA, m <sup>2</sup>	1.9 ± 0.2
BMI, kg/m <sup>2</sup>	26.9 ± 3.9
Smoking, n (%)	74 (41)
Hypertension, n (%)	109 (60)
Diabetes, n (%)	34 (19)
Dyslipidaemia, n (%)	91 (50)
Family history of CAD, n (%)	56 (31)
Cardiac arrest, n (%)	1 (0.5)
ST deviation, n (%)	96 (53)
LBBB, n (%)	11 (6)
RBBB, n (%)	6 (3)
Hs-troponin I, ng/L	921 ± 3741
Killip, n (%)	
0	1 (0.5)
1	172 (94.5)
2	3 (1.6)
3	6 (3.4)
GRACE	112 ± 27
NSTEMI, n (%)	156 (86)
Unstable angina, n (%)	26 (14)
Culprit vessel, n (%)	
Left main	1 (0.5)
Left anterior descending artery	70 (38.5)
Circumflex artery	72 (39.6)
Right coronary artery	39 (21.4)

BMI, body mass index; BSA, body surface area; CAD, coronary artery disease; GRACE, Global Registry of Acute Coronary Events; NSTEMI, non-ST-segment elevation myocardial infarction.

**Table 2** Echocardiographic parameters of study population

Echocardiographic parameters	
LVEDVi (mL/m <sup>2</sup> )	56 ± 16
LVESVi (mL/m <sup>2</sup> )	27 ± 13
LVEF (%)	54 ± 9
LV mass index (g/m <sup>2</sup> )	31 ± 9
E/A	0.95 ± 0.43
E/e'	10.9 ± 5.6
LAVI (mL/m <sup>2</sup> )	30.7 ± 9.4
TAPSE (mm)	21.8 ± 3.7
S' (cm/s)	12.2 ± 2.4
PAPs (mmHg)	29.4 ± 7.8

LAVI, left atrial volume index; LVEDVi, left ventricular end-diastolic volume index; LVESVi, left ventricular end-systolic volume index; PAPs, pulmonary artery pressure; TAPSE, tricuspid annulus plane systolic excursion.

**Table 3** WMSI and STE in multivessel CAD

	1 vessel (n = 98)	2 vessels (n = 49)	3 vessels (n = 35)	P-value
WMSI	1.2 ± 0.3	1.3 ± 0.4	1.5 ± 0.5*	0.004
WMSI-LAD	1.2 ± 0.4	1.3 ± 0.5	1.4 ± 0.5	0.076
WMSI-RCA	1.3 ± 0.4	1.4 ± 0.5	1.5 ± 0.6*	0.020
WMSI-CX	1.3 ± 0.4	1.4 ± 0.5	1.5 ± 0.6*	0.035
GLS	-16.3 ± 2.1	-14.9 ± 2.9*	-13.9 ± 3.3*	<0.001
TLS-LAD	-16.2 ± 2.9	-14.6 ± 3.5*	-13.9 ± 3.7*	<0.001
TLS-RCA	-16.7 ± 2.6	-15.3 ± 3.0*	-13.7 ± 3.1*†	<0.001
TLS-CX	-15.5 ± 3.0	-14 ± 3.2*	-12.4 ± 3.8*	<0.001

CX, circumflex coronary artery; GLS, global longitudinal strain; LAD, left anterior descending coronary artery; RCA, right coronary artery; TLS-LAD, territorial longitudinal strain in LAD territory; WMSI-LAD, wall-motion score index in the LAD territory.

\*P < 0.05 vs. 1 vessel.

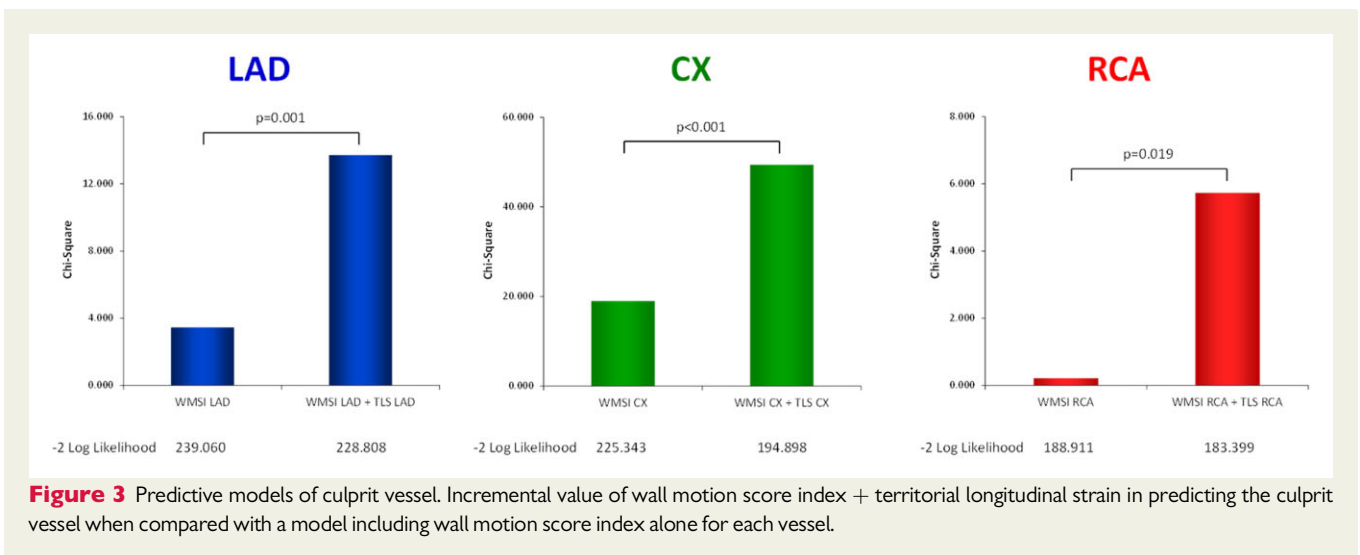
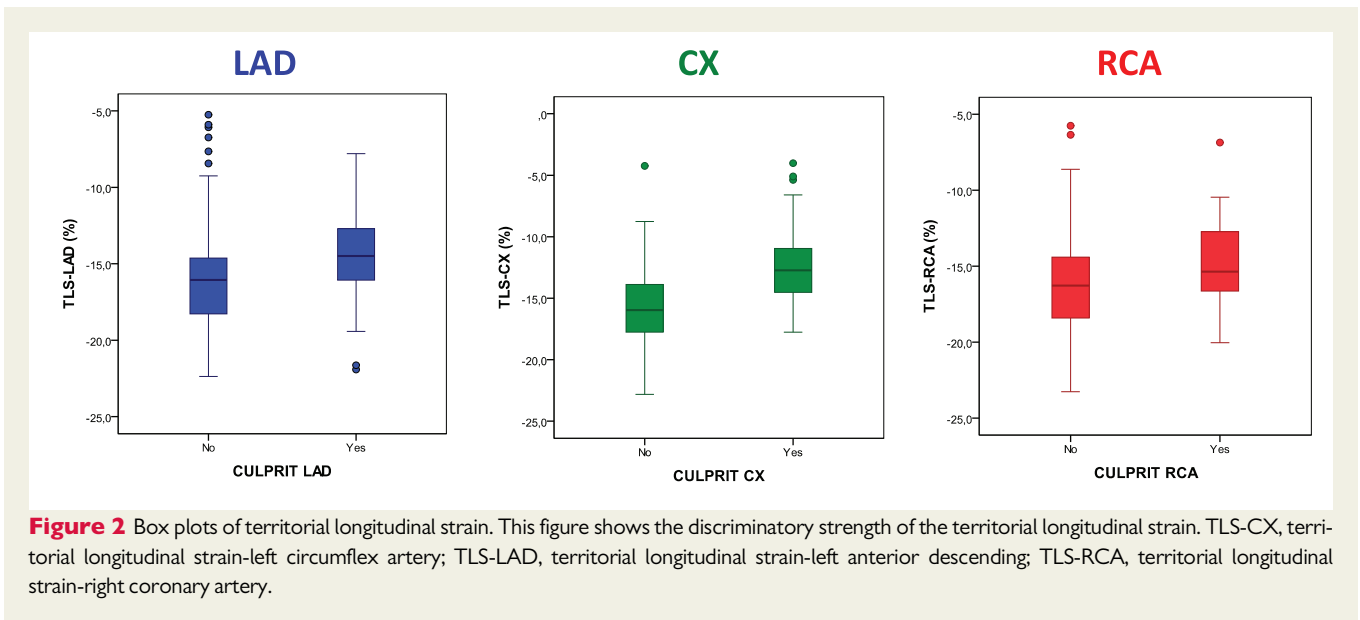
†P < 0.05 vs. 2 vessels.

1-vessel CAD. Moreover, the same finding was obtained comparing TLS-RCA values between 3-vessel and 2-vessel CAD. On the other hand, WMSI values were consistent with the above findings only when comparing 3-vessel CAD to 1-vessel CAD. Only WMSI-LAD results were not significant in this case.

A novel point of our study was to correlate both regional WMSI and TLS with the corresponding vessel disease. As expected, analysing regional WMSI and TLS separately, both demonstrated a significant difference comparing patients with coronary artery stenosis >70% and those with normal vessels. Subsequently, we repeated the same analysis with the addition of evaluating the culprit vessel and its distribution territory. Only TLS values showed a significant difference, while regional WMSI was significant only for lesions involving the CX artery. Possible explanations for higher detection of TLS compared to regional WMSI can be hypothesized. During myocardial ischaemia, the function of sub-endocardial fibres is impaired, which occurs before EKG findings, symptom onset and WMSI changes. For this reason, we chose STE which is a non-invasive imaging technique that allows assessment of global and regional myocardial function.<sup>13,28</sup> GLS and TLS evaluate myocardial longitudinal fibres, which are the most susceptible to any disease process affecting the subendocardium, particularly ischaemia. Differently, WMSI evaluates radial fibre behaviour. Thus, it could be normal because during subendocardial ischaemia radial and circumferential fibres are usually not involved or they may have compensatory hyperkinesis.<sup>29,30</sup>

Mghaieth Zghal et al.<sup>26</sup> showed in their study that TLS predicted the culprit vessel and in particular its acute occlusion. TLS determined the culprit artery in 74% of cases and TLS value >-9.2% predicted ACO with 85% sensitivity and specificity. However, the authors evaluated a small population (70 patients), and did not exclude known CAD. Moreover, they used median values of TLS instead of considering separate TLS values of regional myocardium for each coronary artery. Eventually, we used a regression model to enhance our results and demonstrated that the model including WMSI and TLS represents a more powerful diagnostic method to identify culprit vessel as compared to WMSI alone.

Our outcomes have important clinical implications because an early and accurate evaluation of the severity of CAD with TLS may



**Table 4** Coronary-specific WMSI and TLS and culprit vessel

	LAD no stenosis (n = 56)	LAD stenosis no culprit (n = 56)	LAD stenosis culprit (n = 70)	P-value
WMSI-LAD	1.1 ± 0.3	1.3 ± 0.5*	1.4 ± 0.5*	0.005
TLS-LAD	-17.3 ± 2.6	-14.8 ± 3.5*	-14.2 ± 3.1*	<0.001
	CX no stenosis (n = 89)	CX stenosis no culprit (n = 23)	CX stenosis culprit (n = 70)	P-value
WMSI-CX	1.2 ± 0.4	1.2 ± 0.4	1.6 ± 0.6*†	<0.001
TLS-CX	-16.2 ± 2.8	-14.1 ± 3.4*	-12.4 ± 3.0*†	<0.001
	RCA no stenosis (n = 103)	RCA stenosis no culprit (n = 40)	RCA stenosis culprit (n = 39)	P-value
WMSI-RCA	1.2 ± 0.4	1.6 ± 0.6*	1.4 ± 0.4	<0.001
TLS-RCA	-16.8 ± 2.6	-14.0 ± 3.3*	-14.8 ± 2.7*	<0.001

CX, circumflex coronary artery; LAD, left anterior descending coronary artery; RCA, right coronary artery; TLS-LAD, territorial longitudinal strain in LAD territory; WMSI-LAD, wall-motion score index in the LAD territory.

\*Versus no stenosis.

†Versus stenosis no culprit.



**Table 5** Univariate and multivariate logistic regression analysis for the identification of independent variables predicting the culprit vessel

	Univariate OR	P-value	Multivariate OR	P-value
<b>LAD culprit</b>				
WMSI-LAD	1.835(0.966–3.486)	0.064	0.948(0.435–2.062)	0.892
TLS-LAD	1.194(1.081–1.318)	<0.001	1.198(1.068–1.345)	0.002
<b>CX culprit</b>				
WMSI-CX	4.167(2.098–8.279)	<0.001	1.768(0.806–3.875)	0.155
TLS-CX	1.453(1.278–1.652)	<0.001	1.405(1.226–1.611)	<0.001
<b>RCA culprit</b>				
WMSI-RCA	1.190(0.575–2.462)	0.099	0.710(0.299–1.685)	0.438
TLS-RCA	1.141(1.017–1.281)	0.025	1.175(1.024–1.347)	0.021

**Table 6** Intra-observer and inter-observer variability analysis

	Intra-observer		Inter-observer	
	ICC	CV	ICC	CV
GLS	0.944	1.4%	0.975	1.3%
TLS-LAD	0.893	1.2%	0.999	0.4%
TLS-RCA	0.889	1.2%	0.995	0.5%
TLS-CX	0.896	1.2%	0.988	0.4%

offer insightful information about the clinical risk of the patient, and subsequently this could be useful to target initial management. Therefore, from a practical perspective, both wall motion assessment and STE may be useful and easy techniques during the initial evaluation of NSTEMI-ACS patients.

## Limitations

The present study has numerous limitations. First, the population was relatively small. However, we selected only patients without pre-existing systolic dysfunction and ischaemic history to get TLS and WMSI for the acute presentation. Second, the retrospective nature of our study limits the clinical application. Third, we studied culprit vessel without taking into account the possible ACO of the culprit artery, which would benefit from early reperfusion therapy. Fourth, although we collected clinical parameters such as Killip score elements, the limited number of enrolled patients did not allow us to consider loading conditions and inotropic changes that may influence LV systolic function in statistical analyses. Fifth, the number of involved coronary arteries is not equally distributed and this may explain why WMSI-CX showed a better correlation with the culprit vessel as compared to WMSI-LAD and RCA. Sixth, we employed a simplified model of TLS in respect to relative coronary artery distribution without taking into account the variability derived from coronary dominance. Therefore, it is likely that in 20–25% of cases TLS of the inferior wall may be inaccurate. Seventh, we performed a multiple assessment of coronary-specific TLS showing the different values in case of absence of

disease, presence of significant disease non-culprit and presence of significant disease culprit, a comprehensive evaluation of multi-vessel patients need a larger study population. Eighth, echocardiography is a user-dependent technique by definition even though we provided a double analysis by two independent readers. Moreover, strain cut-off values should be considered carefully because of the lack of software standards for optimal cut-offs and, hence, larger multicentre and multivendor studies are warranted.

## Conclusion

Coronary-specific quantification of myocardial deformation by strain echocardiography allows an accurate identification of the culprit vessel in NSTEMI-ACS patients. In addition to WMSI, TLS may be considered as part of routine echocardiography for better clinical assessment in this subset of patients.

## Lead author biography



Prof. Andrea Igoen Guaricci earned his MD from University of Bologna in Italy. He completed his cardiovascular medicine residency from University of Bari followed by cardiology and radiology fellowships at the University of Pittsburgh and Weill Medical College Cornell University, New York. He joined the Italian Society of Cardiology where he served as

Chairman of the Working Group of Cardiac Imaging. Prof. Guaricci's work focuses on quality of diagnosis by echocardiography, cardiac MR and cardiac CT, and care and clinical outcomes of cardiomyopathies and heart failure patients.

## Data Availability

The data underlying this article will be shared on reasonable request to the corresponding author.

**Conflict of interest:** none declared.

## References

- Roger VL, Weston SA, Gerber Y, Killian JM, Dunlay SM, Jaffe AS, Bell MR, Kors J, Yawn BP, Jacobsen SJ. Trends in incidence, severity, and outcome of hospitalized myocardial infarction. *Circulation* 2010;**121**:863–869.
- Benjamin EJ, Virani SS, Callaway CW, Chamberlain AM, Chang AR, Cheng S, Chiuve SE, Cushman M, Delling FN, Deo R, de Ferranti SD, Ferguson JF, Fornage M, Gillespie C, Isasi CR, Jiménez MC, Jordan LC, Judd SE, Lackland D, Lichtman JH, Lisabeth L, Liu S, Longenecker CT, Lutsey PL, Mackey JS, Matchar DB, Matsushita K, Mussolino ME, Nasir K, O'Flaherty M, Palaniappan LP, Pandey A, Pandey DK, Reeves MJ, Ritchey MD, Rodriguez CJ, Roth GA, Rosamond WD, Sampson UKA, Satou GM, Shah SH, Spartano NL, Tirschwell DL, Tsao CW, Voeks JH, Willey JZ, Wilkins JT, Wu JH, Alger HM, Wong SS, Muntner P; American Heart Association Council on Epidemiology and Prevention Statistics Committee and Stroke Statistics Subcommittee. Heart disease and stroke statistics—2018 update: a report from the American Heart Association. *Circulation* 2018;**137**:e67–e492.
- Boeddinghaus J, Nestelberger T, Twerenbold R, Neumann JT, Lindahl B, Giannitsis E, Sörensen NA, Badertscher P, Jann JE, Wussler D, Puelacher C, Rubini Giménez M, Wildi K, Strelbel I, Du Fay de Lavallaz J, Selman F, Sabti Z, Kozuharov N, Potlukova E, Rentsch K, Miró Ó, Martín-Sánchez FJ, Morawiec B, Parenica J, Lohmann J, Kloos W, Buser A, Geigy N, Keller DI, Osswald S, Reichlin T, Westermann D, Blankenberg S, Mueller C; APACE, BACC, and TRAPID-AMI Investigators. Impact of age on the performance of the ESC 0/1h algorithms for early diagnosis of myocardial infarction. *Eur Heart J* 2018;**39**:3780–3794.
- Collet JP, Thiele H, Barbato E, Barthélémy O, Bauersachs J, Bhatt DL, Dendale P, Dorobantu M, Edvardsen T, Folliquet T, Gale CP, Gilard M, Jobs A, Jüni P, Lambrinou E, Lewis BS, Mehilli J, Meliga E, Merkely B, Mueller C, Roffi M, Rutten FH, Sibbing D, Siontis GCM. ESC Scientific Document Group. 2020 ESC Guidelines for the management of acute coronary syndromes in patients presenting without persistent ST-segment elevation. *Eur Heart J* 2021 Apr 7;**42**(14):1289–1367.
- Guaricci AI, Pontone G, Fusini L, De Luca M, Cafarelli FP, Guglielmo M, Baggiano A, Beltrama V, Muscogiuri G, Mushtaq S, Conte E, Guglielmi G, Andreini D, Brunetti ND, Di Biase M, Bartorelli AL, Pepi M. Additional value of inflammatory biomarkers and carotid artery disease in prediction of significant coronary artery disease as assessed by coronary computed tomography angiography. *Eur Heart J Cardiovasc Imaging* 2017;**18**:1049–1056.
- Muscogiuri G, Chiesa N, Trotta M, Gatti M, Palmisano V, Dell'Aversana S, Baessato F, Cavaliere A, Cicala G, Loffreno A, Rizzon G, Guglielmo M, Baggiano A, Fusini L, Saba L, Andreini D, Pepi M, Rabbat MG, Guaricci AI, De Cecco CN, Colombo G, Pontone G. Performance of a deep learning algorithm for the evaluation of CAD-RADS classification with CCTA. *Atherosclerosis* 2020;**294**:25–32.
- Pontone G, Guaricci AI, Andreini D, Ferro G, Guglielmo M, Baggiano A, Fusini L, Muscogiuri G, Lorenzoni V, Mushtaq S, Conte E, Annoni A, Formenti A, Mancini ME, Carità P, Verdecchia M, Pica S, Fazzari F, Cosentino N, Marenzi G, Rabbat MG, Agostoni P, Bartorelli AL, Pepi M, Masci PG. Prognostic stratification of patients with ST-segment-elevation myocardial infarction (PROSPECT): a cardiac magnetic resonance study. *Circ Cardiovasc Imaging* 2017;**10**:e006428.
- Pontone G, Andreini D, Bertella E, Loguerio M, Guglielmo M, Baggiano A, Aquaro GD, Mushtaq S, Salerni S, Gripari P, Rossi C, Segurini C, Conte E, Beltrama V, Giovannardi M, Veglia F, Guaricci AI, Bartorelli AL, Agostoni P, Pepi M, Masci PG. Prognostic value of dipyridamole stress cardiac magnetic resonance in patients with known or suspected coronary artery disease: a mid-term follow-up study. *Eur Radiol* 2016;**26**:2155–2165.
- Gaibazzi N, Porter T, Lorenzoni V, Pontone G, De Santis D, De Rosa A, Guaricci AI. Effect of coronary revascularization on the prognostic value of stress myocardial contrast wall motion and perfusion imaging. *J Am Heart Assoc* 2017;**6**:e006202. <https://doi.org/10.1161/JAHA.117.006202>.
- Chandraratna PAN, Mohar DS, Sidarous PF, Brar P, Miller J, Shah N, Kadis J, Ali A, Mohar P. Evaluation of non-ST segment elevation acute chest pain syndromes with a novel low-profile continuous imaging ultrasound transducer. *Echocardiography* 2012;**29**:895–899.
- Fleischmann KE, Lee RT, Come PC, Goldman L, Cook EF, Weissman MA, Johnson PA, Lee TH. Impact of valvular regurgitation and ventricular dysfunction on long-term survival in patients with chest pain. *Am J Cardiol* 1997;**80**:1266–1272.
- Roffi M, Patrono C, Collet J-P, Mueller C, Valgimigli M, Andreotti F, Bax JJ, Borger MA, Brotons C, Chew DP, Gencer B, Hasenfuss G, Kjeldsen K, Lancellotti P, Landmesser U, Mehilli J, Mukherjee D, Storey RF, Windecker S; ESC Scientific Document Group. 2015 ESC Guidelines for the management of acute coronary syndromes in patients presenting without persistent ST-segment elevation: task Force for the Management of Acute Coronary Syndromes in Patients Presenting without Persistent ST-Segment Elevation of the European Society of Cardiology (ESC). *Eur Heart J* 2016;**37**:267–315.
- Amundsen BH, Helle-Valle T, Edvardsen T, Torp H, Crosby J, Lyseggen E, Støylen A, Ihlen H, Lima JAC, Smiseth OA, Slørdahl SA. Noninvasive myocardial strain measurement by speckle tracking echocardiography: validation against sonomicrometry and tagged magnetic resonance imaging. *J Am Coll Cardiol* 2006;**47**:789–793.
- Urheim S, Edvardsen T, Torp H, Angelsen B, Smiseth OA. Myocardial strain by Doppler echocardiography. Validation of a new method to quantify regional myocardial function. *Circulation* 2000;**102**:1158–1164.
- Edvardsen T, Skulstad H, Aakhus S, Urheim S, Ihlen H. Regional myocardial systolic function during acute myocardial ischemia assessed by strain Doppler echocardiography. *J Am Coll Cardiol* 2001;**37**:726–730.
- Grenne B, Eek C, Sjøli B, Dahlslett T, Uchto M, Hol PK, Skulstad H, Smiseth OA, Edvardsen T, Brunvand H. Acute coronary occlusion in non-ST-elevation acute coronary syndrome: outcome and early identification by strain echocardiography. *Heart* 2010;**96**:1550–1556.
- Favot M, Courage C, Ehrman R, Khaït L, Levy P. Strain echocardiography in acute cardiovascular diseases. *West J Emerg Med* 2016;**17**:54–60.
- Cai Q, Ahmad M. Left ventricular dyssynchrony by three-dimensional echocardiography: current understanding and potential future clinical applications. *Echocardiography* 2015;**32**:1299–1306.
- Granger CB, Goldberg RJ, Dabbous O, Pieper KS, Eagle KA, Cannon CP, Van De Werf F, Avezum A, Goodman SG, Flather MD, Fox KAA; Global Registry of Acute Coronary Events Investigators. Predictors of hospital mortality in the global registry of acute coronary events. *Arch Intern Med* 2003;**163**:2345–2353.
- Jafari FY. Devereux formula for left ventricle mass—be careful to use the right units of measurements. *J Am Soc Echocardiogr* 2007;**20**:783.
- Lang RM, Badano LP, Mor-Avi V, Afilalo J, Armstrong A, Ernande L, Flachskampf FA, Foster E, Goldstein SA, Kuznetsova T, Lancellotti P, Muraru D, Picard MH, Rietzschel ER, Rudski L, Spencer KT, Tsang W, Voigt J-U. Recommendations for cardiac chamber quantification by echocardiography in adults: an update from the American Society of Echocardiography and the European Association of Cardiovascular Imaging. *J Am Soc Echocardiogr* 2015;**28**:1–39.e14.
- Lebeau R, Serri K, Lorenzo MD, Sauvé C, Le VHV, Soulières V, El-Rayes M, Pagé M, Zaïani C, Garot J, Poulin F. Assessment of LVEF using a new 16-segment wall motion score in echocardiography. *Echo Res Pract* 2018;**5**:63–69.
- Sarvari SI, Haugaa KH, Zahid W, Bendz B, Aakhus S, Aaberge L, Edvardsen T. Layer-specific quantification of myocardial deformation by strain echocardiography may reveal significant CAD in patients with non-ST-segment elevation acute coronary syndrome. *JACC Cardiovasc Imaging* 2013;**6**:535–544.
- Cerqueira MD, Weissman NJ, Dilsizian V, Jacobs AK, Kaul S, Laskey WK, Pennell DJ, Rumberger JA, Ryan T, Verani MS; American Heart Association Writing Group on Myocardial Segmentation and Registration for Cardiac Imaging. Standardized myocardial segmentation and nomenclature for tomographic imaging of the heart. A statement for healthcare professionals from the Cardiac Imaging Committee of the Council on Clinical Cardiology of the American Heart Association. *Circulation* 2002;**105**:539–542.
- Eek C, Grenne B, Brunvand H, Aakhus S, Endresen K, Smiseth OA, Edvardsen T, Skulstad H. Strain echocardiography predicts acute coronary occlusion in patients with non-ST-segment elevation acute coronary syndrome. *Eur J Echocardiogr* 2010;**11**:501–508.
- Mghaieth Zghal F, Boudiche S, Houes H, Fathallah I, Ouaghlani K, Bonkano A, Ayari J, Rekiq B, Ben Halima M, Ouali S, Mourali MS. Diagnostic and prognostic value of 2D-strain in non-ST elevation myocardial infarction. *Tunis Med* 2020;**98**:70–79.
- Atici A, Barman HA, Durmaz E, Demir K, Cakmak R, Tugrul S, Elitok A, Onur İ, Sahin İ, Oncul A. Predictive value of global and territorial longitudinal strain imaging in detecting significant coronary artery disease in patients with myocardial infarction without persistent ST-segment elevation. *Echocardiography* 2019;**36**:512–520.
- Winter R, Jussila R, Nowak J, Brodin LA. Speckle tracking echocardiography is a sensitive tool for the detection of myocardial ischemia: a pilot study from the catheterization laboratory during percutaneous coronary intervention. *J Am Soc Echocardiogr* 2007;**20**:974–981.
- Fent GJ, Garg P, Foley JR, Dobson LE, Musa TA, Erhayiem B, Greenwood JP, Plein S, Swoboda PP. The utility of global longitudinal strain in the identification of prior myocardial infarction in patients with preserved left ventricular ejection fraction. *Int J Cardiovasc Imaging* 2017;**33**:1561–1569.
- Sengupta PP, Krishnamoorthy VK, Korinek J, Narula J, Vannan MA, Lester SJ, Tajik JA, Seward JB, Khandheria BK, Belohlavek M. Left ventricular form and function revisited: applied translational science to cardiovascular ultrasound imaging. *J Am Soc Echocardiogr* 2007;**20**:539–551.