







Review

Socket Shield Technique to Improve the Outcomes of Immediate Implant: A Systematic Review and Meta-Analysis

Antonio Scarano ^{1,*}, Mariastella Di Carmine ^{1,†}, Faez Saleh Al-Hamed ^{2,†}, Ahmad G. A. Khater ^{3,‡}, Sergio Alexandre Gehrke ^{4,5,†}, Sergio Rexhep Tari ^{1,†}, Lucia Leo ^{1,†}, Francesco Inchingolo ^{6,‡} and Felice Lorusso ¹

¹ Department of Innovative Technologies in Medicine and Dentistry, University of Chieti–Pescara, 66100 Chieti, Italy; sergiotari@yahoo.it (S.R.T.); drlucialeo@hotmail.com (L.L.); drlorussofelice@gmail.com (F.L.)

² College of Dental Medicine, QU Health, Qatar University, Doha 2713, Qatar

³ Health Affairs Directorate, Egyptian Ministry of Health and Population, Banisuif 62511, Egypt; ahmed.g.a.khater@gmail.com

⁴ Department of Research, Bioface/PgO/UCAM, Calle Cuareim 1483, Montevideo 11100, Uruguay; sergio.gehrke@hotmail.com

⁵ Department of Biotechnology, Universidad Católica de Murcia (UCAM), 30107 Murcia, Spain

⁶ Department of Interdisciplinary Medicine, University of Bari “Aldo Moro”, 70121 Bari, Italy

* Correspondence: ascarano@unich.it; Tel.: +39-0871-3554084; Fax: +39-0871-3554099

† These authors contributed equally to this work as co-first Authors.

‡ These authors contributed equally to this work as co-last Authors.

Abstract: Background: The socket shield technique (SST) could address the challenges in immediate implant placement by minimizing post-extraction bone resorption while maintaining soft tissue levels. This study aimed to summarize the available evidence and systematically assess the effectiveness of SST immediate implant placement regarding all outcomes (bone loss, esthetics, implant stability, probing depth, complications, and survival rate). Methods: We searched seven electronic databases through April 2023 to identify randomized clinical trials that assessed the effect of immediate implant placed with SST (test group) versus other implant placement protocols without SST. The risk of bias was assessed using Cochrane’s randomized trial quality assessment Tool (RoB 2.0). Random-effects meta-analysis was conducted, with mean difference and 95% confidence intervals (MD, 95% CI) as effect estimates. We used the GRADE approach to assess the certainty of evidence. Results: Twelve RCTs, involving 414 immediate implants, placed in 398 patients, were included. Meta-analyses revealed that the immediate implants placed with SST had a statistically significant decrease in horizontal (MD = -0.28 , 95% CI [-0.37 , -0.19], $p < 0.0001$), vertical (MD = -0.85 , 95% CI [-1.12 , -0.58], $p < 0.0001$), and crestal (MD = -0.35 , 95% CI [-0.56 , -0.13], $p = 0.002$) bone loss, as well as probing depth (MD = -0.64 , 95% CI [-0.99 , -0.29], $p = 0.0003$). Additionally, SST had a significant increase in implant stability (MD = 3.46 , 95% CI [1.22 , 5.69], $p = 0.002$) and pink esthetic score (MD = 1.60 , 95% CI [0.90 , 2.30], $p < 0.0001$). Only two studies reported shield exposure incidences in the SST group; however, all studies revealed no implant failure and a 100% survival rate. The evidence certainty was assessed as very low. Conclusions: Based on limited evidence, SST was more effective in minimizing bone resorption and improving implant stability and esthetic outcomes than conventional immediate implant placement. Still, SST could not be recommended as a routine clinical protocol due to the lack of a standardized surgical approach; thus, further high-quality RCTs are required to support this conclusion.

Keywords: dental implant; esthetic zone; evidence-based dentistry; immediate implant placement; immediate loading; partial extraction; socket shield; systematic review



Citation: Scarano, A.; Di Carmine, M.; Al-Hamed, F.S.; Khater, A.G.A.; Gehrke, S.A.; Tari, S.R.; Leo, L.; Inchingolo, F.; Lorusso, F. Socket Shield Technique to Improve the Outcomes of Immediate Implant: A Systematic Review and Meta-Analysis. *Prosthesis* **2023**, *5*, 509–526. <https://doi.org/10.3390/prosthesis5020035>

Academic Editors: Bruno Chrcanovic and Marco Cicciu

Received: 10 March 2023

Revised: 14 May 2023

Accepted: 15 May 2023

Published: 22 May 2023



Copyright: © 2023 by the authors. Licensee MDPI, Basel, Switzerland. This article is an open access article distributed under the terms and conditions of the Creative Commons Attribution (CC BY) license (<https://creativecommons.org/licenses/by/4.0/>).

1. Introduction

The implant-prosthetic rehabilitation of anterior edentulous areas remains challenging for clinicians due to the solid aesthetic consequences and high patient expectations [1–3]. Furthermore, post-extraction bone resorption makes placing implants in a proper prosthetic location more difficult. Pre-existing or acquired anatomical factors are frequently associated with bone deficits that are difficult to manage; for example, tooth agenesis is accompanied by under-dimensioning of the alveolar process, a tooth with traumatic avulsion can be associated with an alveolar process fracture, and inflammatory lesions and cysts can compromise the residual bone availability [4]. It is well documented that tooth extraction causes loss of vascularization from the periodontal ligament and failure to transmit the occlusal stresses to the bone, which are necessary for maintenance. As a result of the lack of functional stimulation and vascular supply (particularly Sharpey's fibers presented in bundle bone), such a tooth-dependent structure will undergo complete resorption [5]. As such, radiographic investigations revealed that the thickness of the vestibular cortex on the anterior teeth was highly reduced (rarely reaching 1 mm in the cervical area), ranging from 0.8 mm in the anterior teeth to 1.1 mm in the premolar sites, with an average thickness of 0.5 mm [6,7]. Consequently, the buccal bone in the anterior area (mainly made of BB) undergoes substantial resorption, which may sometimes result in the ridge shifting to the lingual/palatal position. As such, regeneration and ridge augmentation procedures are required for implant placement, according to biological and prosthetic guidelines; thus, anterior and premolar locations would require more bone grafting procedures (either before or during implant placement) than molar sites (69.7% and 45.9%, respectively). Socket preservation techniques (SST) have emerged in implant dentistry as a response to the need to reduce or compensate for bone resorption (e.g., guided bone regeneration (GBR), grafting, and tissue engineering techniques); however, these procedures require two surgeries, increasing their invasiveness, morbidity, length of rehabilitation time, and cost [8–10]. In order to minimize the alveolar crest constriction and shorten surgical and rehabilitation durations, immediate post-extraction implants have been recommended as a viable alternative. However, such an approach would be associated with a 0.78 mm vertical bone loss and a 1.07 mm horizontal loss in the first year of implantation; hence, it can only slow down physiological bone resorption, not prevent it [11]. The socket shield technique is a minimally invasive procedure that could reduce morbidity and surgical steps while effectively maintaining the alveolar ridge thickness by retaining the vestibular part of the root and preserving the vascularization from the periodontal ligament. In 2010, Hürzeler's study, "The socket shield technique: the proof of principle report", published the first actual proof of the principle behind the so-called socket shield technique, demonstrating that the retained root aids in the preservation of alveolar bone and does not compromise the implant osseointegration located in direct contact with the root [12]. However, clinical and histological studies had already established how the crowned root (whether endodontically treated or not) and intentionally retained roots could favor bone volume maintenance with low complications before Hürzeler's work [13–17]. Beyond the technical variants, the SS entails dissecting the crown and sectioning the root in a mesiodistal direction, removing the palatal fragment, including the apex, and leaving the vestibular portion in place. The fragment is trimmed to have a concave profile and a thickness of half the distance between the root canal and the buccal margin [18]. Gluckman et al. recommended lowering the fragment by 1 mm below the crest and creating a coronal bevel to facilitate the soft tissue thickening between the root and the prosthesis and to minimize complications, such as root exposure [19] (Figures 1 and 2). Although the current evidence about the effectiveness of SST in immediate implant placement is founded on several studies, such evidence is limited and un-robust since these studies are primarily observational (case reports and series) with short follow-up and no control group. Therefore, we performed a systematic review with meta-analysis to summarize the available evidence and systematically assess the effectiveness of SST immediate implant placement regarding all outcomes (bone loss, esthetics, implant stability, probing depth, complications, and survival rate), aiming to

answer the following question: does implant placement with SST improve immediate implant outcomes?

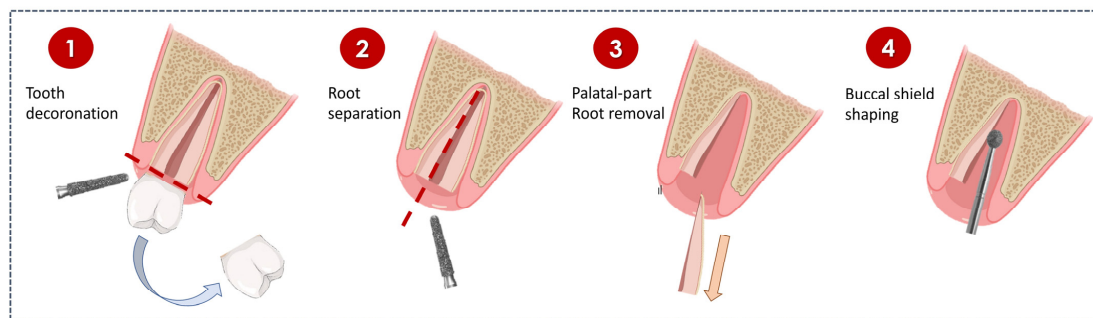


Figure 1. Surgical phases of the socket shield procedure. (Part 1) (1) Tooth decoronated with diamond bur. (2) Root division. (3) Removed palatal root. (4) Buccal shield shaping.

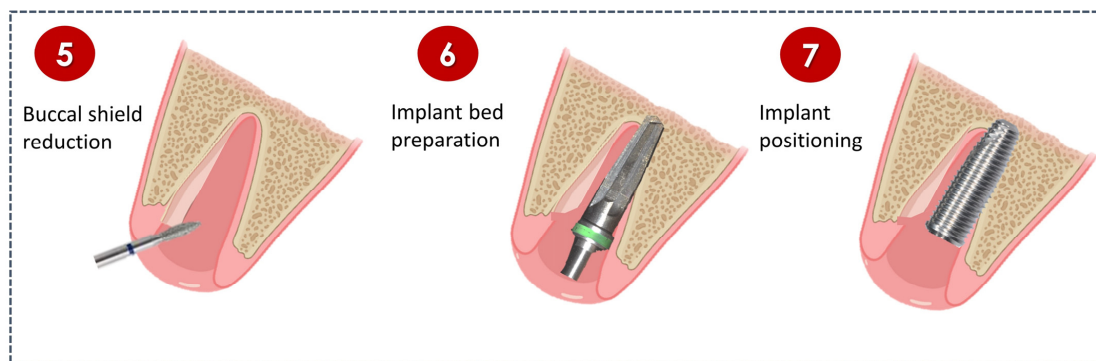


Figure 2. Surgical phases of the socket shield procedure. (Part 2). (5) Socket shield reduced to bone crest. (6) Implant bed preparation. (7) Implant placement.

2. Methods

The PRISMA statement [20] and the Cochrane Collaboration guidelines [21] were followed for reporting this systematic review and meta-analysis.

2.1. Eligibility Criteria

The following PICOS framework was used to structure our inclusion criteria:

- Population: Adult healthy patients (≥ 18 years) who indicated immediate dental implantation after tooth extraction in the aesthetic area (i.e., incisors, canines, or premolars).
- Intervention: Immediate dental implantation with SST.
- Comparison: Immediate dental implantation without SST.
- Outcomes:
 - Horizontal bone loss (i.e., changes in buccal bone width), determined by radiographs
 - Vertical bone loss (i.e., changes in buccal bone height), determined by radiographs
 - Implant stability, determined by measuring via implant stability quotient.
 - Esthetic evaluation, determined by pink esthetic score (PES).
 - Crestal bone loss (i.e., changes in marginal bone levels), determined by radiographs.
 - Probing depth, measured by a periodontal probe.
 - Post-operative complications
 - Rate of implant failure, determined by the number of implants removed
- Study design: Randomized clinical trial (RCT)

There were no limitations as to the comparisons or the follow-up period. However, we excluded non-randomized clinical trials, observational studies, animal studies, in vitro studies, case reports and series, reviews, book chapters, personal opinions, and non-English studies.

2.2. Information Sources and Search

Five electronic databases were searched: MEDLINE (via PubMed), EMBASE, CENTRAL (via Cochrane Library), and Web of Science. We further searched ProQuest and EBSCOhost for the grey literature, as well as clinicaltrials.gov and The WHO International Clinical Trials Registry Platform (ICTRP) for ongoing studies. The last search was updated on 4 April 2023, without language or time limitations. All reference lists of eligible studies and relevant reviews on the subject were scanned for possible additional studies. Details on the search strategy in all databases are summarized in Supplementary Table S1.

2.3. Study Selection

Paired independent authors (LL, FL) reviewed references based on titles and abstracts; then, eligible studies were collected as full texts and independently reviewed again by the same authors for inclusion. Any disagreement was resolved by discussion or, if necessary, involving the third author (AS).

2.4. Data Collection and Items

The following data were independently extracted by paired independent authors (AGAK, LL, FL): first author's name, year, country, age, sample size, gender (male-to-female ratio), study design and location, extracted teeth with extraction reason, population setting (medical status, smoking habit, periodontal phenotype), socket shield procedures, comparator procedures, implants' details (system, settings (length, diameter, torque), prosthetic), type of radiographic assessment, funding source, conflicts of interest, follow-ups, complications, dropouts, and results of included outcomes.

2.5. Risk of Bias in Individual Studies

Paired independent reviewers (AGAK, LL, FL) assessed the risk of bias of included studies using the revised version of Cochrane Risk of Bias Tool (2.0) for randomized trials [19,20]. Quality of studies was classified as "low risk", "some concerns", and "high risk" based on the risk of bias in the following domains: randomization process, deviations from the intended interventions, missing data on the outcome, measurement of the outcome, selection of the results reported. For the second domain, studies were assessed as "some concerns" if their personnel and participants were aware of the intervention; however, this judgment did not affect our overall judgment because of the impossibility of blinding operators and participants due to the intervention's nature. Likewise, any disagreement was resolved by discussion or involving the third author (AS).

2.6. Outcome Measure

For all reported follow-ups, the findings of all included outcomes were reported for both SST and control groups. In outcomes (horizontal, vertical, and crestal bone loss), the study effects were estimated using the baseline and follow-up data for each arm, representing the mean change from baseline to follow-up with their corresponding standard deviation (SD) per arm, as specified in the Cochrane Handbook [21]. For meta-analyses, we used the results of the final time point in the study to conduct a subgroup analysis considering the follow-up durations.

2.7. Data Synthesis

Continuous data outcomes (horizontal, vertical, and crestal bone loss, implant stability, esthetic evaluation, and probing depth) were estimated as mean difference (MD) and 95% confidence intervals (CIs). We conducted a random effects inverse variance model to pool the results (entered as mean and standard deviation per followed implants) using the Review Manager Software, version 5.4 (RevMan, Cochrane Collaboration). To avoid the unit-of-analysis error, since some RCTs showed clustering (i.e., multiple implants were placed in the same patient), we considered the patient as the statistical unit and the implants to be clustered within a patient by estimating the design effect (DE) for each trial [22]. The

design effect is $(1 + (M-1) \times ICC)$, where M is the average cluster size, and ICC is the intra-cluster correlation coefficient. As ICC for each included trial was not reported, we used an ICC of 0.3 based on records of clustering of clinical and radiographic periodontal outcomes within patients [23,24]. The statistical heterogeneity was assessed using the I^2 test, which represents the variability of the overall estimate based on the variability between studies ($I^2 = 25\%$: low; $I^2 = 50\%$: moderate; $I^2 = 75\%$: high). We conducted sensitivity analyses to assess the findings' robustness by comparing outcomes after different follow-up periods.

2.8. Certainty Assessment

The cumulative evidence's certainty was evaluated according to the Grading of Recommendations Assessment, Development, and Evaluation (GRADE) approach using the GRADEpro online tool [22]. The strength of the evidence was graded as "high", "moderate", "low", or "very low" based on the following domains: limitations in the study design, inconsistency, indirectness, imprecision, and publication bias. The Summary of Findings (SoF) table presents the grading and summary estimates. Given the limited number of studies on outcomes (i.e., <10 studies), no additional assessment of publication bias or small study (e.g., funnel plot or Egger test) was performed due to limited power to detect publication bias.

3. Results

3.1. Study Selection

The electronic search process yielded ($n = 8686$) entries, of which ($n = 3599$) were subject to title/abstract screening after removing duplicates and excluding irrelevant records. Consequently, the remaining ($n = 60$) records and references obtained from manual searches ($n = 17$) resulted in 77 articles being included in the full-text screening. From the 77 studies subjected to full-text review, 12 RCTs met the inclusion criteria, and 65 were excluded for reasons described in Supplementary Table S2 (Figure 3).

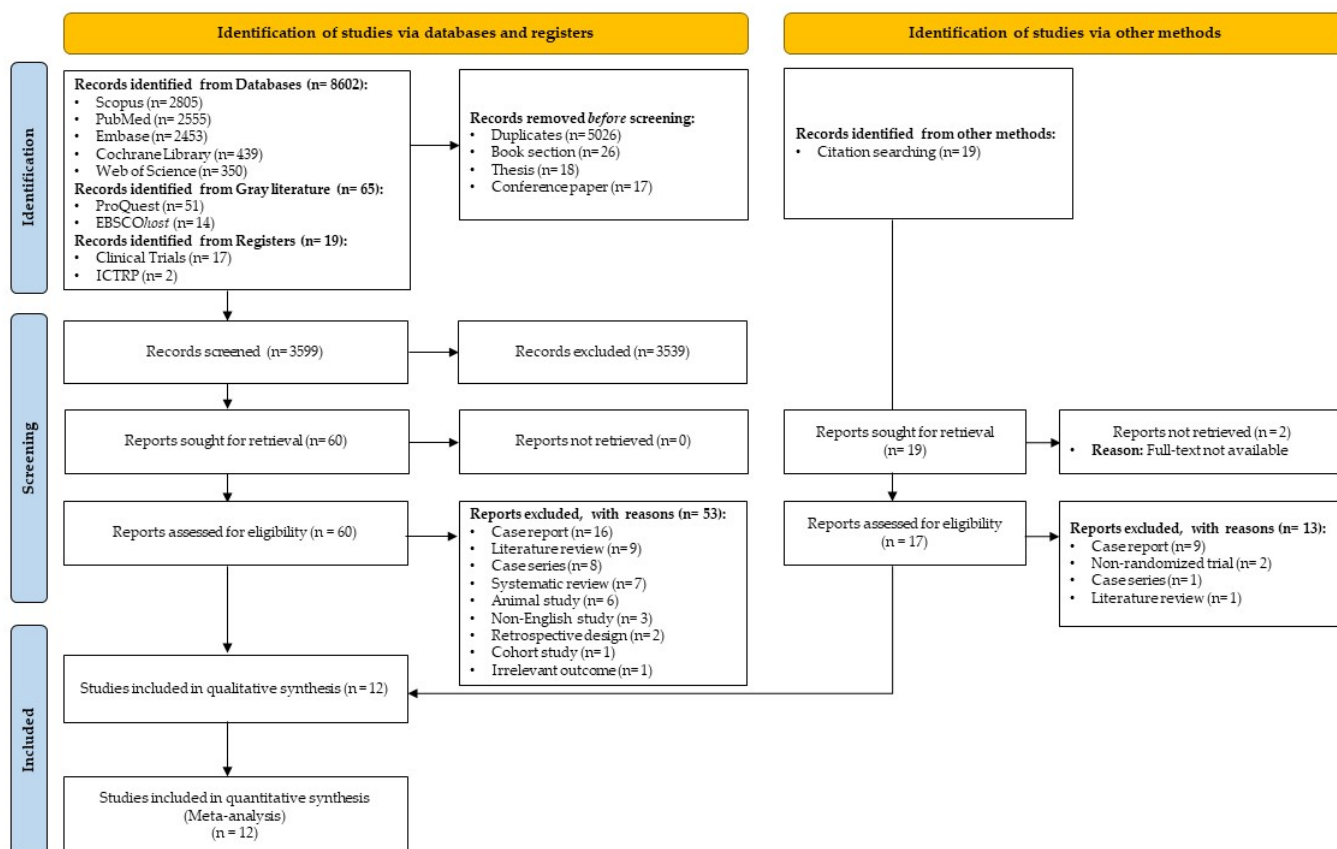


Figure 3. PRISMA flow diagram.

3.2. Study Characteristics

Twelve RCTs involved 398 patients (both genders) with a mean age of about 33.74 years, who received 414 immediate dental implants [23–34]. All RCTs were conducted in a university clinic, with six studies in Egypt, three in India, and one in each Iraq, Italy, and China, and the follow-up periods ranged from three months to three years. All studies were individual-randomized clinical trials, except the studies by Abd-Elrahman et al. [27] and Kumar et al. [32], which were cluster-randomized clinical trials (with the patient as a cluster, i.e., more than one dental implant per patient); however, all RCTs used a parallel-arm design, except for Abdel-Raheim et al. [26], who used a split-mouth approach.

Surgeries were conducted in the maxillary esthetic area in all RCTs, except for Hana et al. [28] and Sun et al. [29], wherein the surgeries were performed in the maxillary and mandibular areas; similarly, the surgical site was anterior teeth in all studies, except for Atef et al. [31] and Abdullah et al. [34], whose surgery sites involved anterior and premolar teeth.

Studies showed little variations in socket-shield procedures regarding tooth decoration, separation method, and level of buccal shield to crestal bone. However, the gap between the implant and the root remained empty in all studies, except for three RCTs, in which two filled the gap with grafting material [24,29] and one with collagen plug [31].

The comparator was atraumatic tooth extraction using periostomes and forceps to preserve socket walls and alveolar bone, followed by preparing a minimally invasive flap or a flapless approach for immediate implant placement; then, the buccal gap was filled with grafting materials in six studies, while the others remained without grafting.

In all studies, a provisional restoration was placed immediately after surgery in both groups, except for four studies [23,30–32], which delayed prosthesis loading to four months after surgery. Table 1 presents details of the main characteristics of the included studies.

3.3. Risk of Bias within Studies

Overall, seven studies were assessed as having a high risk of bias [23,25–28,30,32], three studies as having some concerns risk of bias [24,29,34], and two studies as having a low risk of bias [31,33]. Six studies (50%) did not report information about allocation concealment, raising some concerns of bias. Additionally, six studies (50%) also raised some concerns of bias, since they did not report information about the blinding of outcome assessors. Furthermore, in all studies (except Atef et al. [31] and Santhanakrishnan et al. [33]), we could not access any protocols to compare them with the reported results, raising some concerns of bias. Figure 4 summarizes the risk of bias assessment within and across the included studies.

3.4. Results of Individual Studies

The included studies assessed the effectiveness of SST in immediate implant placement outcomes across follow-up duration, ranging from three months to three years. Supplementary Table S3 summarizes the results of included outcomes during all follow-ups.

3.5. Results of Syntheses

3.5.1. Horizontal Bone Loss (i.e., Changes in Buccal Bone Width)

Eight RCTs involved 284 immediate implants placed in 268 patients with follow-up periods ranging from four months to one year. Immediate implants placed using SST had a statistically significant decrease in the amount of horizontal bone loss at all follow-ups (MD = -0.28 , 95% CI [-0.37 , -0.19], $p < 0.0001$) with significant heterogeneity ($I^2 = 94\%$, $p < 0.0001$), (Figure 5 and Supplementary Figure S1).

Table 1. Main characteristics of the included studies.

Authors (Year) Country	Design (Location)	Age (Range) Mean ± SD	Sample Size (M/F Ratio)	Number Evaluated (Participants/Implants)	Extracted Teeth	Reason for Extraction	Population			Socket Shield Procedures	Control Procedures	Implant			Radiographic Assessment	Funding Source	Conflicts of Interest
							Medical Status	Smoking Habit	Periodontal Phenotype			System	Settings	Prosthetic			
Barakat et al. (2017) Egypt [23]	RCT-Pa (University Clinic)	(20:50) 35 years	20 (NR)	Tot: 20/20 SST: 10/10 Con: 10/10	Maxillary incisors and canines	NR	NR	NR	<1.5 mm Labial bone plate thickness	Tooth decoronated: 1 mm above gingival level Root sectioned: a Buccal shield: e Buccal gap: No graft	Tooth extraction: g Flap: h GBR: No graft	Superline implant, Dentium, Gangnam-gu, Seoul, Republic of Korea.	D: 3.3 and 3.8 mm L: 12 and 14 mm T: NR	Delayed implant loading at four months	CBCT	NR	NR
Bramanti et al. (2018) Italy [24]	RCT-Pa (University Clinic)	NR	40 (NR)	Tot: 40/40 SST: 20/20 Con: 20/20	Maxillary/Mandibular incisors and canines	Fractures, destructive caries, internal resorption, and failed root canal treatment	NR	NR	NR	Tooth decoronated: to gingival level Root sectioned: c Buccal shield: e Buccal gap: Bone allograft (j)	Tooth extraction: g Flap: h GPR: Bone allograft (j)	NR	D: 4.5 mm L: NR T: <35 Ncm	Immediate provisional restoration	Periapical radiographs (parallel technique)	Funded (p)	None
Fattouh (2018) Egypt [25]	RCT-Pa (University Clinic)	NR	20 (8 M:12 F)	Tot: 20/20 SST: 10/10 Con: 10/10	Maxillary incisors and canines	NR	NR	Non-smokers	NR	Tooth decoronated: to gingival level Root sectioned: a Buccal shield: f Buccal gap: No graft	Tooth extraction: g Flap: i GPR: Xenograft and collagen membrane (k)	NR	D: 4.1 mm L: 13 mm T: 30 Ncm	Immediate provisional restoration	Periapical radiographs (parallel technique)	NR	NR
Abdel-Raheim et al. (2019) Egypt [26]	RCT-SM (University Clinic)	(20:35) 29.8 ± 5.3 years	10 (4 M:6 F)	Tot: 20/20 SST: 10/10 Con: 10/10	Maxillary incisors and canines	NR	NR	NR	<1.5 mm Labial bone plate thickness	Tooth decoronated: to gingival level Root sectioned: b Buccal shield: e Buccal gap: No graft	Tooth extraction: g Flap: h GBR: No graft	NR	D: NR L: NR T: NR	Immediate provisional restoration	CBCT	NR	NR
Abd-Elrahman et al. (2020) Egypt [27]	RCT-Pa (University Clinic)	(21:39) 30.9 ± 5.5 years	25 (11 M:14 F)	Tot: 25/40 SST: 16/20 Con: 18/20	Maxillary incisors and canines	NR	NR	NR	Both (thick and thin) periodontal phenotype	Tooth decoronated: 1mm above gingival level Root sectioned: a Buccal shield: d Buccal gap: No graft	Tooth extraction: g Flap: h GBR: No graft	Dual implant, Titan Industries EG, Cairo, Egypt	D: 3.3 and 3.7 mm L: 14 and 16 mm T: NR	Immediate provisional restoration	CBCT	NR	None
Hana et al. (2020) Iraq [28]	RCT-Pa (University Clinic)	(28:65) 51 years	40 (24 M:16 F)	Tot: 40/40 SST: 20/20 Con: 20/20	Maxillary/Mandibular incisors and canines	NR	ASA I and ASA II	Non-smokers	NR	Tooth decoronated: 1mm above gingival level Root sectioned: a Buccal shield: d Buccal gap: No graft	Tooth extraction: g Flap: h GBR: No graft	EUROTeknika implant, Sallanches, France	D: 3.5 to 5 (4.1mm) L: 11 to 14 (2.3 mm) T: 49 Ncm	Immediate provisional restoration	CBCT	NR	NR
Sun et al. (2020) China [29]	RCT-Pa (University Clinic)	NR	30 (23 M:7 F)	Tot: 30/30 SST: 15/15 Con: 15/15	Maxillary/Mandibular incisors and canines	Trauma, Decay/pulp lesions	NR	Smokers (<10 cigarettes/day)	Thick gingival biotype with healthy marginal gingiva	Tooth decoronated: 1mm above gingival level Root sectioned: NR Buccal shield: e Buccal gap: Xenograft (if gap >1 mm) (m)	Tooth extraction: g Flap: h GPR: Xenograft (if gap >1 mm) (l)	Nobel Replace [®] cc, Nobel Biocare, Gothenburg, Sweden.	D: 3.5, 4.0 L: NR T: 35 Ncm	Immediate provisional restoration	CBCT	NR	None
Tiwari et al. (2020) India [30]	RCT-Pa (University Clinic)	(18:30) years	16 (NR)	Tot: 16/16 SST: 8/8 Con: 8/8	Maxillary incisors and canines	NR	ASA I and ASA II	NR	Intact buccal cortical plate with <2 mm thickness	Tooth decoronated: below gingival level Root sectioned: a Buccal shield: e Buccal gap: Suture + Periodontal pack	Tooth extraction: g Flap: i GBR: No graft	NR	D: NR L: NR T: 40 Ncm	Delayed implant loading at four months	CBCT	None	None

Table 1. Cont.

Authors (Year) Country	Design (Location)	Age (Range) Mean ± SD	Sample Size (M/F Ratio)	Number Evaluated (Participants/Implants)	Extracted Teeth	Reason for Extraction	Population			Socket Shield Procedures	Control Procedures	Implant			Radiographic Assessment	Funding Source	Conflicts of Interest
							Medical Status	Smoking Habit	Periodontal Phenotype			System	Settings	Prosthetic			
Atef et al. (2021) Egypt [31]	RCT-Pa (University Clinic)	36 ± 5.55 years	42 (11 M:31 F)	Tot: 42/42 SST: 21/21 Con: 21/21	Maxillary premolars and anteriors	NR	NR	Non-smokers	Thick gingival biotype	Tooth decoronated: to gingival level Root sectioned: a Buccal shield: d Buccal gap: Collagen plug	Tooth extraction: g Flap: i GPR: Xenograft (m)	IS II, Neobiotech Co., Seoul, Republic of Korea	D: NR L: NR T: NR	Delayed implant loading at four months	CBCT	None	None
Kumar et al. (2021) India [32]	RCT-Pa (University Clinic)	37 years	20 (14 M:6 F)	Tot: 20/30 SST: 10/15 Con: 10/15	Maxillary incisors and canines	NR	NR	NR	NR	Tooth decoronated: to gingival level Root sectioned: a Buccal shield: e Buccal gap: No graft	Tooth extraction: g Flap: h GBR: No graft	Megagen Implant Co. Ltd., Seoul, Republic of Korea	D: 3.5-mm L: NR T: NR	Delayed implant loading at four months	Periapical radiographs (parallel technique)	Funded (q,r)	None
Santhanakrishnan et al. (2021) India [33]	RCT-Pa (University Clinic)	(18:50) 30.6 ± 6.0 years	50 (23 M:27 F)	Tot: 50/50 SST: 25/25 Con: 25/25	Maxillary incisors and canines	NR	NR	NR	Intact facial bone with <2 mm thickness	Tooth decoronated: 1mm above gingival level Root sectioned: a Buccal shield: d Buccal gap: No graft	Tooth extraction: g Flap: h GPR: Xenograft and autogenous bone (n)	DIO implant system, Busan, Republic of Korea	D: 3.3 and 3.8 mm L: 13 and 15 mm T: 40 Ncm	Immediate provisional restoration	CBCT	None	None
Abdullah et al. (2022) Egypt [34]	RCT-Pa (University Clinic)	29.4 years	46 (20 M:26 F)	Tot: 46/46 SST: 23/23 Con: 23/23	Maxillary premolars and anteriors	Failed root canal treatment	NR	NR	Both (thick and thin) periodontal phenotype	Tooth decoronated: 1 mm above gingival level Root sectioned: a Buccal shield: d Buccal gap: No graft	Tooth extraction: g Flap: h GPR: Xenograft (o)	IS II, Neobiotech Co., Seoul, Republic of Korea	NR	Immediate provisional restoration	CBCT	None	None

Explanations:

- a. The root was sectioned using a long shank bur.
- b. The root was sectioned using a Lindemann cutter.
- c. The root was sectioned using a piezosurgical insert.
- d. The buccal shield was reduced to the level of crestal bone.
- e. The buccal shield was reduced to a level below crestal bone.
- f. The buccal shield was reduced to a level above crestal bone.
- g. Atraumatic extraction using periosteal and forceps followed by socket debridement using curettes
- h. The surgical technique used atraumatic tooth extraction with no flap elevation.
- i. A mucoperiosteal flap was raised, and minimally traumatic extraction was performed.
- j. CopiOs, Zimmer Dental
- k. (0.25–0.5 mm size) BioOss® Spongiosa and BioGide® collagen membrane (Geistlich Biomaterials, Wolhusen, Switzerland).
- l. DBBM, Bio-Oss; Geistlich Pharma AG, Bahnhofstrasse, Switzerland.
- m. Tutobone, Tutogen Medical GmbH, Neunkirchen am Brand, Germany.
- n. DBBM; Bio-Oss, Geistlich AG.
- o. Cerabone botiss biomaterials GmbH, Germany
- p. University funding
- q. Government funding
- r. Implant company funding

Abbreviations: RCT, randomized clinical trial; Pa, parallel design; SM, split-mouth design; NR, not reported; M, male; F, female; Tot, total; SST, socket shield technique; Con, control; ASA, American Society of Anesthesiologists; GPR, guided bone regeneration; D, diameter; L, length; T, torque; CBCT, cone beam computed tomography.

Study	Risk of bias domains					Overall
	D1	D2	D3	D4	D5	
Barakat et al. (2017)	-	-	+	-	-	X
Bramanti et al. (2018)	+	+	+	+	-	-
Fattouh (2018)	-	-	+	-	-	X
Abdel-Raheim et al. (2019)	-	-	+	-	-	X
Abd-Elrahman et al. (2020)	-	-	+	-	-	X
Hana et al. (2020)	-	-	+	-	-	X
Sun et al. (2020)	+	-	+	+	-	-
Tiwari et al. (2020)	+	-	+	-	-	X
Atef et al. (2021)	+	-	+	+	+	+
Kumar et al. (2021)	-	-	+	+	-	X
Santhanakrishnan et al. (2021)	+	+	+	+	+	+
Abdullah et al. (2022)	+	-	+	+	-	-

Domains:
 D1: Bias arising from the randomization process.
 D2: Bias due to deviations from intended intervention.
 D3: Bias due to missing outcome data.
 D4: Bias in measurement of the outcome.
 D5: Bias in selection of the reported result.

Judgement
 X High
 - Some concerns
 + Low

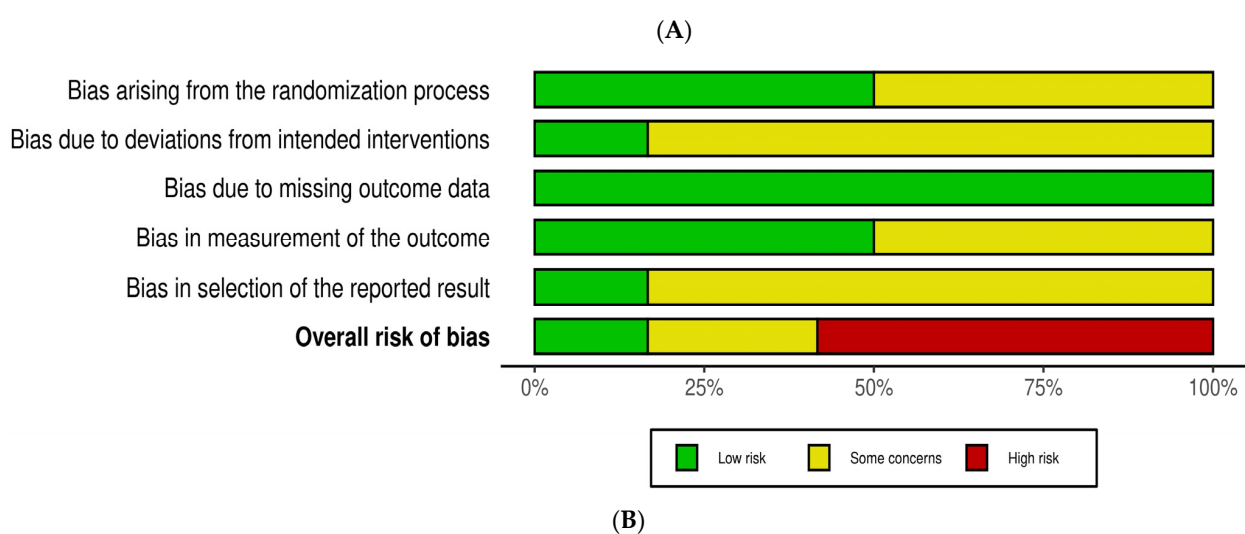


Figure 4. Risk of bias. (A) Risk of bias summary shows each risk of bias for each included study [23–34]. (B) Risk of bias graph summarized each risk of bias item presented as percentages across all included studies.

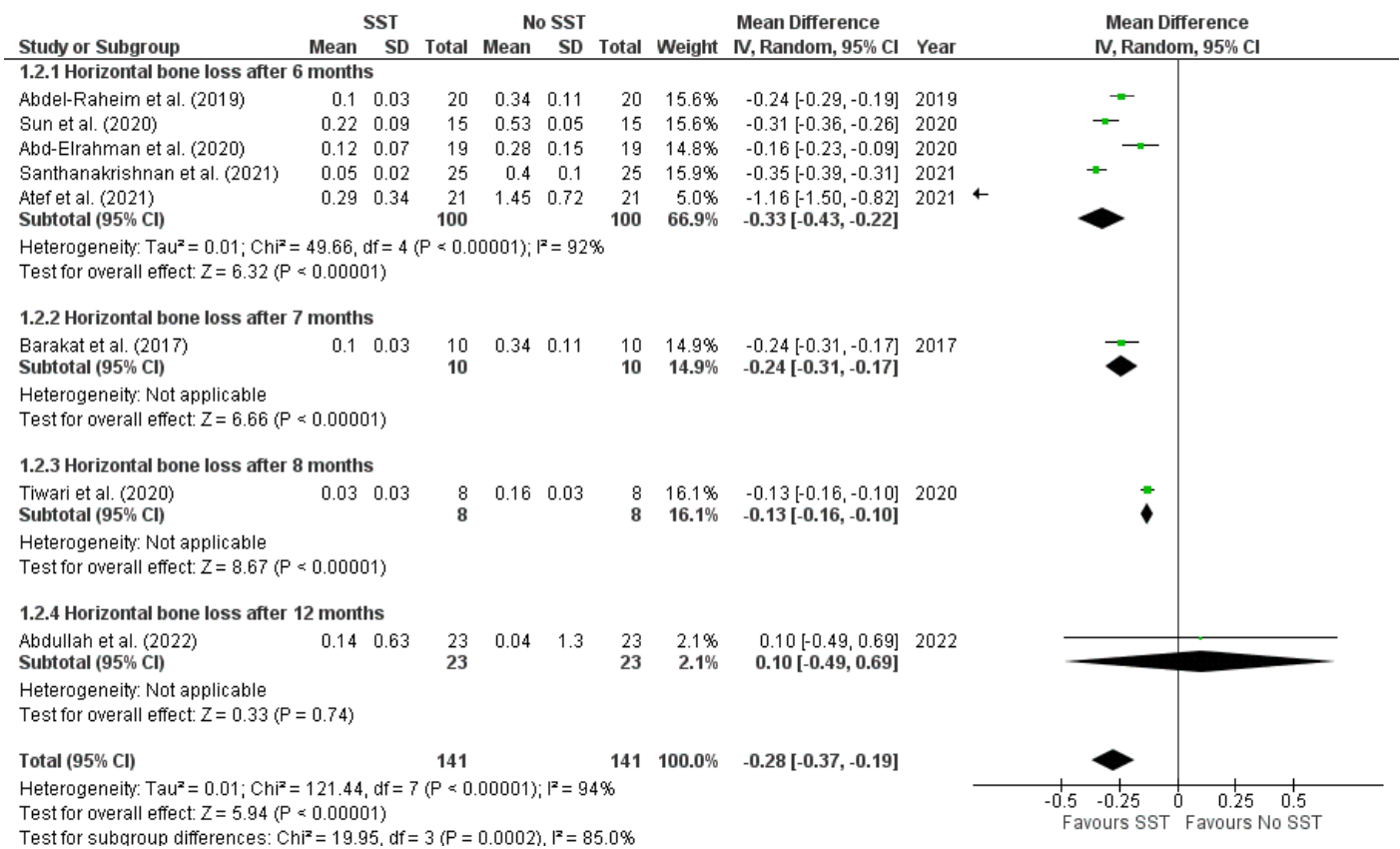


Figure 5. Forest plot of horizontal bone loss at all reported follow-ups [23,26,27,29–31,33,34].

3.5.2. Vertical Bone Loss (i.e., Changes in Buccal Bone Height)

Six RCTs involved 172 immediate implants placed in 156 patients with follow-up periods ranging from six to seven months. At all follow-ups, immediate implants implanted with SST showed a statistically significant decrease in vertical bone loss (MD = -0.85, 95% CI [-1.12, -0.58], p < 0.0001) with significant heterogeneity (I² = 85%, p < 0.0001), (Figure 6 and Supplementary Figure S2).

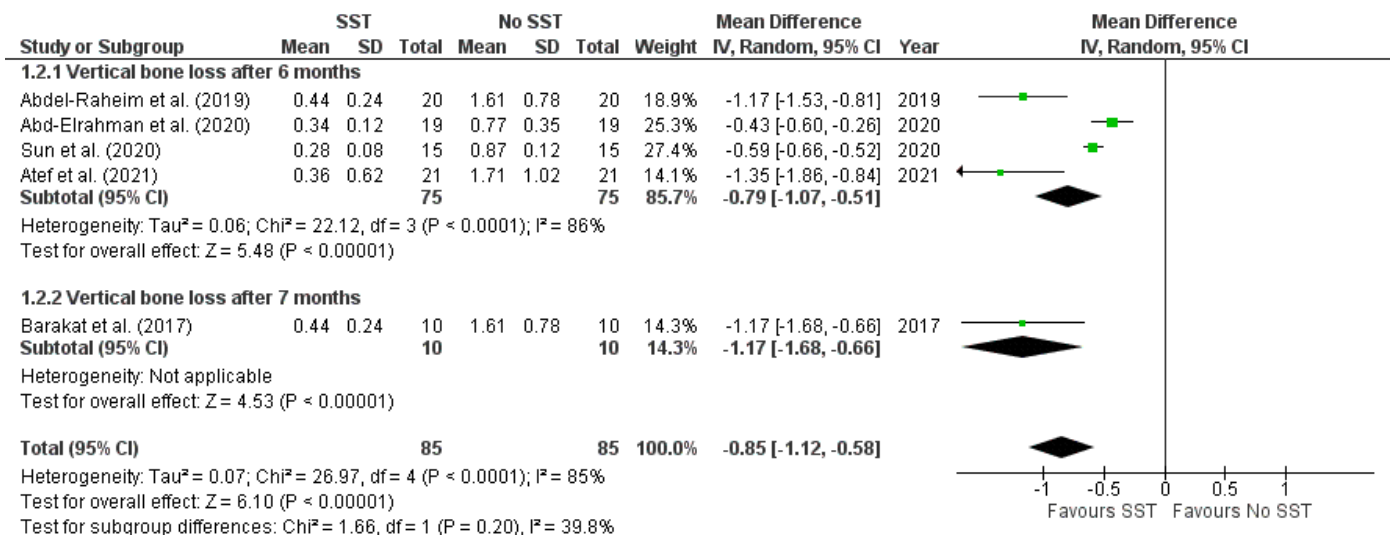


Figure 6. Forest plot of vertical bone loss at all reported follow-ups [23,26,27,29,31].

3.5.3. Implant Stability Quotient (ISQ)

Five RCTs, involving 156 immediate implants placed in 140 patients, evaluated the implant stability immediately after implantation, with follow-ups ranging from four to six months. There was no significant difference in ISQ measurements immediately after implantation (MD = 2.22, 95% CI [-0.17, 4.60], $p = 0.07$) with non-significant heterogeneity ($I^2 = 48%$, $p = 0.11$); however, immediate implants placed with SST had significant stability at all follow-ups (MD = 3.46, 95% CI [1.22, 5.69], $p = 0.002$) with moderate significant heterogeneity ($I^2 = 35%$, $p = 0.20$), (Figure 7 and Supplementary Figure S3).

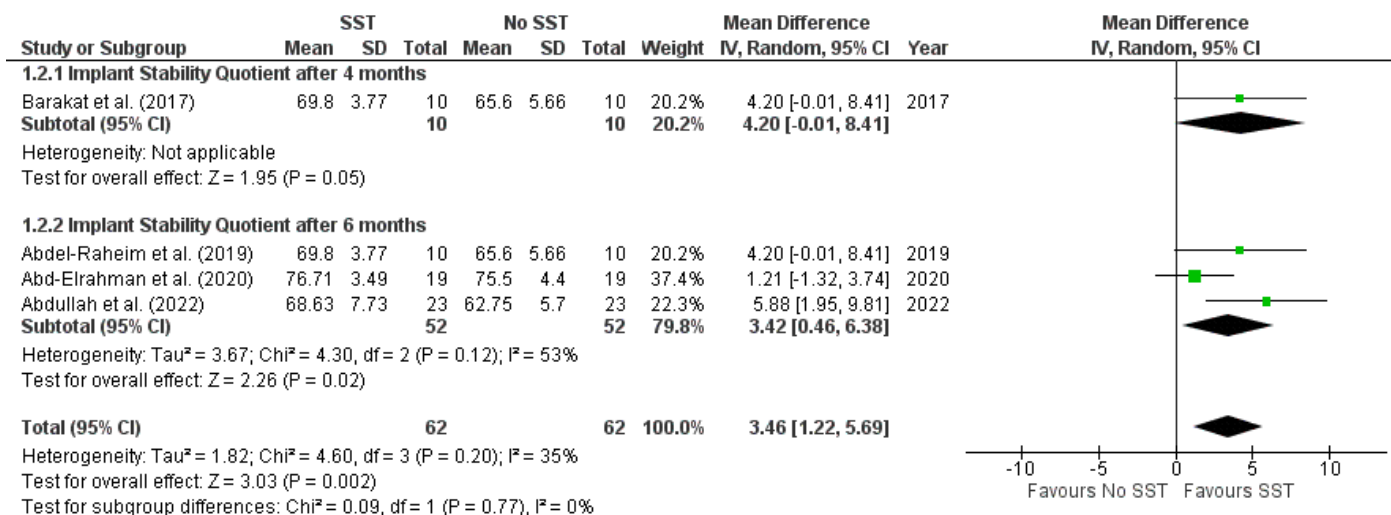


Figure 7. Forest plot of implant stability quotient at all reported follow-ups [23,26,27,34].

3.5.4. Pink Esthetic Score (PES)

Eight RCTs involved 296 immediate implants placed in 280 patients with follow-up periods ranging from four months to three years. At all follow-ups, immediate implants placed with SST showed a statistically significant increase in the pink esthetic score (MD = 1.60, 95% CI [0.90, 2.30], $p < 0.0001$) with significant heterogeneity ($I^2 = 81%$, $p < 0.0001$), (Figure 8 and Supplementary Figure S4).

3.5.5. Crestal Bone Loss (i.e., Changes in Marginal Bone Levels)

Three RCTs involved 106 immediate implants placed in 106 patients with follow-up periods ranging from three months to three years. Immediate implants placed with SST had a statistically significant decrease in the amount of crestal bone loss across all follow-ups (MD = -0.35, 95% CI [-0.56, -0.13], $p = 0.002$) with significant heterogeneity ($I^2 = 84%$, $p = 0.002$). (Figure 9 and Supplementary Figure S5).

3.5.6. Probing Depth

Two RCTs, involving 50 immediate implants placed in 50 patients, measured the probing depth at follow-up periods ranging from four months to two years. At all follow-ups, there was a statistically significant decrease in probing depth measures in immediate implants placed with SST (MD = -0.64, 95% CI [-0.99, -0.29], $p = 0.0003$) with moderate significant heterogeneity ($I^2 = 66%$, $p = 0.09$), (Figure 10 and Supplementary Figure S6).

3.5.7. Complications

Eight RCTs (66.67%) revealed no post-operative complications [26–29,32,34–36], and two (17%) did not report information about post-operative complications [33,37]. Only Abd-Elrahman et al. [30] and Hana et al. [31] reported shield exposure incidences in the SST group (one and two patients, respectively).

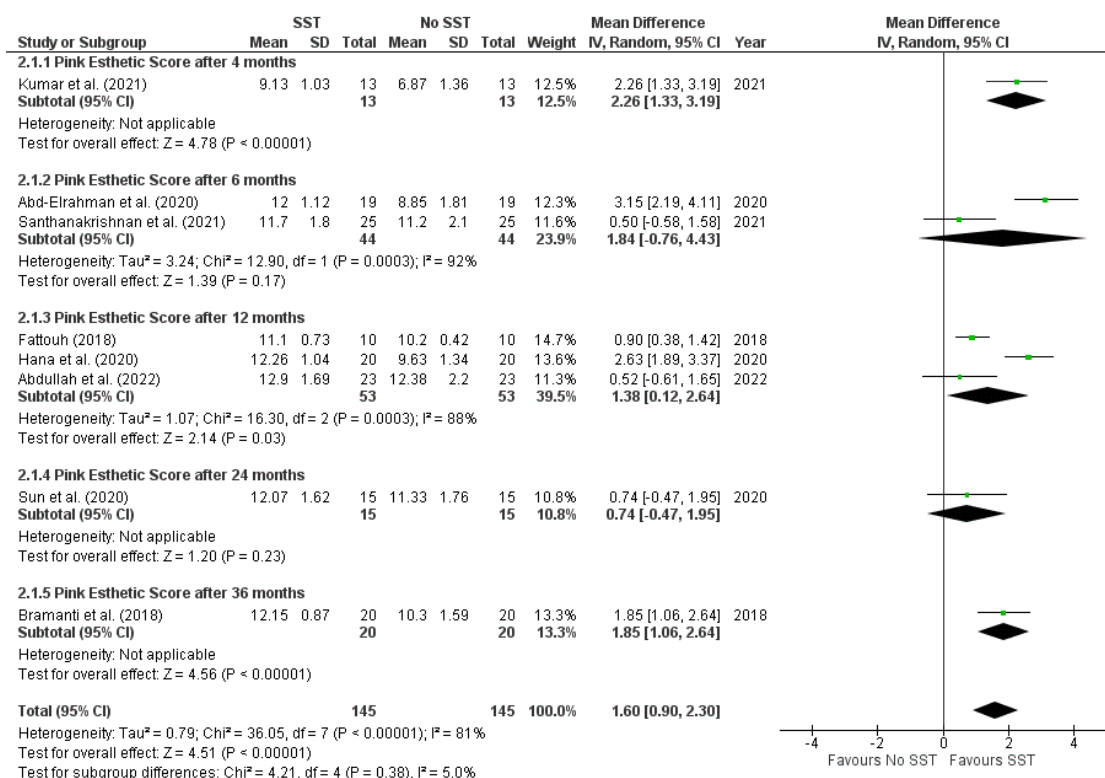


Figure 8. Forest plot of the pink esthetic score at all reported follow-ups [24,25,28–30,32–34].

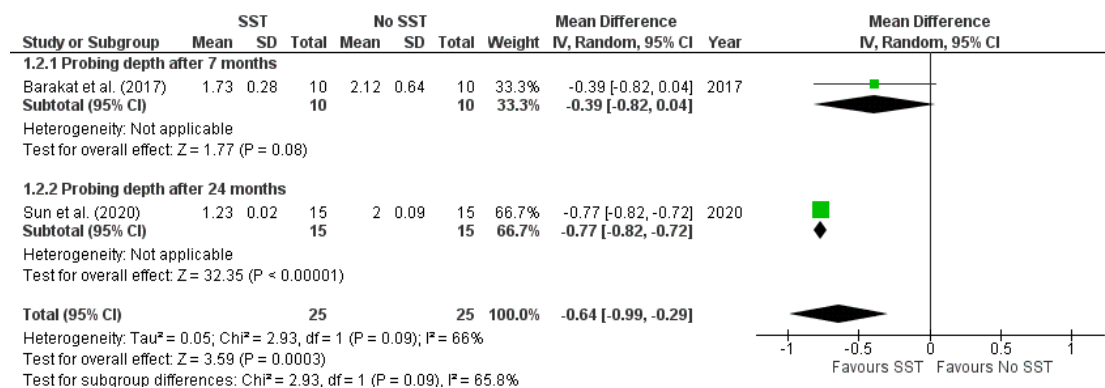


Figure 9. Forest plot of crestal bone loss at all reported follow-ups [23,29].

3.5.8. Implant Failure

All included studies (12 RCTs, involving 414 immediate implants placed in 398 patients) revealed no implant failure and a 100% survival rate at follow-up periods ranging from four months to three years. (Supplementary Table S3).

3.6. Sensitivity Analysis

Given that most RCTs had a high risk of bias, a sensitivity analysis excluding RCTs with a high risk of bias was not possible. However, we comparatively assessed all reported outcomes after different follow-up periods, and sensitivity analyses yielded similar results to the primary analyses. (Supplementary Figures S1–S6).

3.7. Certainty of Evidence

The certainty of the cumulative evidence obtained through our study was assessed as very low; such downrating was primarily due to limitations in the studies' design and inconsistency (Table 2).

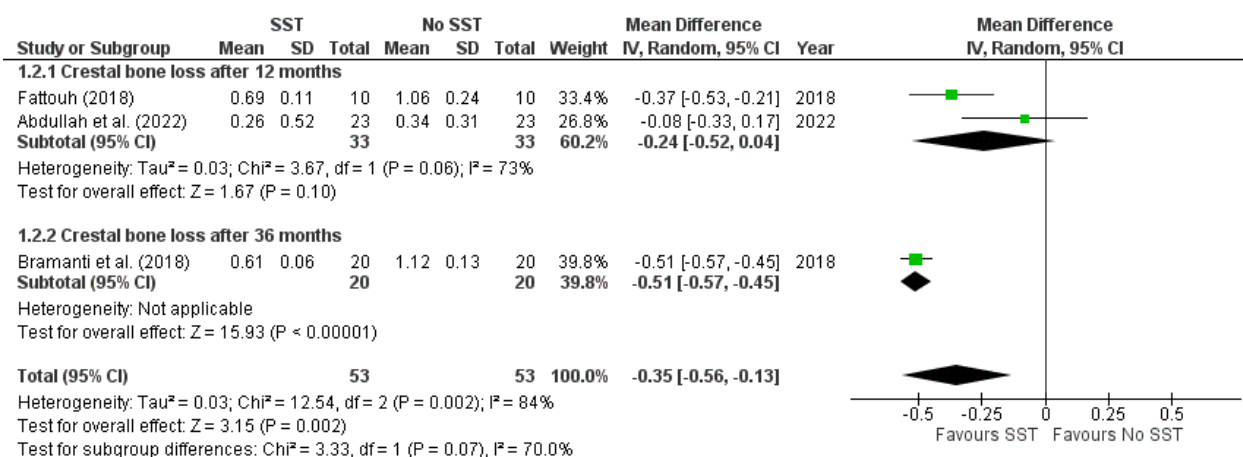


Figure 10. Forest plot of probing depth at all reported follow-ups [24,25,34].

Table 2. Summary of Findings table (SoF).

Outcomes	N° of Participants/Implants (Studies)	Certainty of the Evidence (GRADE)	Relative Effect (95% CI)	Anticipated Absolute Effects	
				Risk with [No SST]	Risk Difference with [SST]
Horizontal bone loss (i.e., changes in buccal bone width) assessed with: mm follow-up range: four months to twelve months	268/284 (8 RCTs)	⊕○○○ Very low	-	The mean horizontal bone loss (i.e., changes in buccal bone width) was 0 mm	MD 0.28 mm fewer (0.37 fewer to 0.19 fewer)
Vertical bone loss (i.e., changes in buccal bone height) assessed with: mm follow-up range: six months to seven months	156/166 (6 RCTs)	⊕○○○ Very low	-	The mean vertical bone loss (i.e., changes in buccal bone height) was 0 mm	MD 0.85 mm fewer (1.12 fewer to 0.58 fewer)
Implant Stability assessed with: ISQ measurements follow-up range: four months to six months	140/156 (5 RCTs)	⊕○○○ Very low	-	The mean implant Stability Quotient (ISQ) was 0	MD 3.46 more (1.22 more to 5.69 more)
Esthetic evaluation assessed with: PES measurements follow-up range: four months to three years	280/296 (8 RCTs)	⊕○○○ Very low	-	The mean pink Esthetic Score (PES) was 0	MD 1.6 more (0.9 more to 2.3 more)
Crestal bone loss (i.e., changes in marginal bone levels) assessed with: mm follow-up range: three months to three years	106/106 (3 RCTs)	⊕○○○ Very low	-	The mean crestal bone loss (i.e., changes in marginal bone levels) was 0 mm	MD 0.35 mm fewer (0.56 fewer to 0.13 fewer)
Probing depth assessed with: mm follow-up range: four months to two years	50/50 (2 RCTs)	⊕○○○ Very low	-	The mean probing depth was 0 mm	MD 0.64 mm fewer (0.99 fewer to 0.29 fewer)

* The risk in the intervention group (and its 95% confidence interval) is based on the assumed risk in the comparison group and the relative effect of the intervention (and its 95% CI).

CI: confidence interval; MD: mean difference

GRADE Working Group grades of evidence

High certainty: We are very confident that the true effect lies close to that of the estimate of the effect.

Moderate certainty: We are moderately confident in the effect estimate: the true effect is likely to be close to the estimate of the effect, but there is a possibility that it is substantially different.

Low certainty: Our confidence in the effect estimate is limited: the true effect may be substantially different from the estimate of the effect.

Very low certainty: We have very little confidence in the effect estimate: the true effect is likely to be substantially different from the estimate of effect.

4. Discussion

In this meta-analysis, we systematically assessed the available evidence about the effectiveness of SST in immediate implant placement regarding all outcomes, including only RCTs based on strict eligibility criteria, to ensure providing high-quality evidence. As a result, twelve RCTs from five countries (Egypt, India, Iraq, Italy, and China), with follow-up periods ranging from three months to three years, were included. We found that the immediate implants placed with SST were more effective than the conventional approach (with or without grafting) in minimizing horizontal, vertical, and crestal bone loss, improving esthetic outcomes, increasing implant stability, and decreasing probing depth at different time points. However, the cumulative evidence certainty of these findings was assessed as very low. Our meta-analysis revealed that immediate implants placed with SST had superior esthetic outcomes. This esthetic evaluation was performed using the PES, considered the most valid and reliable among several indices for evaluating implant-supported prostheses in the anterior area. PES considers seven parameters (the mesial and distal papilla levels, the soft tissues contour, level, texture, and color, and the alveolar process deficiencies), assigning a score between 0 and 2, with a maximum score of 14 [36]. Such superior esthetic findings can be attributed to the reduced soft tissue volumetric alterations due to the preservation of hard tissues surrounding the implant. As such, the efficient crest preservation from post-extraction remodeling is reflected in the soft tissue stability and the esthetic results. Based on our findings, the immediate implant placed with SST revealed a 100% survival rate at follow-up periods ranging from four months to three years without implant failure. Moreover, the adverse effects of SST were limited because only Hana et al. [28] reported post-operative complications (internal and external shield exposure) in two patients who were treated with root reduction and soft tissue grafting, as well as Abd-Elrahman et al. [27], who reported internal shield exposure in two patients who required only monitoring over time without further signs of inflammation or need for intervention. However, such findings should be interpreted cautiously because 83.3% of included studies had a short follow-up period (i.e., not exceeding one year).

Agreements with long-term follow-up studies include Siormpas et al. [35], who reported a 96.5% survival rate and 87.9% success rate at about 10-year follow-up, and Mitsias et al. [37] found all implants had successful osseointegration with optimal soft tissue stability and dimensional changes of the soft tissues ranging from 0.19 mm (95% CI [0.10, 0.28]) in the mid-buccal area to -0.06 mm (95% CI [-0.14 , 0.02]) in the distal papilla area at minimum three-year follow-up. Additionally, Baumer et al. [38] reported a 0.33 ± 0.23 mm average mid-buccal recession at implants and a 0.38 ± 0.27 mm at neighboring teeth, a buccal tissue loss (in oro-facial direction) of 0.21 ± 0.18 mm, and a marginal bone loss of 0.33 ± 0.43 mm mesially and 0.17 ± 0.36 mm distally after five-year follow-up without adverse effects. Such consistency in the outcomes of these long-term studies with our findings seems to support the excellent hard and soft tissue stability with insignificant recessions.

Despite several SST modifications reported in the literature [12,19,35,36,39,40], SST remains a minimally invasive approach for immediate implantation. Such modifications are primarily attributed to the preparation of the buccal shield, which involves the shield's height and thickness concerning the crestal bone level, and the controversy on whether or not to use grafting material to fill the gap between the buccal shield and implant [12,19,39,40]. For instance, many clinical and histological investigations have indicated that leaving the gap empty induces the formation of new bone rather than cementum [9,41,42]; in contrast, other research preferred to fill the gap with xenograft to avoid soft tissue migration towards this space [19,40,43]. As such, Hürzeler et al. [12] recommended using a graft if the gap distance is more than two mm to prevent soft tissue migration into the gap, while Gluckman et al. [40] recommended always filling the space between the implant and the root fragment with grafting materials.

Regarding the root length, only a few of included studies specified the size of the root remnant; however, it should be at most 8 mm or about two-thirds of the original root

length [41], as confirmed by histological studies on animals, which showed better bone preservation for 1/3 and 2/3 root remnant lengths [42,44]; however, there was a lack of adhesion between bone, remnant fragment, and implant, with an apical migration of the connective tissue when the fragments were longer than the coronal third.

Similarly, not all studies specified the root thickness; however, Gluckman et al. [45] recommended reducing the root to about half the thickness between the root canal and buccal bone, while Kher et al. [41] recommended the thickness be about a quarter of the buccolingual thickness of the root or at least 1.5 mm. Although the original Hürzeler technique retained a height of 1 mm [12], Gluckman et al. [45] recommended reducing the root 1 mm below the crest to reduce the risk of exposure. Additionally, Tan et al.'s animal study [46] demonstrated that root height at or 1 mm above the crestal level could influence the height of alveolar bone after three months or the development of new bone between dentin and implant. Although the potential effects of various SST procedures on the long-term outcomes of immediate implant placement remain unknown, we could not compare such surgical differences in SST due to limited studies available.

5. Strengths and Limitations

Our robust methodology and evaluation of all available immediate implant outcomes for all reported follow-up periods are the strengths of this systematic review and meta-analysis. To avoid misleading conclusions, we also presented effect estimates and confidence intervals for all outcomes and assessed their certainty of evidence using the GRADE approach. However, the current evidence had a very low certainty, primarily due to the inconsistency (significant heterogeneity) among included studies and the study's design limitations. Such heterogeneity could be attributed to differences in SST procedures regarding tooth decoronation, shaping, and reduction in the buccal shield, as well as whether or not the gap between the buccal shield and implant is filled with grafting materials. Additionally, none of the included RCTs provided adequate information in the descriptions of eligibility criteria about the risk factors and confounders (e.g., patients' medical status, smoking habit, periodontal phenotype, etc.) that could influence the surgeries outcomes and whether the SST and control groups were balanced regarding these influencing factors, which undermine the precision of their results.

On the other hand, the limitations in study design were attributable to bias in the randomization process, since 50% of included studies did not report information about allocation concealment or bias in the outcome measurement, since 50% of studies did not blindly assess the outcomes and bias in the selection of reported results, since 83% of studies did not have a pre-specified plan to compare outcome measurements and analyses with it. As a result, the limited sample of included studies with a high risk of bias and heterogeneity constituted limitations of this study and undermined the credibility of its findings; hence, these gained conclusions should be carefully considered and not regarded as clinical guidance. Moreover, there are some limitations to this systematic review. The first is excluding non-English studies, which might provide valuable data. Second, the small sample size of included studies and the lack of long-term follow-up might impact the implant failure rate.

6. Conclusions

Based on the limited body of evidence, our systematic review and meta-analysis found that the immediate implants placed with SST were more effective than the conventional approach (with or without grafting) in minimizing horizontal, vertical, and crestal bone loss, improving esthetic outcomes, increasing implant stability, and decreasing probing depth at different time points (ranging from three months to three years) with negligible complications and a 100% survival rate. Further long-term, well designed, and well reported RCTs with larger sample sizes are needed to confirm these findings.

Supplementary Materials: The following supporting information can be downloaded at: <https://www.mdpi.com/article/10.3390/prosthesis5020035/s1>, Table S1: Search strategies. Table S2: Excluded studies after the full-text screening ($n = 68$). Table S3: Results of all outcomes during follow-ups. Figure S1: Sensitivity analysis measuring the amount of horizontal bone loss at different follow-ups. Figure S2: Sensitivity analysis measuring the amount of vertical bone loss at different follow-ups. Figure S3: Sensitivity analysis measuring the implant stability quotient at different follow-ups. Figure S4: Sensitivity analysis measuring the pink esthetic score at different follow-ups. Figure S5: Sensitivity analysis measuring the amount of crestal bone loss at different follow-ups. Figure S6: Sensitivity analysis measuring the probing depth at different follow-ups [47].

Author Contributions: Conceptualization, A.S.; methodology, A.S., L.L., F.L. and F.S.A.-H.; software, F.S.A.-H., A.S., L.L. and F.L.; validation, A.S., M.D.C., F.S.A.-H., A.G.A.K., S.A.G., S.R.T., L.L., F.I. and F.L.; formal analysis, A.S., F.S.A.-H. and F.L.; investigation, A.S.; data curation, A.S. and F.L.; F.S.A.-H. and L.L.; writing—original draft preparation, A.S., F.L., F.S.A.-H. and L.L.; writing—review and editing, A.S., F.L., F.S.A.-H. and L.L. All authors have read and agreed to the published version of the manuscript.

Funding: This research received no external funding.

Institutional Review Board Statement: Not applicable.

Informed Consent Statement: Not applicable.

Data Availability Statement: All experimental data to support the findings of this study are available upon contacting the corresponding author upon request.

Conflicts of Interest: The authors declare no conflict of interest.

References

1. Cornelini, R.; Scarano, A.; Covani, U.; Petrone, G.; Piattelli, A. Immediate One-Stage Postextraction Implant: A Human Clinical and Histologic Case Report. *Int. J. Oral Maxillofac. Implant.* **2000**, *15*, 432–437.
2. Scarano, A.; Conte, E.; Mastrangelo, F.; Greco Lucchina, A.; Lorusso, F. Narrow Single Tooth Implants for Congenitally Missing Maxillary Lateral Incisors: A 5-Year Follow-Up. *J. Biol. Regul. Homeost. Agents* **2019**, *33*, 69–76. [[PubMed](#)]
3. Scarano, A.; Assenza, B.; Di Cerbo, A.; Candotto, V.; De Oliveira, S.P.; Lorusso, F. Bone Regeneration in Aesthetic Areas Using Titanium Micromesh. Three Case Reports. *Oral Implant.* **2017**, *10*, 488–494. [[CrossRef](#)]
4. Buser, D.; Martin, W.; Belsler, U.C. Optimizing Esthetics for Implant Restorations in the Anterior Maxilla: Anatomic and Surgical Considerations. *Int. J. Oral Maxillofac. Implant.* **2004**, *19*, 43–61.
5. Chappuis, V.; Araújo, M.G.; Buser, D. Clinical Relevance of Dimensional Bone and Soft Tissue Alterations Post-Extraction in Esthetic Sites. *Periodontol.* **2017**, *73*, 73–83. [[CrossRef](#)]
6. Tsigarida, A.; Toscano, J.; de Brito Bezerra, B.; Geminiani, A.; Barmak, A.B.; Caton, J.; Papaspyridakos, P.; Chochlidakis, K. Buccal Bone Thickness of Maxillary Anterior Teeth: A Systematic Review and Meta-Analysis. *J. Clin. Periodontol.* **2020**, *47*, 1326–1343. [[CrossRef](#)]
7. Huynh-Ba, G.; Pjetursson, B.E.; Sanz, M.; Cecchinato, D.; Ferrus, J.; Lindhe, J.; Lang, N.P. Analysis of the Socket Bone Wall Dimensions in the Upper Maxilla in Relation to Immediate Implant Placement: Socket Bone Wall Dimensions and Immediate Implant Placement. *Clin. Oral Implant. Res.* **2010**, *21*, 37–42. [[CrossRef](#)]
8. Pagni, G.; Pellegrini, G.; Giannobile, W.V.; Rasperini, G. Postextraction Alveolar Ridge Preservation: Biological Basis and Treatments. *Int. J. Dent.* **2012**, *2012*, 1–13. [[CrossRef](#)]
9. Al Yafi, F.; Alchawaf, B.; Nelson, K. What Is the Optimum for Alveolar Ridge Preservation? *Dent. Clin. N. Am.* **2019**, *63*, 399–418. [[CrossRef](#)]
10. López-Pacheco, A.; Soto-Peñaloza, D.; Gómez, M.; Peñarocha-Oltra, D.; Alarcón, M.A. Socket Seal Surgery Techniques in the Esthetic Zone: A Systematic Review with Meta-Analysis and Trial Sequential Analysis of Randomized Clinical Trials. *Int. J. Implant. Dent.* **2021**, *7*, 13. [[CrossRef](#)]
11. Lee, C.-T.; Chiu, T.-S.; Chuang, S.-K.; Tarnow, D.; Stoupe, J. Alterations of the Bone Dimension Following Immediate Implant Placement into Extraction Socket: Systematic Review and Meta-Analysis. *J. Clin. Periodontol.* **2014**, *41*, 914–926. [[CrossRef](#)]
12. Hürzeler, M.B.; Zuh, O.; Schupbach, P.; Rebele, S.F.; Emmanouilidis, N.; Fickl, S. The Socket-Shield Technique: A Proof-of-Principle Report: The Socket Shield Technique. *J. Clin. Periodontol.* **2010**, *37*, 855–862. [[CrossRef](#)] [[PubMed](#)]
13. Reames, R.L.; Nickel, J.S.; Patterson, S.S.; Boone, M.; El-Kafrawy, A.H. Clinical, Radiographic, and Histological Study of Endodontically Treated Retained Roots to Preserve Alveolar Bone. *J. Endod.* **1975**, *1*, 367–373. [[CrossRef](#)]
14. O'Neal, R.B.; Gound, T.; Levin, M.P.; Del Rio, C.E. Submergence of Roots for Alveolar Bone Preservation. *Oral Surg. Oral Med. Oral Pathol.* **1978**, *45*, 803–810. [[CrossRef](#)]

15. Buser, D.; Warrar, K.; Karring, T. Formation of a Periodontal Ligament Around Titanium Implants. *J. Periodontol.* **1990**, *61*, 597–601. [[CrossRef](#)] [[PubMed](#)]
16. Plata, R.L.; Kelln, E.E. Intentional Retention of Vital Submerged Roots in Dogs. *Oral Surg. Oral Med. Oral Pathol.* **1976**, *42*, 100–108. [[CrossRef](#)]
17. Filippi, A.; Pohl, Y.; Von Arx, T. Decoronation of an Ankylosed Tooth for Preservation of Alveolar Bone Prior to Implant Placement*: Decoronation for Preservation of Alveolar Bone. *Dent. Traumatol.* **2001**, *17*, 93–95. [[CrossRef](#)] [[PubMed](#)]
18. Gluckman, H.; Du Toit, J.; Salama, M.; Nagy, K.; Dard, M. A Decade of the Socket-Shield Technique: A Step-by-Step Partial Extraction Therapy Protocol. *Int. J. Esthet. Dent.* **2020**, *15*, 212–225.
19. Gluckman, H.; Salama, M.; Du Toit, J. Partial Extraction Therapies (PET) Part 2: Procedures and Technical Aspects. *Int. J. Periodontics Restor. Dent.* **2017**, *37*, 377–385. [[CrossRef](#)]
20. Liberati, A.; Altman, D.G.; Tetzlaff, J.; Mulrow, C.; Gøtzsche, P.C.; Ioannidis, J.P.A.; Clarke, M.; Devereaux, P.J.; Kleijnen, J.; Moher, D. The PRISMA Statement for Reporting Systematic Reviews and Meta-Analyses of Studies That Evaluate Health Care Interventions: Explanation and Elaboration. *J. Clin. Epidemiol.* **2009**, *62*, e1–e34. [[CrossRef](#)]
21. Higgins, J.P.T.; Thomas, J.; Chandler, J.; Cumpston, M.; Li, T.; Page, M.J.; Welch, V.A. (Eds.) *Cochrane Handbook for Systematic Reviews of Interventions*, 1st ed.; Wiley: Hoboken, NJ, USA, 2019; ISBN 978-1-119-53662-8.
22. Schünemann, H.; Brożek, J.; Guyatt, G.; Oxman, A. Handbook for Grading the Quality of Evidence and the Strength of Recommendations Using the GRADE Approach, (updated October 2013). Available online: <https://gdt.gradepro.org/app/handbook/handbook.html> (accessed on 10 March 2023).
23. Barakat, D.A.; Hassan, R.S.; Eldibany, R.M. Evaluation of the Socket Shield Technique for Immediate Implantation. *Alex. Dent. J.* **2017**, *42*, 155–161. [[CrossRef](#)]
24. Bramanti, E.; Norcia, A.; Cicciù, M.; Maticena, G.; Cervino, G.; Troiano, G.; Zhurakivska, K.; Laino, L. Postextraction Dental Implant in the Aesthetic Zone, Socket Shield Technique Versus Conventional Protocol. *J. Craniofac. Surg.* **2018**, *29*, 1037–1041. [[CrossRef](#)]
25. Fattouh, H. Socket-Shield Technique versus Guided Bone Regeneration Technique for Ridge Preservation with Immediate Implant Placement in the Esthetic Zone. *Egypt. Dent. J.* **2018**, *64*, 2047–2055. [[CrossRef](#)]
26. Abdel-Raheim, A.S.; Al-Fakharany, A.-M.H. Evaluation of Immediate Immediate Implant with Socket Shield Technique in Aesthetic Zone. *Al-Azhar J. Dent. Sci.* **2019**, *22*, 129.
27. Abd-Elrahman, A.; Shaheen, M.; Askar, N.; Atef, M. Socket Shield Technique vs Conventional Immediate Implant Placement with Immediate Temporization. Randomized Clinical Trial. *Clin. Implant. Dent. Relat. Res.* **2020**, *22*, 602–611. [[CrossRef](#)]
28. Hana, S.A.; Omar, O.A. Socket Shield Technique for Dental Implants in the Esthetic Zone, Clinical and Radiographical Evaluation. *J. Duhok Univ.* **2020**, *23*, 69–80. [[CrossRef](#)]
29. Sun, C.; Zhao, J.; Liu, Z.; Tan, L.; Huang, Y.; Zhao, L.; Tao, H. Comparing Conventional Flap-Less Immediate Implantation and Socket-Shield Technique for Esthetic and Clinical Outcomes: A Randomized Clinical Study. *Clin. Oral Implant. Res.* **2020**, *31*, 181–191. [[CrossRef](#)]
30. Tiwari, S.; Bedi, R.S.; Wadhvani, P.; Aurora, J.K.; Chauhan, H. Comparison of Immediate Implant Placement Following Extraction with and without Socket-Shield Technique in Esthetic Region. *J. Maxillofac. Oral Surg.* **2020**, *19*, 552–560. [[CrossRef](#)]
31. Atef, M.; El Barbary, A.; Dahrous, M.S.E.-D.; Zahran, A.F. Comparison of the Soft and Hard Peri-Implant Tissue Dimensional Changes around Single Immediate Implants in the Esthetic Zone with Socket Shield Technique versus Using Xenograft: A Randomized Controlled Clinical Trial. *Clin. Implant. Dent. Relat. Res.* **2021**, *23*, 456–465. [[CrossRef](#)]
32. Kumar, P.R.; Vikram, J.; Kher, U.; Tunkiwala, A.; Sawhney, H. Pink Esthetic and Radiological Scores around Immediate Implants Placed in the Esthetic Zone—Socket-Shield Technique versus Immediate Conventional Technique: A Pilot Study. *J. Indian Soc. Periodontol.* **2021**, *25*, 510–517. [[CrossRef](#)]
33. Santhanakrishnan, M.; Subramanian, V.; Ramesh, N.; Kamaleeshwari, R. Radiographic and Esthetic Evaluation Following Immediate Implant Placement with or without Socket Shield and Delayed Implant Placement Following Socket Preservation in the Maxillary Esthetic Region—A Randomized Controlled Clinical Trial. *Clin. Cosmet. Investig. Dent.* **2021**, *13*, 479–494. [[CrossRef](#)] [[PubMed](#)]
34. Abdullah, A.H.; Abdel Gaber, H.K.; Adel-Khattab, D. Evaluation of Soft Tissue and Labial Plate of Bone Stability with Immediate Implant in Direct Contact versus Gap with Socket Shield: A Randomized Clinical Trial with 1 Year Follow-up. *Clin. Implant. Dent. Rel. Res.* **2022**, *24*, 548–558. [[CrossRef](#)] [[PubMed](#)]
35. Mitsias, M.E.; Siormpas, K.D.; Kotsakis, G.A.; Ganz, S.D.; Mangano, C.; Iezzi, G. The Root Membrane Technique: Human Histologic Evidence after Five Years of Function. *BioMed Res. Int.* **2017**, *2017*, 1–8. [[CrossRef](#)] [[PubMed](#)]
36. Fürhauser, R.; Florescu, D.; Benesch, T.; Haas, R.; Mailath, G.; Watzek, G. Evaluation of Soft Tissue around Single-Tooth Implant Crowns: The Pink Esthetic Score: Esthetic Score. *Clin. Oral Implant. Res.* **2005**, *16*, 639–644. [[CrossRef](#)] [[PubMed](#)]
37. Siormpas, K.D.; Mitsias, M.E.; Kotsakis, G.A.; Tawil, I.; Pikos, M.A.; Mangano, F.G. The Root Membrane Technique: A Retrospective Clinical Study With Up to 10 Years of Follow-Up. *Implant Dent.* **2018**, *27*, 564–574. [[CrossRef](#)] [[PubMed](#)]
38. Bäumer, D.; Zuhr, O.; Rebele, S.; Hürzeler, M. Socket Shield Technique for Immediate Implant Placement—Clinical, Radiographic and Volumetric Data after 5 Years. *Clin. Oral Implant. Res.* **2017**, *28*, 1450–1458. [[CrossRef](#)]

39. Siormpas, K.; Mitsias, M.; Kontsiotou-Siormpa, E.; Garber, D.; Kotsakis, G. Immediate Implant Placement in the Esthetic Zone Utilizing the “Root-Membrane” Technique: Clinical Results up to 5 Years Postloading. *Int. J. Oral Maxillofac. Implant.* **2014**, *29*, 1397–1405. [[CrossRef](#)]
40. Gluckman, H.; Salama, M.; Du Toit, J. A Retrospective Evaluation of 128 Socket-Shield Cases in the Esthetic Zone and Posterior Sites: Partial Extraction Therapy with up to 4 Years Follow-Up. *Clin. Implant. Dent. Relat. Res.* **2018**, *20*, 122–129. [[CrossRef](#)]
41. Kher, U. Surgical Technique for Socket Shield Procedure. In *Partial Extraction Therapy in Implant Dentistry*; Kher, U., Tunkiwala, A., Eds.; Springer International Publishing: Cham, Switzerland, 2020; pp. 17–42. ISBN 978-3-030-33609-7.
42. Cochran, D.L.; Hermann, J.S.; Schenk, R.K.; Higginbottom, F.L.; Buser, D. Biologic Width around Titanium Implants. A Histometric Analysis of the Implanto-Gingival Junction around Unloaded and Loaded Nonsubmerged Implants in the Canine Mandible. *J. Periodontol.* **1997**, *68*, 186–197. [[CrossRef](#)] [[PubMed](#)]
43. Abadzhiev, M.; Nenkov, P.; Velcheva, P. Conventional Immediate Implant Placement and Immediate Placement with Socket-Shield Technique—Which Is Better. *Int. J. Clin. Med. Res.* **2014**, *1*, 176–180.
44. Buser, D.; Weber, H.P.; Donath, K.; Fiorellini, J.P.; Paquette, D.W.; Williams, R.C. Soft Tissue Reactions to Non-Submerged Unloaded Titanium Implants in Beagle Dogs. *J. Periodontol.* **1992**, *63*, 225–235. [[CrossRef](#)] [[PubMed](#)]
45. Gluckman, H.; Salama, M.; Du Toit, J. Partial Extraction Therapies (PET) Part 1: Maintaining Alveolar Ridge Contour at Pontic and Immediate Implant Sites. *Int. J. Periodontics Restor. Dent.* **2016**, *36*, 681–687. [[CrossRef](#)] [[PubMed](#)]
46. Tan, Z.; Kang, J.; Liu, W.; Wang, H. The Effect of the Heights and Thicknesses of the Remaining Root Segments on Buccal Bone Resorption in the Socket-Shield Technique: An Experimental Study in Dogs. *Clin. Implant. Dent. Relat. Res.* **2018**, *20*, 352–359. [[CrossRef](#)] [[PubMed](#)]
47. Page, M.J.; McKenzie, J.E.; Bossuyt, P.M.; Boutron, I.; Hoffmann, T.C.; Mulrow, C.D.; Shamseer, L.; Tetzlaff, J.; Akl, E.; Brennan, S.E.; et al. The PRISMA 2020 Statement: An Updated Guideline for Reporting Systematic Reviews. *MetaArXiv 2020*. Available online: www.prisma-statement.org (accessed on 10 March 2023).

Disclaimer/Publisher’s Note: The statements, opinions and data contained in all publications are solely those of the individual author(s) and contributor(s) and not of MDPI and/or the editor(s). MDPI and/or the editor(s) disclaim responsibility for any injury to people or property resulting from any ideas, methods, instructions or products referred to in the content.