

C A S E R E P O R T

Uterine rupture after previous caesarean section with hysterotomy above the lower uterine segment

Miriam Dellino^{1,2}, Francesco Maria Crupano¹, Xuemin He¹, Antonio Malvasi², Antonella Vimercati¹

¹Department of Biomedical Sciences and Human Oncology, University of Bari, Italy; ²Clinic of Obstetrics and Gynecology, “San Paolo” Hospital, ASL Bari, Bari, Italy

Abstract. *Background and aim* Spontaneous uterine rupture represent a severe obstetrics emergency. Numerous risk factors have been reported, particularly for patients with a previous caesarean section. *Methods:* We described two cases of uterine rupture (UR) arising outside of labour in women with a history of caesarean section (CS) due to placenta previa. *Result:* The present report assesses how a higher hysterotomy, together with specific risk factors, could increase the incidence of UR in the following pregnancy. *Conclusions:* our experience demonstrated that an attentive assessment of risk factors could detect women who need a particular follow up to early identify and treat UR since it could improve the maternal-fetal outcome. (www.actabiomedica.it)

Key words: uterine rupture, placenta previa, high caesarean section, pre-labour, pre-labour, cesarian section-scar to vesicovaginal fold

Introduction

Uterine rupture (UR) represents an irregular area inside the uterine wall, comprising its serosa (over-lying peritoneum) and probably implicating the bladder and wide ligament (1). Uterine dehiscence frequently precedes UR, but it does not involve the serosa. Indeed, uterine dehiscence thus keeping fetus and placenta internal to the uterus with an inferior rate of maternal-fetal complications (2). UR is a severe obstetrics complication, that can be correlated to neonatal and maternal an adverse outcome (3). Recently, the frequency of UR has considerably augmented both in patients without a prior hysterotomy (especially after labour management) and women with a previous caesarean section (CS) (4). Despite in literature there are debated opinions, precise risk factors of UR are evaluated (5). Consequently, following to the increasing rate of CS in recent years from 6.7% to 19.1%, we easily comprehend how the occurrence of

UR among patients with a previous CS increased from 0.22 to 0.5% in developed countries (6). Few works in the literature report the previous placenta previa as a risk for UR. On the other hand, placenta accreta spectrum, indicates to the range of pathologic adherence of the placenta, involving placenta increta, placenta percreta, and placenta accrete (7). Moreover, cesarean scar pregnancy (CSP) is described as the implantation of a gestational sac within the scar of a previous cesarean surgery. In case of placenta accreta spectrum the ideal management includes a standardized approach with a complete multidisciplinary care team that could include hemodynamic approach with embolization treatment (8). Indeed, a multidisciplinary approach, including a single-surgery protocol with multivessel uterine embolization is related with a decrease in blood transfusion necessities, blood loss with and consequently improvement of maternal post-operative morbidity (9). We would report our experience: two cases of spontaneous UR outside of labour in women

with a previous CS following to prenatal diagnosis of placenta previa. In both case hysterotomy was executed more cranially since lower placental insertion and far from the low uterine segment (LUS). Fetal outcome and patients' characteristics are summarised in Table 1.

Both women are being accurately informed about the use of their personal data for scientific reasons, under the protection of the Privacy Act, and they accepted and signed a related informed consent.

Case presentation

Case 1:

A 34-year-old patient, parity 0/1/0/1, with a previous pregnancy (November 2017) and central placenta previa at 35 weeks of gestational age (GA) that we we had identified using ultrasound (Figure 1 a). Therefore, elective CS with transverse hysterotomy was performed more cranially than usual since a placental flap was extending anteriorly over the LUS (Figure 1b). In March 2019, the patient, 22 weeks pregnant,

go to our clinic to perform a voluntary termination of pregnancy. After the first administration of misoprostol (400 mcg), she referred moderate abdominopelvic pain: she was pale, asthenic but conscious with BP: 100/65 mmHg, HR: 100bpm, obstetric shock index (OSI): 0.9 (normal value <1). No vaginal bleeding or amniotic fluid leakage are described; Transvaginal scan reported: cervical length of 3,5 cm. On the other hand, trans-abdominal scan revealed: fetus devoid of cardiac activity expelled in the abdomen, with empty uterine cavity (Figure 1c). Moreover, an anterior irregularly implanted placenta with free fluid into the Morison, Douglas and the recto-uterine pouch was described. Therefore, an emergency CS was performed and opening the abdomen, lower midline incision, was executed accurate drainage of 1000 ml of blood and the gestational sac and placenta were almost completely detached from the uterine wall so were removed and the breach was closed with interrupted stitches. After that a good control of haemostasis was attained, and this allowed a conservative approach.

The haemoglobin level decreased from 9.7 gr/dL before surgery to 8.6 gr/dL after surgery and finally

Table 1. Case reports characteristics pf spontaneous UR in women with a CS for placenta previa

	Case 1	Case 2
Age	34	31
Parity	0/1/0/1	1/0/0/1
GA at the diagnosis of UR	22w	37w
RU Symptomatology	Abdominal-pelvic pain, vaginal painful, asthenic	Severe abdominal-pelvic pain, vaginal painful, pale nervous
BP, OSI and HR duringUR	BP:100/65 mmHG HR:100 bpm- OSI: 0,9	BP: 95/55 mmHG HR: 85 bpm OSI: 0,8
Ultrasonic picture of UR	Fetus expelled in the abdomen	Heart activity, fetal movements and normal amniotic fluid, irregular implant placental
CTG during UR	/	Bradycardia (85 bpm) - no uterine contraction
Management	Conservative	Conservative
Unit of pRBC/plasma	3pRb	3pRb/1 plasma
Day of discharge	Five	Seven
Fetal outcome	Fetal Death	Apgar 7/8-PH:6,9 -lactate: 13mmol/l- BE: 17mmol/L
Site of previous CS	Above the LUS	Above the LUS
Time of prevoius CS	35 w	38w

CS: cesarian section, LUS:lower uterine segment,GA: gestational age, UR:uterine rupture

BP: blood pressure, HR: heart rate, OSI:obstetrics shock index, CTG: cardiotocografy FHR:fetal heart rate, pRBC: packed red blood cells

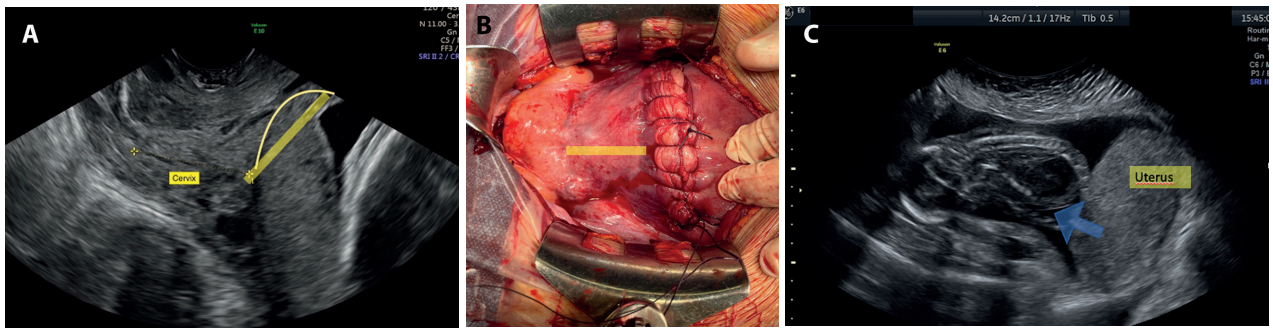


Figure 1. Case 1:

- a) Ultrasound evaluation with placenta previa which goes up on the anterior uterine wall for 50 mm (yellow line)
- b) High hysterorrhaphy and distance from uterine vesicular plica (yellow line)
- c) Rupture of uterus on scar (blue arrow) at 22 weeks and expulsion fetus in the abdomen

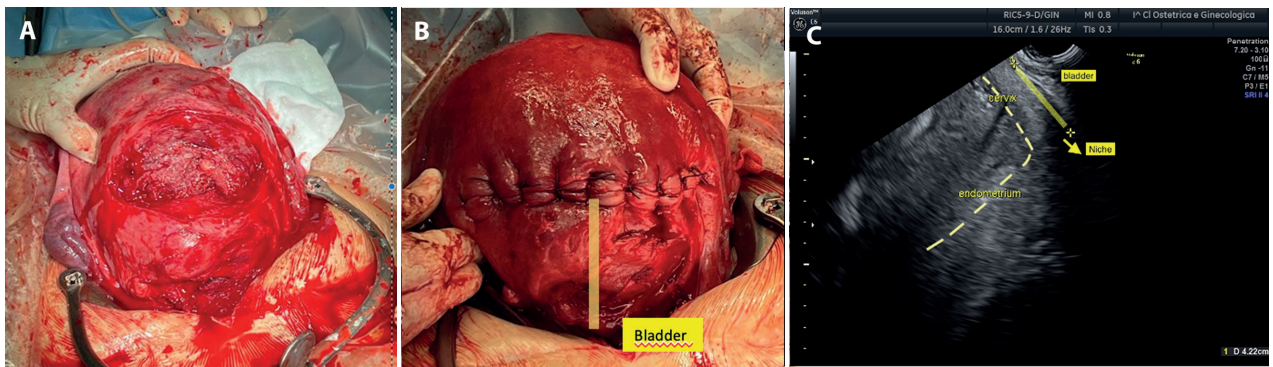


Figure 2. Case 2:

- a) Transversal hysterotomy above the LUS in precedent pregnancy (2017)
- b) Hysterorrhaphy performed 45 mm above bladder fold (yellow line)
- c) Six months post CS-US evaluation shows sagittal scan retro-verse uterus with scar -bladder fold distance of 42,2 mm

to 7.6 gr/dL the second post-operative day. Consequently, first intravenous iron and then three units of packed red blood cells (pRBC) were requested. The patient was discharged on day five and prescribed home therapy with antibiotics, antithrombotic, iron and uterotonic. At the end, histological analysis revealed the presence of scar tissue over the breach edges.

Case 2:

A 31-year-old patient with no relevant medical history, parity 1/0/0/1. In October 2017,

We performed her an elective CS at 38 weeks, for a prenatal diagnosis of anterior placenta previa. Indeed, an ultrasound assessment executed during the next pregnancy, at 8 weeks of gestational age, revealed the

higher CS scar location (Figure 2). Therefore, a transversal hysterotomy was affected above the LUS (Figure 2a) and the hysterorrhaphy performed at the top 45 mm from the bladder fold (Figure 2b). After six 6 months from the caesarean section, the patient underwent a follow-up and we previously evaluated in sagittal scan the of CS -scar to vesicovaginal fold (VVF) distance, (42 mm-Figure 2c). In June 2019, patient was to 37 weeks and suddenly she filed a severe abdominopelvic pain. She remained conscious, asthenic, and pale with HR: 85bpm, BP: 95/55 mmHg (OSI: 0.8). The abdominal palpation and digital evaluation of the vaginal fornix was painful. Moreover, when pouch of Douglas and the cervix was explored no vaginal bleeding or amniotic fluid leakage was observed. The CTG examination underlined a fetal bradycardia (85 bpm for 7

minutes) and no uterine contractions; a transabdominal ultrasound scan confirms the fetal bradycardia. Consequently, an emergency CS with a Pfannenstiel laparotomy over the previous scar was performed. After that, an open uterine breach with initial opening of the amniotic sac was found, so fetus was immediately extracted and entrusted to the care of neonatologists. Analyses the gas of umbilical artery blood (Apgar 7/8-PH:6, 9 -lactate: 13mmol/l- BE:- 17 mmol/L). After abstracted the placenta, a large breach over the middle third of the anterior wall was stitched with interrupted stitches, getting a good haemostasis and a conservative approach. Three units of pRBC and one units of plasma were instilled during the surgery to balance the massive amount of blood collected into the abdomen. The patient was discharged on day seven, and recommended home therapy with iron, antithrombotic and antibiotics. Concerning fetal outcome, a Magnetic resonance imaging (MRI) executed 30 days after birth, detected no signs of hypoxic-ischemic encephalopathy.

Discussion

UR frequently have higher incidence during late gestational age and usually involves the LUS area (scarred uterus 93% - unscarred uterus 62%), since it is less resistant than the uterine corpus and fundus (10). UR is often an intraoperative diagnosed pregnancy complication that could be supposed by execution a detailed gynaecological and ultrasound examination, but only a surgical evaluation can usually confirm the diagnosis (11). Furthermore, the clinical onset is frequently nonspecific, could becoming more typical with abdominal pain, absence of fetal heart activity, haemorrhagic shock (9). The first case presented with a specific clinical characteristic and the ultrasound evaluation was supportive of diagnosis. The timely surgery reduced the risk of maternal complications, but the fetal outcome was determinate from the early gestational age (22 weeks). In second case reported, ultrasound evaluation showed signs of fetal suffering (bradycardia) with aspecific symptomatology. Consequently, according to our experience and knowledge of literature, to improve the maternal-fetal outcome, high-risk patients should be evaluated early in preconceptional times to

select women at risk and perform serious follow-ups and the obstetric emergencies timely diagnostic recognition. (previous CS, abdominal pain, sickness, signs of peritoneal irritation and pelvic effusion) should be rapidly recognized and referred to adequate obstetric emergency units for urgent surgical treatment (12). Indeed, literature was described a statistically increased prevalence of UR following a fundic hysterotomy, metroplasty or fetal surgery (14% for both uterine dehiscence and UR) (13). On the other hand, a low transverse uterine incision over the LUS is connected to a low risk (0.4-0.7%). While a previous T or J uterine incision increase the risk of UR from 4% to 9% (11). In case transverse incision risk of UR is greater than 5 times and doubles in case di earlier vertical incision over the LUS (10). Regarding the consequences of a "high" transverse incision over the LUS are not well listed. Some Authors give it no importance, while others described that every incision of the uterine contractile tissue increases the possibility of UR (2). Moreover, in literature was report that the presence of a higher uterine incision due to placenta previa seems to be correlated with a major risk of UR. Particularly, periconceptional US examination of CS -scar to VVF distance, (which represents the level of the previous CS), appears to be a suitable to predict risk of pre-labor UR (14). Therefore, from 5 years, we are studying patients with placenta previa history, during preconception time and we systematically perform the measurement of the CS -scar to VVF distance. Indeed, ultrasound measurement of CS -scar to VVF can allow you to locate patients with a high risk of UR, both during preconception counselling and early pregnancy (14). In fact, of the second case, we followed the patient in the center for risk pregnancy and we had evaluated the presence of a CS -scar to VVF of 42.2 mm and we followed her in close follow-up. Consequently, we performed an early diagnosis, with a satisfying maternal and fetal outcome. While in the first case, being an unexpected pregnancy, the patient did not adhere to recommended preconceptionally follow-ups, but by virtue of history also in this case the diagnosis was timely. In addition to this evaluation, an anamnestic assessment of all other risk factors should also be performed. Therefore, the relevant of detailing the height of a CS scar in the patient's discharge letter becomes obviously evident, to plan a

proper management and follow up of the next pregnancy. Indeed, the amount of time from the last CS or the absence of a cervical dilatation without a full uterine drainage, represent further risk factor of UR(15); Regarding time of CS, in current literature, a standard 'safe' range of time is not specified but some Authors studies suggest a 6-to-19-month period, other studies recommended an interval of 12 or 18 months(16). In an observational study focuses on on 1500 women, excluding all the biases (epidural anaesthesia, type of stitches, oxytocin induction) but still maintaining an odds ratio for UR of 2.65 (95% CI 1.08-6.46), reported that a period of 24 months appears safe (17). Therefore, during counselling patients with a previous CS, exhaustive information about the short and long-term UR risks factors should be examined and collected, including the type of hysterotomy executed, the length of time (less than 18- 24 months) since the last CS (18). Moreover, for women who reported a high hysterotomy, through ultrasounds evaluation, CS -scar to VVF distance can be measured (19).

This US evaluation is not yet standardized but it could identify preconceptionally, the height of the CS scar to evaluate the risk of UR (20). Moreover, ongoing pregnancies should be examined for all the probable anamnestic risk factors: motive for CS, range of time from the last pregnancy, and type of hysterotomy, additional uterine operations, emergency or elective surgery, range of time from the last pregnancy (21). As in the cases reported, through this approach is possible to perform a proper risk assessment and plan serial follow-ups to detect and treat a possible UR early (22). This could reduce the time between diagnosis and surgery since during the emergence the most important factor improve maternal and fetal outcome is timeliness (23).

Conflict of Interest: Each author declares that he or she has no commercial associations (e.g. consultancies, stock ownership, equity interest, patent/licensing arrangement etc.) that might pose a conflict of interest in connection with the submitted article

References

1. Soltsman S, Perlitz Y, Ben Ami M, Ben Shlomo I. Uterine rupture after previous low segment transverse cesarean is rarely catastrophic. *J Matern Fetal Neonatal Med* 2018; 31:708-712.
2. Habeš D, Střecha M, Kalousek I, Kestřánek J. Uterine rupture during pregnancy. *Ceska Gynekol* 2019; 84:345-350.
3. Ronel D, Wiznitzer A, Sergienko R, Zlotnik A, Sheiner E. Trends. Risk factors and pregnancy outcome in women with uterine rupture. *Arch Gynecol Obstet* 2012; 285:317-321.
4. Ofir K., Sheiner E, Levy A, Katz M., Mazor M. Uterine rupture: risk factors and pregnancy outcome. *Am. J. Obstet. Gynecol* 2003;1042-1046.
5. Lannon, S. M., Guthrie, K. A., Vanderhoeven, J. P., Gammill, H. S. Uterine rupture risk after periviable cesarean delivery. *Obstet. Gynecol* 2015; 125:1095-1100. 10.1097/AOG.0000000000000832.
6. Al-Zirqi, I., Stray-Pedersen, B., Forsén, L., Daltveit, A.K., and Vangen, S. Uterine rupture:trends over 40 years. *BJOG* 2016;123: 780-787.
7. Al-Zirqi I, Daltveit AK, Forsén L, Stray-Pedersen B, Vangen S. Risk factors for complete uterine rupture. *Am J Obstet Gynecol* 2017; 216:165.
8. Melber DJ, Berman ZT, Jacobs MB, et al. Placenta Accreta Spectrum Treatment With Intraoperative Multivessel Embolization: the PASTIME protocol. *Am J Obstet Gynecol* 2021 Oct;225(4):442.e1-442.
9. Buonomo B, Massarotti C, Dellino et al. Reproductive issues in carriers of germline pathogenic variants in the BRCA1/2 genes: an expert meeting. *BMC Med* 2021 Sep 10;19(1):205.
10. Dellino M, Silvestris E, Loizzi V, et al. Germinal ovarian tumors in reproductive age women: Fertility-sparing and outcome. *Medicine (Baltimore)* 2020 Sep 25;99(39): e22146.
11. Silvestris E, Cormio G, Skrypets T, et al. Novel aspects on gonadotoxicity and fertility preservation in lymphoproliferative neoplasms. *Crit Rev Oncol Hematol* 2020 Jul; 151:102981.
12. Silvestris E, Dellino M, Cafforio P, Paradiso AV, Cormio G, D'Oronzo S. Breast cancer: an update on treatment-related infertility. *J Cancer Res Clin Oncol* 2020 Mar;146(3):647-657.
13. Silvestris E, D'Oronzo S, Cafforio P, et al. In Vitro Generation of Oocytes from Ovarian Stem Cells (OSCs): In Search of Major Evidence. *Int J Mol Sci* 2019 Dec 10;20(24): 6225.
14. Vimercati A, Dellino M, Crupano FM, Gargano G, Ciccinelli E. Ultrasonic assessment of cesarean section scar to vesicovaginal fold distance: an instrument to estimate pre-labor uterine rupture risk. *J Matern Fetal Neonatal Med* 2021 Jan 4:1-5.
15. Silvestris E, De Palma G, Canosa S, et al. Human Ovarian Cortex biobanking: A Fascinating Resource for Fertility Preservation in Cancer. *Int J Mol Sci* 2020 May 4;21(9):3245.
16. Dellino M, Minoia C, Paradiso AV, De Palo R, Silvestris E. Fertility Preservation in Cancer Patients During the Coronavirus (COVID-19) Pandemic. *Front Oncol* 2020 Jun 4; 10:1009.

17. Date S, Murthy B, Magdum A. Post B-lynch uterine rupture: case report and review of literature. *J Obstet Gynaecol India* 2014; 64:362-363
18. La Rosa VL, Valenti, G, Sapia F et al. Psychological impact of gynecological diseases: the importance of a multidisciplinary approach. *J Gynaecol Obstet* 2018; 3030(2):23-26.
19. Dellino M, Crupano FM, Rossi AC, et al. Relationship between prelabour uterine rupture and previous placenta previa diagnosis: case reports and review of literature *Italian Journal of Gynaecology and Obstetrics* 2022; Vol. 34 (No. 1) 48-53.
20. A. Privitera, M. Fiore, G. Valenti, et al. The role of serum potassium and sodium levels in the development of postpartum hemorrhage. A retrospective study. *J Gynaecol Obstet*; Vol. 32 (No. 2) 2020 June, 126-135.
21. Tanos V, Toney ZA. Uterine scar rupture - Prediction, prevention, diagnosis, and management. *Best Pract Res Clin Obstet Gynaecol* 2019; Aug;59:115-131.
22. Zhou Q, Zhou X, Feng L, Wang SS. Complete Rupture of the Pregnant Uterus: A 10-year Retrospective Descriptive Study. *Curr Med Sci* 2022 Feb;42(1):177-184.
23. Marwah S, Singh S, Bharti N, Gupta PK. Risk Factors and Outcome Analysis in Rupture of Gravid Uterus: Lessons for Obstetricians. *Cureus* 2022 Feb 3;14(2):e21890.

Correspondence:

Received: 5 February 2022

Accepted: 31 May 2022

Miriam Dellino, MD

Department of Biomedical Sciences and Human Oncology,

Policlinic of Bari, University of Bari

Piazza Aldo Moro

Bari, 70100

Phone: +393462434273

E-mail: miriamdellino@hotmail.it