

● *Original Contribution*

## ULTRASOUND VERSUS COMPUTED TOMOGRAPHY ASSESSMENT OF FOCAL LUNG AERATION IN INVASIVELY VENTILATED ICU PATIENTS

MARRY R. SMIT,<sup>\*†</sup> LUIGI PISANI,<sup>\*‡</sup> EVA J.E. DE BOCK,<sup>\*†</sup> FERDINAND VAN DER HEIJDEN,<sup>†,§</sup>  
FREDERIQUE PAULUS,<sup>\*</sup> LUDO F.M. BEENEN,<sup>¶</sup> STIJE J. LEOPOLD,<sup>‡,||</sup> MICHAËLA A.M. HUSON,<sup>#</sup>  
PATRICIA C. HENWOOD,<sup>h</sup> ELISABETH D. RIVIELLO,<sup>i</sup> ANDREW P. WALDEN,<sup>‡‡</sup> ARJEN M. DONDORP,<sup>\*‡</sup>  
MARCUS J. SCHULTZ,<sup>\*,‡,§§</sup> LIEUWE D.J. BOS<sup>\*</sup> and for the Lung Ultrasound Consortium

<sup>\*</sup> Department of Intensive Care, Amsterdam UMC, location AMC, Amsterdam, The Netherlands; <sup>†</sup> Technical Medicine Centre, University of Twente, Enschede, The Netherlands; <sup>‡</sup> Mahidol–Oxford Tropical Medicine Research Unit (MORU), Mahidol University, Bangkok, Thailand; <sup>§</sup> Department of Robotics and Mechatronics, University of Twente, Enschede, The Netherlands; <sup>¶</sup> Department of Radiology and Nuclear Medicine, Amsterdam UMC, location AMC, Amsterdam, The Netherlands; <sup>||</sup> Department of Internal Medicine, Amsterdam UMC, location AMC, Amsterdam, The Netherlands; <sup>#</sup> Department of Medical Microbiology and Infectious Diseases, Erasmus Medical Center, Rotterdam, The Netherlands; <sup>h</sup> Emergency Medicine Department, Brigham and Women's Hospital, Boston, Massachusetts, USA; <sup>i</sup> Division of Pulmonary, Critical Care and Sleep Medicine, Beth Israel Deaconess Medical Center and Harvard Medical School, Boston, Massachusetts, USA; <sup>‡‡</sup> Department of ICU, Royal Berkshire Hospital, Reading, United Kingdom; and <sup>§§</sup> Nuffield Department of Medicine, University of Oxford, Headington, Oxford, United Kingdom

(Received 21 January 2021; revised 23 April 2021; in final form 25 May 2021)

**Abstract**—It is unknown whether and to what extent the penetration depth of lung ultrasound (LUS) influences the accuracy of LUS findings. The current study evaluated and compared the LUS aeration score and two frequently used B-line scores with focal lung aeration assessed by chest computed tomography (CT) at different levels of depth in invasively ventilated intensive care unit (ICU) patients. In this prospective observational study, patients with a clinical indication for chest CT underwent a 12-region LUS examination shortly before CT scanning. LUS images were compared with corresponding regions on the chest CT scan at different subpleural depths. For each LUS image, the LUS aeration score was calculated. LUS images with B-lines were scored as the number of separately spaced B-lines (B-line count score) and the percentage of the screen covered by B-lines divided by 10 (B-line percentage score). The fixed-effect correlation coefficient ( $\beta$ ) was presented per 100 Hounsfield units. A total of 40 patients were included, and 372 regions were analyzed. The best association between the LUS aeration score and CT was found at a subpleural depth of 5 cm for all LUS patterns ( $\beta = 0.30$ ,  $p < 0.001$ ), 1 cm for A- and B1-patterns ( $\beta = 0.10$ ,  $p < 0.001$ ), 6 cm for B1- and B2-patterns ( $\beta = 0.11$ ,  $p < 0.001$ ) and 4 cm for B2- and C-patterns ( $\beta = 0.07$ ,  $p = 0.001$ ). The B-line percentage score was associated with CT ( $\beta = 0.46$ ,  $p = 0.001$ ), while the B-line count score was not ( $\beta = 0.07$ ,  $p = 0.305$ ). In conclusion, the subpleural penetration depth of ultrasound increased with decreased aeration reflected by the LUS pattern. The LUS aeration score and the B-line percentage score accurately reflect lung aeration in ICU patients, but should be interpreted while accounting for the subpleural penetration depth of ultrasound. (E-mail: [m.r.smit@amsterdamumc.nl](mailto:m.r.smit@amsterdamumc.nl)) © 2021 The Author(s). Published by Elsevier Inc. on behalf of World Federation for Ultrasound in Medicine & Biology. This is an open access article under the CC BY license (<http://creativecommons.org/licenses/by/4.0/>).

**Key Words:** Lung ultrasound, Computed tomography, Mechanical ventilation, Critical care, Lung aeration.

### INTRODUCTION

Monitoring of lung aeration in intensive care unit (ICU) patients under invasive ventilation is important in understanding the nature of respiratory failure, its evolution

and the response to interventions and changes in ventilator settings (Xirouchaki et al. 2014). A precise measure of lung aeration is the ratio between lung mass and volume, or “lung density.” Lung density increases when the lung deflates (atelectasis) or when interstitial or alveolar mass increases (Kruisselbrink et al. 2017). The gold standard for measuring lung aeration is chest computed tomography (CT) as it provides a quantitative density

Address correspondence to: Marry R. Smit, Department of Intensive Care, Amsterdam UMC, location AMC, Meibergdreef 9, 1105 AZ Amsterdam, The Netherlands. E-mail: [m.r.smit@amsterdamumc.nl](mailto:m.r.smit@amsterdamumc.nl)

estimation (Gattinoni et al. 2001). However, performing a CT scan in ICU patients under invasive ventilation poses important challenges, including risks associated with transport to the CT scanner and exposure to radiation (Baldi et al. 2013).

Lung ultrasound (LUS) has gained popularity for monitoring and diagnosing pulmonary complications in mechanically ventilated ICU patients, as it is a radiation-free technique and can be repeated often (Bouhemad et al. 2010; Shyamsundar et al. 2013; Mongodi et al. 2016). Moreover, LUS allows for a quick evaluation of the lungs at the bedside and therefore avoids the need for time-consuming and risky transportation to the radiology department. Density of lung tissue underneath the probe can be semiquantified using the LUS aeration score, which relies on specific ultrasound patterns. “A-Line” artifacts suggest the presence of normally aerated lung tissue, while “B-lines” are vertical artifacts indicating less aerated lung tissue. In case of complete loss of aeration, the lung is observed as an anatomical image of partial or lobar consolidation (Lichtenstein and Mezière 2008).

As the presence of B-lines encompasses mild to severe impairment of lung aeration, several scoring methods have been proposed for B-line semiquantification. These have been compared with extravascular lung water measured by thermodilution (Agricola et al. 2005; Bataille et al. 2015) and CT at a global lung level (Baldi et al. 2013), while we often need to characterize lung pathology associated with B-patterns at a focal level. Moreover, it remains uncertain whether B-lines can and should be “counted” as an absolute number or whether estimation of the percentage of the screen covered by B-lines is preferable (Soldati et al. 2011; Zanforlin et al. 2014).

LUS is theoretically confined to visualizing the subpleural layer of the lung because of the high dissipation of ultrasound beams in aerated lung tissue (Volpicelli et al. 2012), although this theory has not been validated with the gold standard chest CT. Comparison on a regional level of the studies by Chiumello et al. (2018, 2019) revealed a good correlation between the LUS aeration score and aeration measured by CT, but these studies made broad assumptions by analyzing whole lung regions on CT and using the worst LUS pattern found in a region. As LUS assessments of focal or diffuse interstitial syndromes can drive clinical decisions, such as antibiotic therapy, diuretics or positive end-expiratory pressure titrations, it is important to understand until which subpleural depth the lung can be assessed through LUS in both the normal and the pathological lung (Bouhemad et al. 2010, 2011; Mozzini et al. 2018).

The current study evaluated and compared the LUS aeration score and two frequently used B-line scores

with focal lung aeration assessed by chest CT at different levels of depth in invasively ventilated ICU patients. We hypothesized that the penetration depth of LUS increases with decreasing lung aeration. The second hypothesis was that the LUS aeration score, as well as the B-line scores, are significantly associated with focal lung aeration measured by chest CT.

## METHODS

### *Study design and ethical concerns*

This prospective observational study was performed in the ICU of the Amsterdam University Medical Centers, location Academic Medical Center, Amsterdam, The Netherlands. The institutional review board of the Academic Medical Center approved the study protocol (2017\_312#B201859). A total of 40 consecutive patients were included. Written informed consent was obtained from the patients’ representatives before enrollment.

### *Patients*

Patients were eligible if (i) under invasive ventilation and (ii) scheduled for chest CT scan for any clinical indication, which was not prescribed by the study protocol. Patients less than 18 y of age, patients for whom written informed consent could not be obtained on time and patients with known allergies to skin adhesives used for marking the exact location of lung regions were excluded from participation.

### *Study procedure*

The chest CT was ordered by the treating physician as part of clinical care. Then, patients underwent a comprehensive LUS exam in the last minutes before transport to the CT scanner while already connected to the transport ventilator. Thus, patients were not disconnected from the ventilator between the LUS and chest CT exams, and ventilator settings were left unchanged between the two exams. If it was necessary to change ventilator settings, LUS was repeated immediately after return from the chest CT scan while still connected to the transport ventilator. In that case, only the latter images were used for comparisons.

Self-adhesive radiopaque lead skin markers (Suremark, Simi Valley, CA, USA) were placed at the regions scanned with LUS, to ensure a direct comparison between LUS and CT images. These skin markers were placed on the medial side of the probe immediately after an LUS image was saved (Fig. 1a, arrow).

### *LUS examination*

LUS was performed by trained sonographers using a standard ultrasound machine (LOGIQ e, GE Healthcare, Milwaukee, WI, USA) and a high-frequency linear probe

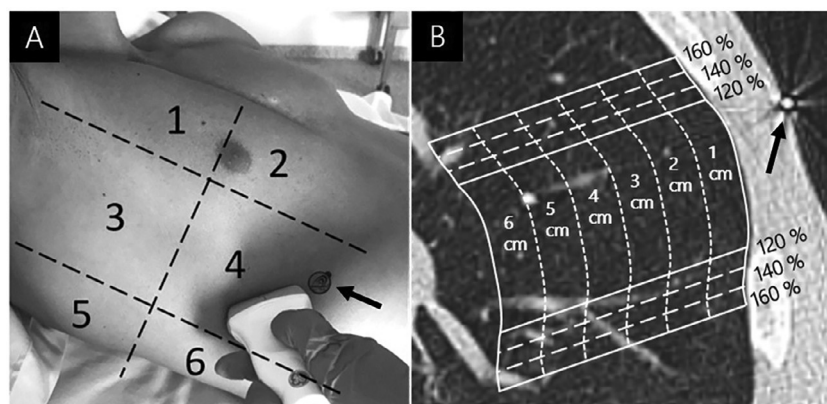


Fig. 1. (a) Scanned lung regions and placement of radio-opaque markers (*arrow*) used to identify LUS regions on the CT image. (b) Radio-opaque marker including the corresponding lung region for different probe footprints and depths that were analyzed in CT. Multiple CT slices were analyzed per lung region. CT = computed tomography; LUS = lung ultrasound.

(Park *et al.* 2017; Goffi *et al.* 2018). LUS images were saved as a 5-s video loop at 18 frames/s and exported in Digital Imaging and Communications in Medicine format. Ultrasound machine settings were protocolized and homogeneous throughout the study (gain: 50, depth: 8 cm, frequency: 7 MHz, time-gain compensation: increased from 0 to 100% with depth, auto-optimization: off).

A 12-region approach was used in which 6 areas on each hemithorax (*i.e.*, 2 ventral regions, 2 lateral regions and 2 posterolateral regions) were scanned, with a transverse approach between the ribs to maximize lung exposition and minimize rib-related artifacts (Fig. 1a) (Mongodi *et al.* 2017). Patients were in a supine or semi-recumbent position with the arms elevated above the head to ensure identical arm position during LUS and CT.

All LUS images were scored by sonographers with extensive expertise in LUS, who remained blind to clinical information as well as findings on the chest CT scan. An “A-pattern” was defined as repeating horizontal lines parallel to the pleural line (score 0). A “B1-pattern” was defined as three or more vertical separated B-lines starting from the pleural line and reaching the bottom of the screen (score 1). A “B2-pattern” was defined as numerous confluent vertical B-lines covering more than 50% of the screen (score 2). A “C-pattern” was defined as a hypo-echoic structure with a diameter of at least 2 cm (score 3). When multiple patterns were visible in one LUS clip, the pattern with the worst aeration and thus highest aeration score was used (Bouhemad *et al.* 2007; Soummer *et al.* 2012; Caltabeloti *et al.* 2014; Chiumello *et al.* 2018).

#### Chest CT scanning

Chest CT scans were acquired with a Somatom AS+ sliding gantry CT scanner (Siemens Healthineers, Erlangen, Germany) with patients in the supine position. CT

settings were set according to clinical protocols (tube voltage: 100–120 kV; mean voxel volume: 0.782 mm<sup>3</sup> (range: 0.268–2.606 mm<sup>3</sup>); slice thickness: 1 and 3 mm).

In lung regions on CT that correspond to the lung regions scanned during LUS, lung aeration was quantified based on mean attenuation values measured in Hounsfield units (HU). The range –1000 to –901 HU in CT was considered hyperinflated lung, that from –900 to –501 HU as normally aerated lung, that from –500 to –101 HU as poorly aerated lung and that from –100 to 100 HU as non-aerated lung (Gattinoni *et al.* 2006). Selection of a 3-D region of interest (ROI) in lung tissue on the CT scan and calculation of the mean HU value of that specific region were performed using software developed in MATLAB Release 2018a (The MathWorks Inc., Natick, MA, USA). In multiple slices, the pleura between the ribs was delineated based on the radiopaque skin markers placed during the LUS study, as these corresponded to the regions examined with LUS (Fig. 1a, 1b). For each LUS region, different ROIs were assessed with CT using multiple depths and probe footprint sizes (Fig. 1b). The subpleural depth of the ROI was varied from 1 cm to the maximum depth of the ultrasound image (fixed depth of 8 cm minus the thickness of the subcutaneous layer in the LUS image). Tissue and structures that were not part of the lung parenchyma were excluded from the ROI. The initial delineation of the pleura between the ribs was considered as a probe footprint of 100%. To assess the uncertainty of the radiopaque skin marker caused by transfer of the patient and the respiratory cycle, the probe footprint was enlarged to 160% in steps of 20% (Fig. 1b).

#### B-Line scoring

For each LUS image with a B-pattern, two semi-quantitative visual scores were calculated that were

previously used in an ICU population. For the B-line count score, separated B-lines were counted without setting an arbitrary plateau used for LUS images with extensive confluency (Jambrik et al. 2004; Agricola et al. 2005; Bilotta et al. 2013; Theerawit et al. 2014; Bataille et al. 2015). For the B-line percentage score, B-lines were also counted when separated, but when a confluent B-line pattern was observed the percentage of the screen covered by B-lines was estimated, which was then divided by 10 (Baldi et al. 2013; Corradi et al. 2016; Davids et al. 2016). This score has previously been described by the international LUS consensus conference (Volpicelli et al. 2012).

### Study endpoint

The primary endpoint was the association between LUS aeration score and focal lung aeration expressed in HU for the corresponding areas on the chest CT scan, for different combinations of subpleural depth and probe footprint size. The secondary endpoints were (i) the primary endpoint analyzed in subgroups based on the LUS pattern (A + B1, B1 + B2 and B2 + C patterns), and (ii) the association between the B-line scores and focal lung aeration assessed in corresponding areas on the chest CT scan, for different combinations of subpleural depth and probe footprint sizes.

### Statistical analysis

Data are expressed as the median (interquartile range [IQR]) for numerical variables and as the absolute number (percentage) for frequency variables. Linear mixed-effect model analysis was used to assess the associations between focal lung aeration measured by chest CT scan and LUS scores for different combinations of subpleural depth and probe footprint sizes. Focal lung aeration measured by chest CT was used as the independent variable and a random intercept per patient was used as multiple images were obtained from each patient. For the linear mixed-effect model, focal lung aeration measured by CT (HU) was divided by 100 to obtain interpretable results for the fixed-effect regression coefficient  $\beta$  ( $\beta$  = change in LUS score per 100 HU). An increase in the  $\beta$  represents an improved association between LUS and CT in estimating lung aeration. Subgroup analyses were performed in groups of two neighboring LUS patterns, as at least two different scores are necessary to determine associations.

Inter-observer variability for the LUS aeration score was assessed on a random subset of 60 images. Similarly, for B-line scoring, inter-observer variability was performed on 26 B-pattern images. The inter-observer agreement on the assessment of the LUS aeration score was tested with Cohen's  $\kappa$  statistics. For the B-line

scores, the intra-class correlation coefficient (ICC) was calculated to determine the reliability of the rating with a two-way model, agreement type with a 95% confidence interval (CI). Intra-class correlation coefficients of <0.30, 0.30–0.49, 0.50–0.69, 0.70–0.89 and >0.90 were considered as poor, fair, moderate, strong and near perfect, respectively.

Statistical analysis was performed with MATLAB Release 2018a and R Version 3.3.1 ([www.r-project.org](http://www.r-project.org)). Graphs were built in GraphPad Prism Version 7.03 ([www.graphpad.com](http://www.graphpad.com)). A  $p$  value < 0.05 was considered to indicate significance.

## RESULTS

### Patients

From 15 February 2018 until 25 June 2019, 40 patients were included, 37 of whom were analyzed. Three patients were excluded from the analysis because the chest CT scan could not be analyzed, or the quality of LUS images was insufficient. Patient flow is illustrated in Figure 2, and patient characteristics are summarized in Table 1.

Because 72 (16%) lung regions could not be scored by LUS because of the presence of surgical dressings, subcutaneous emphysema, chest tubes or a large amount of subcutaneous fat tissue, a total of 372 LUS regions were analyzable. For the deeper subpleural assessment in CT, data were missing because of the thickness of the subcutaneous layer or the presence of other organs in the ROI (percentage of missing data: <1% for 4 cm, 6% for 5 cm, 34% for 6 cm and 81% for 7 cm). For this reason, data are presented until a subpleural depth of 6 cm.

### LUS aeration

Examples of LUS images of A-, B1-, B2- and C-patterns and corresponding CT images are shown in Figure 3. The LUS aeration score and HU from CT for each subpleural depth using the original probe footprint (100%) are illustrated in Figure 4. Combining all LUS patterns revealed that the highest association between the LUS aeration score and focal lung aeration measured by CT was at a subpleural depth of 5 cm with a probe footprint of 160% (fixed-effect regression coefficient  $\beta$ : 0.30 per 100 HU [95% CI: 0.26–0.35],  $p$  < 0.001). For subgroups based on LUS patterns, the highest association between the LUS aeration score and focal lung aeration measured by CT was found at a depth of 1 cm with a probe footprint of 100% for A- and B1- patterns ( $\beta$  = 0.10 per 100 HU [95% CI: 0.06–0.13],  $p$  < 0.001), a depth of 6 cm with a probe footprint of 120% for B1- and B2- patterns ( $\beta$  = 0.11 per 100 HU [95% CI: 0.05–0.17],  $p$  < 0.001) and a depth of 4 cm with a probe footprint of 160% for B2- and C-patterns ( $\beta$  = 0.07 per

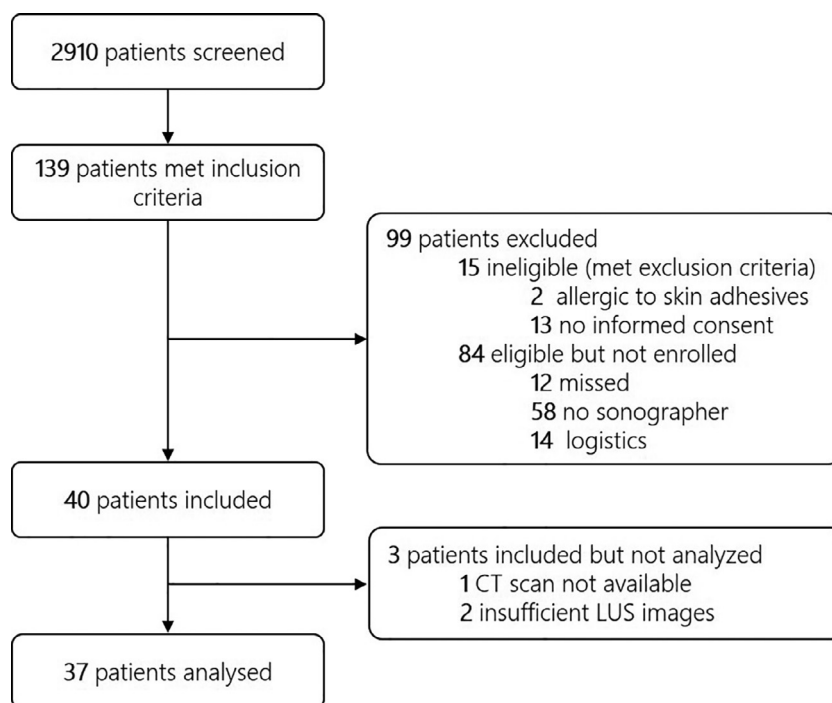


Fig. 2. Study flowchart.

100 HU [95% CI: 0.03–0.11],  $p = 0.001$ ).  $\beta$  Values for all combinations of probe footprints and subpleural depth are provided in Supplementary Figure S1 (online

only). The  $\kappa$  statistic for inter-observer agreement for the LUS aeration score was 0.70.

#### B-Line scores

Examples of LUS images with B-patterns and B-line scores are provided in Figure 3. The B-line scores and HU from CT are presented in Figure 5 for a subpleural depth of 6 cm and a probe footprint size of 120%, which provided the highest association between B-patterns and CT. The B-line count score had a very poor association with focal lung aeration measured by chest CT ( $\beta = 0.07$  per 100 HU [95% CI:  $-0.06$  to  $0.19$ ],  $p = 0.305$ ). The B-line percentage score was significantly associated with focal lung aeration measured by chest CT scan ( $\beta = 0.46$  per 100 HU [95% CI:  $0.18$ – $0.73$ ],  $p = 0.001$ ). The ICC for inter-observer agreement for the B-line count score was 0.75 (95% CI:  $0.53$ – $0.88$ ) while the ICC for the B-line percentage score was 0.91 (95% CI:  $0.81$ – $0.96$ ).

## DISCUSSION

The findings of this study, comparing the LUS aeration score and B-line scores with focal lung aeration in corresponding chest CT scan regions at different subpleural depths, can be summarized as follows: (i) Subpleural ultrasound penetration depth increases with loss of aeration. (ii) The LUS aeration score adequately estimates focal lung aeration measured by CT, especially when accounting for penetration depth. (iii) The B-line

Table 1. Patient characteristics

Patient characteristic	n = 35*
Age, median (IQR), y	58 (48–69)
Female, No. (%)	11 (31%)
Body mass index, median (IQR)	25.1 (22.4–32.5)
APACHE II, median (IQR)	19 (15–24)
Reason for ICU admission, No. (%)	
Surgical	8 (23%)
Medical	27 (77%)
Reason for invasive ventilation, No. (%)	
Pneumonia	18 (51%)
Depressed level of consciousness	4 (11%)
Sepsis	7 (20%)
Post-operative	4 (11%)
Other	2 (6%)
Acute respiratory distress syndrome	26 (74%)
Duration of invasive ventilation before enrollment, median (IQR), d	4 (1–7) <sup>†</sup>
Respiratory measures, median (IQR)	
PaO <sub>2</sub> /FiO <sub>2</sub> ratio	219 (168–279)
FiO <sub>2</sub> , %	50 (40–60)
Tidal volume, mL	451 (389–552)
Peak airway pressure, cm H <sub>2</sub> O	20 (15–26)
Positive end-expiratory pressure, cm H <sub>2</sub> O	8 (5–10)
Respiratory rate, breaths/min	24 (18–32)

IQR = inter-quartile range; APACHE = acute physiology and chronic health evaluation, ICU = intensive care unit, PaO<sub>2</sub> = Partial pressure of oxygen, FiO<sub>2</sub> = Fraction of inspired oxygen.

\* Of 37 analyzed patients, two patients were excluded from this table because of two enrollments in one patient

<sup>†</sup> Data available for 32 patients.

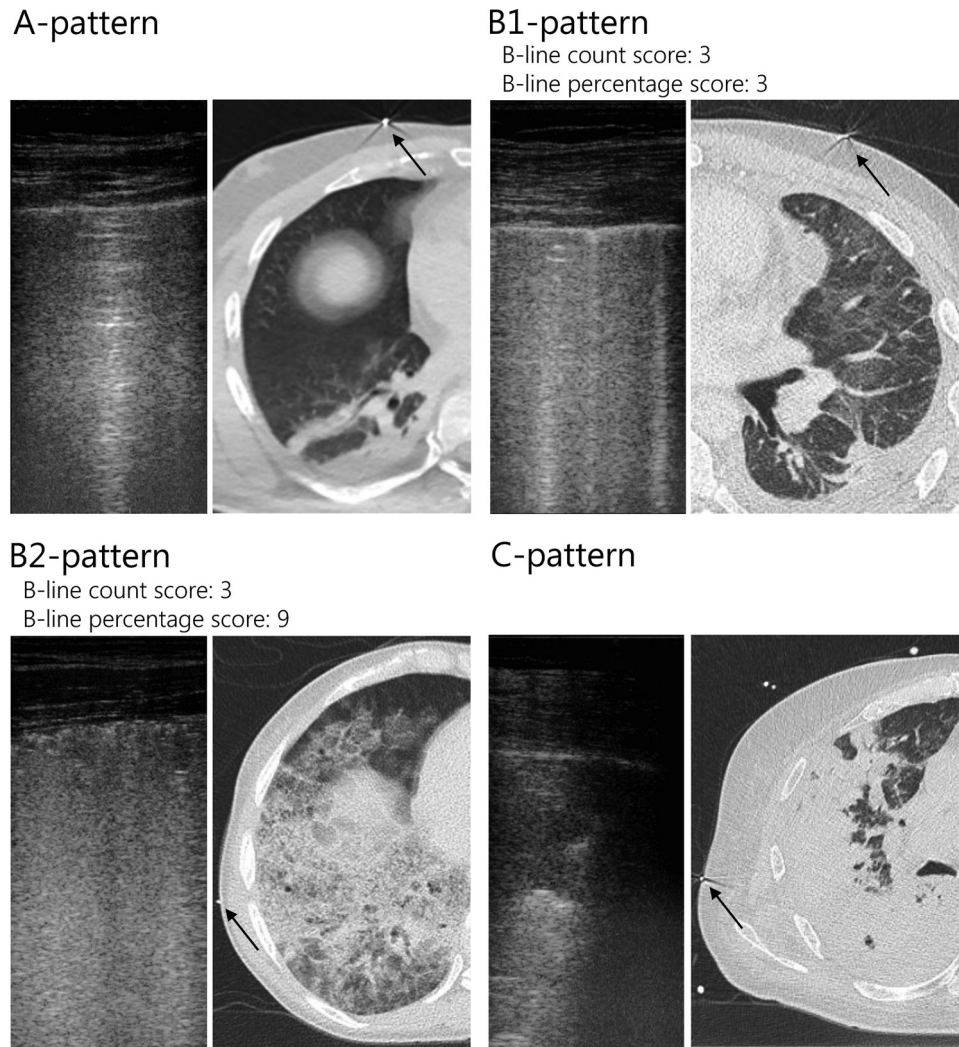


Fig. 3. Examples of LUS images with A-, B1-, B2- and C-patterns and the corresponding CT scans. The *black arrows* in the CT scans indicate the radiopaque skin markers that were placed at the location where the LUS image was obtained. For the images with a B-pattern, the B-line count and B-line percentage score are provided. For the B-line count score, separated B-lines were counted. For the B-line percentage score, B-lines were counted when separated, but in the case of a confluent B-line pattern, the percentage of the screen covered by B-lines was estimated and divided by 10. CT = computed tomography; LUS = lung ultrasound.

percentage score outperforms the B-line count score with respect to focal lung aeration measured by CT.

The subpleural depth for which the association between lung aeration measured with LUS and that measured with CT was the highest was different for each subgroup of LUS patterns. LUS patterns with normal or mild loss of aeration had the highest association with CT at the lowest subpleural depth of 1 cm. This conforms to the physics-derived hypothesis that the penetration depth of LUS in the aerated lung is very limited because of the high reflection and dissipation of ultrasound beams by air (Volpicelli et al. 2012). When evaluating B-patterns only, the highest association between aeration measured with LUS and CT was found at a depth of 6 cm. This

suggests that poorly aerated lung does facilitate ultrasound beams deeper into the lung than previously assumed (Baldi et al. 2013). Thus, in the presence of interstitial syndrome the ultrasound coverage seems to go beyond the superficial subpleural layer. Our findings help to quantify this penetration process *in vivo* in ventilated patients, adding to bench study data that proposed several mechanisms for the increased permeability of the pathological lung (Soldati et al. 2009, 2014). The finding that the subpleural penetration depth was higher in B1- and B2- patterns combined than in B2- and C-patterns combined was unexpected as we know that ultrasound beams can freely travel through consolidated lung tissue (Volpicelli et al. 2012). A possible explanation for this

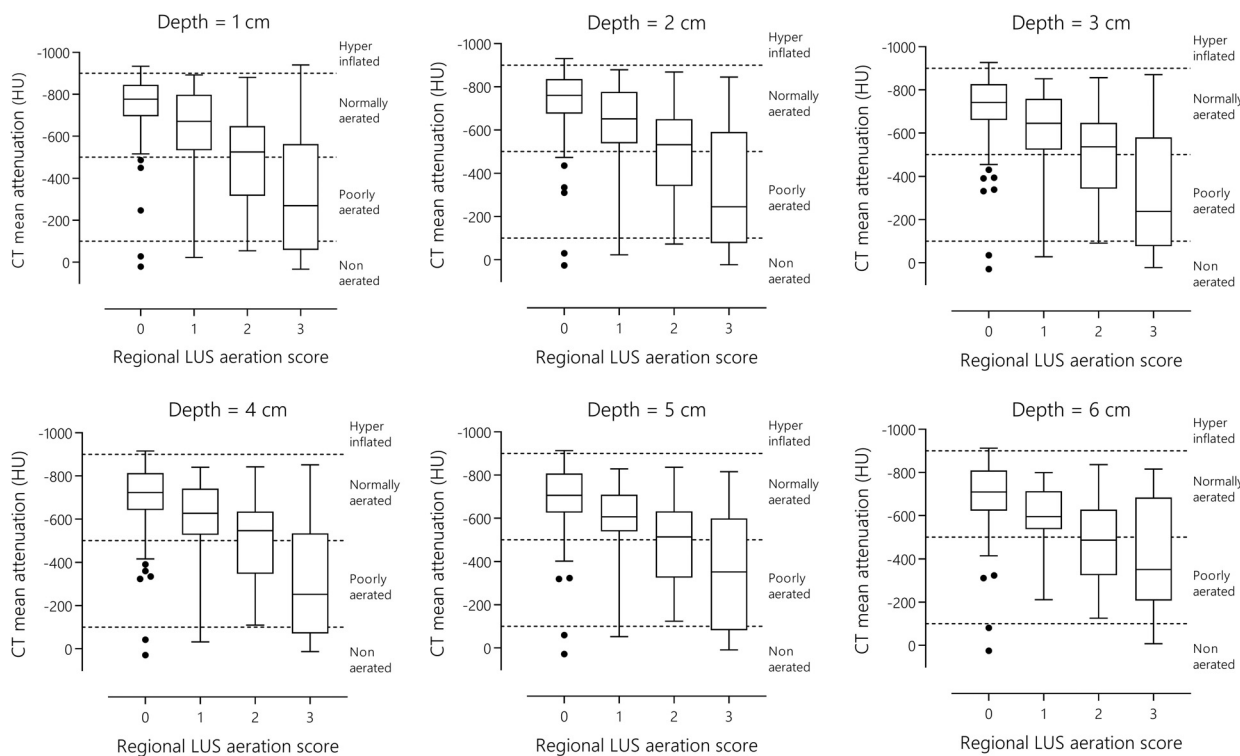


Fig. 4. Lung ultrasound (LUS) aeration score compared with computed tomography (CT) mean attenuation measured at subpleural depths between 1 and 6 cm. The original probe footprint was used (100%).

finding might be the large variation in consolidation size, as smaller consolidations could be surrounded by normally aerated lung tissue and thus exhibit better lung aeration on CT at larger subpleural depths.

Our results comparing the LUS aeration score with chest CT are in line with a previously published study that reported a good correlation between the two techniques in

20 patients with acute respiratory distress syndrome (Chiumello *et al.* 2018). Moreover, our study included every ventilated patient with an indication for chest CT, which proves validity of LUS aeration scores beyond acute respiratory distress syndrome. The previous study compared lung aeration between LUS and CT at the level of an entire lung region. Our study adds to these data by

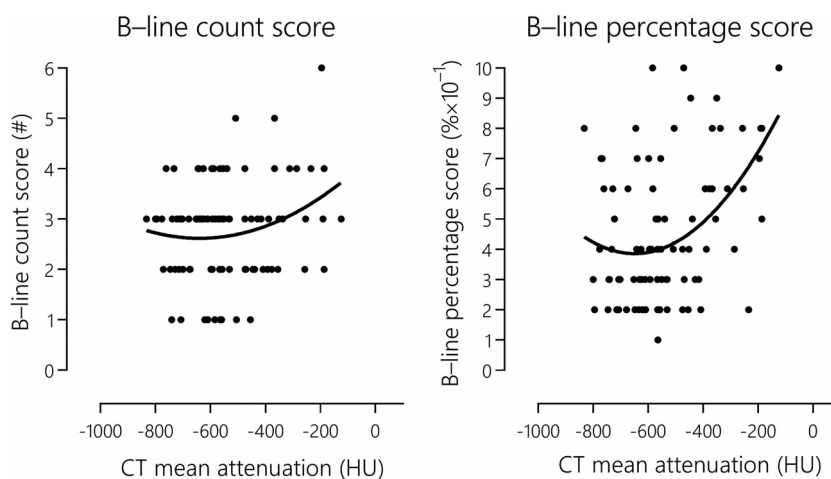


Fig. 5. Comparison between the number of separately spaced B-lines (B-line count score) and the percentage of the screen covered by B-lines divided by 10 (B-line percentage score) and CT mean attenuation. CT mean attenuation was chosen at a subpleural depth of 6 cm and a probe footprint of 120%, yielding the highest association for B-patterns. CT = computed tomography; HU = Hounsfield units; LUS = lung ultrasound.

comparing lung aeration at a focal level and thus, combined with the radiopaque skin marker, provides a more precise comparison between LUS and CT. In the past, several clinical studies reported the potential for LUS scores to guide mechanical ventilation and fluid management (Bouhemad et al. 2011; Caltabeloti et al. 2014; Wang et al. 2016). The present study strengthens the clinical applicability of these studies by adding insight into the capacities and limitations of LUS with respect to penetration depth. Integration of subpleural penetration depths in LUS methods might improve their performance and should be addressed in future studies.

No association was found between the B-line count score and focal lung aeration measured by CT. Previously, the B-line count score was significantly correlated with extravascular lung water measured by chest radiography scores,  $P/F$  ratio and thermodilution (Jambrik et al. 2004; Agricola et al. 2005; Theerawit et al. 2014; Bataille et al. 2015). In the current study, lung aeration was assessed on a focal level instead of a global level, which might explain the contrasting results. The B-line count of all lung regions combined may correlate well with a global measure of extravascular lung water, while this signal is lost when comparing on a focal level. The B-line percentage score exhibited a significant association with CT when assessed on a focal level, which is in line with a previous study comparing the percentage score on a global level with CT (Baldi et al. 2013). The results of our study imply that accounting for confluent B-lines, as done in the B-line percentage score, outperforms counting of single B-lines in estimation of focal lung aeration (Mongodi et al. 2017).

This is the first study that empirically estimates ultrasound penetration depth in the lung in comparison to the gold standard for quantification of lung aeration, namely, quantitative CT analysis. Important strengths of this study were the use of radiopaque skin markers to pinpoint the pulmonary regions of interest at the chest CT scan, the closeness in time of the LUS exam to the chest CT scan and the use of identical ventilator settings during LUS and CT. Also, patients were not disconnected from the ventilator between the two imaging procedures, and the patients' arm positioning was identical during both exams. Hence this study allows for a direct comparison of aeration assessment between LUS and chest CT in the exact same lung region. Of note, we did include all invasively ventilated patients regardless of the reason for invasive ventilation, increasing the generalizability of the findings.

The present study has several limitations. LUS was performed before the patients' transfer to the CT table, in some cases resulting in a change from a semirecumbent to a supine position. The respiratory cycle and transfer of the

patient from the bed to the CT table could have influenced the preciseness of the radiopaque skin markers that were placed during the LUS exam. However, enlarging the "probe footprint" of the ROI that was analyzed in CT had negligible effect on the association between focal lung aeration measured with LUS and CT. Finally, the sample size of this study was low and no formal sample size calculation was performed, but this study is still larger than other ICU studies comparing LUS and CT (Baldi et al. 2013; Chiumello et al. 2018, 2019).

## CONCLUSIONS

In invasively ventilated ICU patients, the level of lung aeration affects the subpleural penetration depth of ultrasound. When this effect was accounted for, a strong association was found between the LUS aeration score and focal lung aeration measured by CT. The B-line percentage score exhibited a strong positive association with lung aeration, while the B-line count score did not. The LUS aeration score and the B-line percentage score accurately reflect lung aeration in ICU patients, but LUS scores should be interpreted while accounting for the subpleural penetration depth of ultrasound.

*Acknowledgments*—No funding was received for this study.

*Conflict of interest disclosure*—The authors declare no conflicts of interest.

## SUPPLEMENTARY MATERIALS

Supplementary material associated with this article can be found in the online version at [doi:10.1016/j.ultrasmedbio.2021.05.019](https://doi.org/10.1016/j.ultrasmedbio.2021.05.019).

## REFERENCES

- Agricola E, Bove T, Oppizzi M, Marino G, Zangrillo A, Margonato A, Picano E. Ultrasound comet-tail images: A marker of pulmonary edema. *Chest* 2005;127:1690–1695.
- Baldi G, Gargani L, Abramo A, D'Errico L, Caramella D, Picano E, Giunta F, Forfori F. Lung water assessment by lung ultrasonography in intensive care: A pilot study. *Intensive Care Med* 2013;39:74–84.
- Bataille B, Rao G, Cocquet P, Mora M, Masson B, Ginot J, Silva S, Moussot PE. Accuracy of ultrasound B-lines score and  $E/E_a$  ratio to estimate extravascular lung water and its variations in patients with acute respiratory distress syndrome. *J Clin Monit Comput* 2015;29:169–176.
- Bilotta F, Giudici LD, Zeppa IO, Guerra C, Stazi E, Rosa G. Ultrasound imaging and use of B-lines for functional lung evaluation in neurocritical care. *Eur J Anaesthesiol* 2013;30:464–468.
- Bouhemad B, Zhang M, Lu Q, Rouby JJ. Clinical review: Bedside lung ultrasound in critical care practice. *Crit Care* 2007;11:205.
- Bouhemad B, Liu ZH, Arbelot C, Zhang M, Ferarri F, Le-Guen M, Girard M, Lu Q, Rouby JJ. Ultrasound assessment of antibiotic-induced pulmonary reaeration in ventilator-associated pneumonia. *Crit Care Med* 2010;38:84–92.
- Bouhemad B, Brisson H, Le-Guen M, Arbelot C, Lu Q, Rouby JJ. Bedside ultrasound assessment of positive end-expiratory pressure-induced lung recruitment. *Am J Respir Crit Care Med* 2011;183:341–347.

- Caltabeloti FP, Monsel A, Arbelot C, Brisson H, Lu Q, Gu WJ, Zhou GJ, C Auler JO, Rouby JJ. Early fluid loading in acute respiratory distress syndrome with septic shock deteriorates lung aeration without impairing arterial oxygenation: A lung ultrasound observational study. *Crit Care* 2014;18:R91.
- Chiumello D, Mongodi S, Algieri I, Vergani GL, Orlando A, Via G, Crimella F, Cressoni M, Mojoli F. Assessment of lung aeration and recruitment by CT scan and ultrasound in Acute Respiratory Distress Syndrome Patients. *Crit Care Med* 2018;46:1761–1768.
- Chiumello D, Umbrello M, Sferazza Papa GF, Angileri A, Gurgitano M, Formenti P, Coppola S, Froio S, Cammaroto A, Carrafiello G. Global and regional diagnostic accuracy of lung ultrasound compared to CT in patients with acute respiratory distress syndrome. *Crit Care Med* 2019;47:1599–1606.
- Corradi F, Brusasco C, Vezzani A, Santori G, Manca T, Ball L, Nicolini F, Gherli T, Brusasco V. Computer-aided quantitative ultrasonography for detection of pulmonary edema in mechanically ventilated cardiac surgery patients. *Chest* 2016;150:640–651.
- Davids JG, Turton EW, Raubenheimer JE. Comparison of lung ultrasound with transpulmonary thermodilution in assessing extra-vascular lung water. *South Afr J Anaesth Analg* 2016;22:170–174.
- Gattinoni L, Caironi P, Pelosi P, Goodman LR. What has computed tomography taught us about the acute respiratory distress syndrome?. *Am J Respir Crit Care Med* 2001;164:1701–1711.
- Gattinoni L, Caironi P, Cressoni M, Chiumello D, Ranieri VM, Quintel M, Russo S, Patroniti N, Cornejo R, Bugeo G. Lung recruitment in patients with the acute respiratory distress syndrome. *N Engl J Med* 2006;354:1775–1786.
- Goffi A, Krusselbrink R, Volpicelli G. The sound of air: point-of-care lung ultrasound in perioperative medicine. *Can J Anesth* 2018;65:399–416.
- Jambrik Z, Monti S, Coppola V, Agricola E, Mottola G, Miniati M, Picano E. Usefulness of ultrasound lung comets as a nonradiologic sign of extravascular lung water. *Am J Cardiol* 2004;93:1265–1270.
- Krusselbrink R, Chan V, Cibinel GA, Abrahamson S, Goffi A. I-AIM (indication, acquisition, interpretation, medical decision-making) framework for point of care lung ultrasound. *Anesthesiology* 2017;127:568–582.
- Lichtenstein DA, Mezière GA. Relevance of lung ultrasound in the diagnosis of acute respiratory failure: The BLUE protocol. *Chest* 2008;134:117–125.
- Mongodi S, Via G, Girard M, Rouquette I, Missot B, Braschi A, Mojoli F, Bouhemad B. Lung Ultrasound for early diagnosis of ventilator-associated pneumonia. *Chest* 2016;149:969–980.
- Mongodi S, Bouhemad B, Orlando A, Stella A, Tavazzi G, Via G, Iotti GA, Braschi A, Mojoli F. Modified lung ultrasound score for assessing and monitoring pulmonary aeration. *Ultraschall Med* 2017;38:530–537.
- Mozzini C, Di Dio Perna M, Pesce G, Garbin U, Fratta Pasini AM, Ticinesi A, Nouvenne A, Meschi T, Casadei A, Soresi M, Cominacini L. Lung ultrasound in internal medicine efficiently drives the management of patients with heart failure and speeds up the discharge time. *Intern Emerg Med* 2018;13:27–33.
- Park EJ, Yoon YT, Hong CK, Ha YR, Ahn JH. Randomized, noninferiority study between video versus hand ultrasound with wet foam dressing materials to simulate B-lines in lung ultrasound. *Medicine (Baltimore)* 2017;96:e7642.
- Shyamsundar M, Attwood B, Keating L, Walden AP. Clinical review: The role of ultrasound in estimating extra-vascular lung water. *Crit Care* 2013;17:237.
- Soldati G, Copetti R, Sher S. Sonographic interstitial syndrome. *J Ultrasound Med* 2009;28:163–174.
- Soldati G, Copetti R, Sher S. Can lung comets be counted as “objects”? *JACC Cardiovasc Imaging* 2011;4:438–439.
- Soldati G, Smargiassi A, Inchingolo R, Sher S, Nenna R, Valente S, Inchingolo CD, Corbo GM. Lung ultrasonography may provide an indirect estimation of lung porosity and airspace geometry. *Respiration* 2014;88:458–468.
- Soummer A, Perbet S, Brisson H, Arbelot C, Constantin JM, Lu Q, Rouby JJ. Ultrasound assessment of lung aeration loss during a successful weaning trial predicts postextubation distress. *Crit Care Med* 2012;40:2064–2072.
- Theerawit P, Touman N, Sutherasan Y, Kiatboonsri S. Transthoracic ultrasound assessment of B-lines for identifying the increment of extravascular lung water in shock patients requiring fluid resuscitation. *Indian J Crit Care Med* 2014;18:195–199.
- Volpicelli G, Elbarbary M, Blaivas M, Lichtenstein DA, Mathis G, Kirkpatrick AW, Melniker L, Gargani L, Noble VE, Via G, Dean A, Tsung JW, Soldati G, Copetti R, Bouhemad B, Reissig A, Agricola E, Rouby J-J, Arbelot C, Liteplo A, Sargsyan A, Silva F, Hoppmann R, Breitkreutz R, Seibel A, Neri L, Storti E, Petrovic T. International evidence-based recommendations for point-of-care lung ultrasound. *Intensive Care Med* 2012;38:577–591.
- Wang X, Ding X, Zhang H, Chen H, Su L, Liu D. Lung ultrasound can be used to predict the potential of prone positioning and assess prognosis in patients with acute respiratory distress syndrome. *Crit Care* 2016;20:385.
- Xirouchaki N, Kondili E, Prinianakis G, Malliotakis P, Georgopoulos D. Impact of lung ultrasound on clinical decision making in critically ill patients. *Intensive Care Med* 2014;40:57–65.
- Zanforlin A, Smargiassi A, Inchingolo R, Sher S, Ramazzina E, Corbo GM, Soldati G. B-Lines: To count or not to count?. *JACC Cardiovasc Imaging* 2014;7:635–636.