

This is the peer reviewed version of the following article:

Identification of cardiac organ damage in arterial hypertension: Insights by echocardiography for a comprehensive assessment / Cameli, M.; Lembo, M.; Sciaccaluga, C.; Bandera, F.; Ciccone, M. M.; D Andrea, A.; D Ascenzi, F.; Esposito, R.; Evola, V.; Liga, R.; Mandoli, G. E.; Palmiero, P.; Santoro, C.; Scicchitano, P.; Sorrentino, R.; Zito, A.; Pedrinelli, R.; Mondillo, S.; Mattioli, A. V.; Galderisi, M.. - In: JOURNAL OF HYPERTENSION. - ISSN 0263-6352. - 38:4(2020), pp. 588-598. [10.1097/HJH.0000000000002323]

Terms of use:

The terms and conditions for the reuse of this version of the manuscript are specified in the publishing policy. For all terms of use and more information see the publisher's website.

17/12/2024 12:50

(Article begins on next page)

Journal of Hypertension

Identification of cardiac organ damage in arterial hypertension: insights by echocardiography for a comprehensive assessment

--Manuscript Draft--

Manuscript Number:	JH-D-19-00840R1
Full Title:	Identification of cardiac organ damage in arterial hypertension: insights by echocardiography for a comprehensive assessment
Short Title:	Echocardiography and Heart in Hypertension
Article Type:	Original Manuscript
Keywords:	Arterial hypertension, Echocardiography, Cardiac organ damage, Left ventricular hypertrophy, Diastolic dysfunction
Corresponding Author:	Maurizio Galderisi, MD naples, ITALY
Corresponding Author's Institution:	
First Author:	Matteo Cameli, MD
Order of Authors:	Matteo Cameli, MD Maria Lembo, MD Carlotta Sciaccaluga, MD Francesco Bandera, MD Marco Matteo Ciccone, MD Antonello D'Andrea, MD Flavio D'Ascenzi, MD Roberta Esposito, MD Vincenzo Evola, MD Riccardo Liga, MD Giulia Elena Mandoli, MD Pasquale Palmiero, MD Ciro Santoro, MD Pietro Scicchitano, MD Regina Sorrentino, MD Annapaola Zito, MD Roberto Pedrinelli, MD Sergio Mondillo, MD Anna Vittoria Mattioli, MD Maurizio Galderisi, MD
Abstract:	Arterial hypertension (AH), a widespread disease, whose prevalence increases with age, represents a major risk factor for cardiovascular events, causing damage in several organs, including the heart. In this context, echocardiography has a clear and pivotal role, being able to assess cardiac morphology and detect hemodynamic changes induced by this disease. 2018 ESC/ESH guidelines on arterial hypertension identified main echo parameters such as left ventricular mass, relative wall thickness and left atrial volume, for detecting cardiac organ damage. The present review highlights the advantage of additional echocardiographic parameters such as diastolic

measurement and both thoracic and abdominal aortic dimensions. An overlook on aortic valve should also be suggested in order to detect aortic regurgitation and stenosis, both frequent complications in hypertensive patients. In this kind of comprehensive assessment, the combination of standard and advanced echocardiography (speckle tracking echocardiography and, with a lesser extent, three-dimensional echocardiography) could be considered to improve the diagnostic accuracy, stratify prognosis and address management in AH.



FEDERICO II UNIVERSITY HOSPITAL

School of Medicine

Department of Advanced Biomedical Sciences

Cardiology with CCU and Cardiovascular Emergencies

Director: Prof. Bruno Trimarco

Prof. Maurizio Galderisi

Head, Interdepartmental Laboratory of Cardiac Imaging

Tel 081-7464749, Email: mgalderi@unina.it

Naples, October 16, 2019

Prof. G. Mancia,
Editor-in-Chief, *Journal of Hypertension*

Dear Prof. Mancia,

On behalf of my co-authors and myself, we submit to your kind attention the revised review **“Identification of cardiac organ damage in arterial hypertension: insights by echocardiography for a comprehensive assessment”** for a possible publication on *Journal of Hypertension*.

The manuscript has been revised according to the criticisms and observations risen by the three reviewers.

The aim of the present review is to present a comprehensive echocardiographic assessment for the identification of early cardiac organ damage in patients affected by arterial hypertension. Thus, we tuned down the title, which now states “Identification of cardiac organ damage in arterial hypertension: insights by echocardiography for comprehensive assessment”. Moreover, we highlighted the impact of arterial hypertension on the onset of aortic regurgitation in chapter 6. In addition, even if global longitudinal strain was demonstrated to be able to detect an early systolic left ventricular dysfunction impairment in hypertensive patients, its prognostic impact is controversial in this setting. Accordingly and because of the lack of evidence, we eliminated global longitudinal strain from the list of echo parameters having a prognostic impact on arterial hypertension and also from Table 2.

Enclosed you find the point by point reply to the reviewers.

All authors have read and approved the revised version review and its submission to *Journal of Hypertension*. All authors also affirm that no conflict of interest has to be disclosed.

We hope that our review could be considered suitable now for publication on *Journal of Hypertension*.

Sincerely,

Maurizio Galderisi, MD, FESC

Head, Interdepartmental Laboratory of Cardiac Imaging

Department of Advanced Biomedical Sciences

Federico II University Hospital

Naples, Italy

Reply to Reviewers:

Reviewer #1:

The additional echocardiographic parameters such as left ventricular diastolic measurement and dimensions of both thoracic and abdominal aorta are meaningful for the hypertension, but the low flow low gradient aortic stenosis is not closely related because the high-load hemodynamic state, so the aortic regurgitation is necessary. I think the evaluation of morphological structure of aortic valve is more important for hypertension.

Thank you for your comment. We recognize the important impact of arterial hypertension on aortic valve morphological changes, thus causing both aortic valve regurgitation and stenosis. Aortic valve regurgitation may be due to accelerated AH induced valve deterioration or it could be functional, thus associated to tethering of the leaflets, it depending on the sino-tubular junction/annulus mismatch, because of ascending aorta dilatation. In the new draft of the manuscript we highlighted this concept in chapter 6 (now called: Aortic valve: aortic regurgitation and paradoxical Low flow low gradient aortic stenosis) (see page 15, lines 17-23 and page 16 lines 1-2). We also believe that paradoxical low flow low gradient is a particular type of aortic stenosis, which needs to be carefully searched and detected in the hypertensive setting, because associated with a poor prognosis. Indeed its rate is often underestimated, because its diagnosis is sometimes difficult and characterized by a mismatch between aortic valve area and mean pressure gradient: valve area $<1 \text{ cm}^2$ with a peak velocity $<4 \text{ m/s}$, a mean pressure gradient $<40 \text{ mmHg}$ and stroke volume index $<35 \text{ mL/m}^2$ despite normal LV ejection fraction. LV features of low flow low gradient aortic stenosis include LV concentric geometry and small LV volume, which often represent LV changes induced by AH. These concepts are summarized in the same Chapter 6.

Reviewer #2:

This review describes the potential interest of echocardiography in assessing cardiac damage in hypertension. This review is exhaustive and well written. My main concern is the presentation of this review. "beyond guidelines". Certainly echocardiography allows gathering many information on left ventricular hypertrophy, left ventricular function, atrial volume, aortic size ... But the main reason why guidelines have to be cautious is that there is no demonstration that systematic echocardiography could really improve the prognosis of hypertensive patients. So in my opinion you should tune down your conclusion that "The role of echocardiography in the thorough assessment of the hypertensive patient is essential" and the introduction should as well be modified. Echocardiography is very often performed when a hypertensive patient is referred to a cardiologist. Usually the evaluated parameters are LVH, ejection fraction, left atrium diameter and mitral flow. These results usually do not influence the way the patient is treated and I am quite sure that this attitude is not cost effective. But if echocardiography is done, well-motivated or not, it is certainly important to gather the maximum of relevant information on heart and aorta and the interest of this review is to summarize all these points.

We understand your concern. According to your suggestion, we tuned down the title, which now states "Identification of cardiac organ damage in arterial hypertension: insights byechocardiography for comprehensive assessment". Indeed, we also modified the final part of the introduction (see page 5, lines 17-23) and the conclusions: "The role of echocardiography in the thorough assessment of the hypertensive patient is very useful..." (page 17, lines 19-20).

Actually, the aim of the present review is to present a comprehensive echocardiographic assessment for the identification of early cardiac organ damage in patients affected by arterial hypertension. Moreover, we do believe that the echocardiographic evaluation could influence patients' treatment, for example addressing to surgery patients with aortic valve diseases or aortic dilatation, which are frequent in arterial hypertension and also for establishing correct timing of follow-up. Accordingly, under well defined circumstances, echocardiography could present even a valuable cost/effectiveness ratio in hypertensive patients. We highlight now these concepts in the last part of the conclusions (page 18, lines 10-14).

Minor points:

* In the chapter on LVM measurements you should introduce a word of caution about reproducibility of the results which seriously limits the possibility to follow the evolution of LVM with time and treatment in a single patient.

According to your suggestion, we added a statement about LVM poor reproducibility: "The standard echocardiographic approaches to LVM calculation presume a normal LV shape and have several intrinsic technical limitations including the need of a geometric assumption, frequent difficulties in the assessment due to beam orientation (often inducing off-axis views), and inaccuracy in presence of dilated ventricles or asymmetric hypertrophy. For these reasons, reproducibility of M-mode and 2D derived LVM appears in general to be suboptimal, limiting sometimes the possibility to follow the evolution of LVM over time." (page 7, lines 6-11)

The 3D method for assessing LVM show in our experience important limitations: not possible in many patients, time consuming and poor reproducibility in current practice.

We acknowledge the fact that 3D derived LVM had some limitations: mainly the possible incorrect detection of LV epicardial contours and of LV apex and also the impossibility of obtaining suitable 3D images in patients with inadequate imaging. Thus, the feasibility of 3D assessment is reduced. (page 7, lines 17-21). However, 3D LVM has also several advantages: being validated against cardiac MRI and not needing geometrical assumption. Thus, with technical advancement ("virtual apex", the possibility of obtaining information in a single heart beat) it could represent a good compromise between 2D echo and cardiac MRI. In the hands of trained operators, the technique has a good reproducibility in our experience, but it is also true that further studies are needed to prognostically validate 3D derived LVM in the hypertensive setting.

* Table 1: With the purpose of defining LVH, cut-off would be more adequate than reference range

According to your request, in Table 1 we described the thresholds of normalcy instead of the reference ranges of the parameters used for LV geometrical assessment.

* Table 2. The cut-off defined with the ability to predict cardiovascular events should be presented with sensitivity and specificity. For LVM there are more recent papers than those quoted.

We are unable to present sensitivity and specificity of echo parameter predicting cardiovascular events in arterial hypertension since we should need raw data from the original studies and actually we did not find their report in literature. Accordingly, we reported this limitation in the text (page 17, lines 15-16): "Unfortunately, evidence on sensitivity and specificity of those parameters in predicting CV events is lacking in the hypertensive setting". In Table 2 we added more recent studies by Verdecchia P et al. J Am Heart Assoc. 2017;6. pii: e005948, Armstrong AC et al. JACC Cardiovasc Imaging 2012;5:837-48, Gosse P et al. J Hypertens.

2012;30:2403-2409,demonstrating the prognostic impact of LV mass and LV hypertrophy in the hypertensive setting.

For GLS, the lower the better, and probably using the absolute value is less confusing. I am not sure that 20% can be considered as an adequate cut-off. We lack adequate studies in hypertensive patients. Moreover it depends on the software used for its calculation. Quoting Lee and al for GLS is not adequate: only 95 hypertensive patients followed during an average 7 years, 20 events and GLS was not a significant predictor of events.

We understand your concern. Even if GLS was described to detect an early systolic LV dysfunction in arterial hypertension, its prognostic impact is controversial in this setting. Because of the lack of evidence, we eliminated GLS from the echo parameters having a prognostic impact on arterial hypertension and also from Table 2.

* Page 12, I suggest to omit the following comment: It has been proposed that hypertensive heart disease might be divided into four stages, starting with isolated DD (degree I), further progression with DD associated with concentric LVH (degree II), the establishment of clinical signs and symptoms of heart failure (degree III) and finally the occurrence of dilated cardiomyopathy with reduced LVEF (degree IV). [58-59]. This is a conceptual view. There are no strong evidences supporting this progressive evolution and It is probably out of the scope of this review. We eliminated the sentence at issue.

* Fig 3 I suggest to emphasize (for instance with Bold letters) the parameters that must absolutely be present in all echo reports from less important parameters.

According to your suggestion, we highlighted in bold letters the parameters that should be always evaluated in hypertensive patients (Figure 3).

Reviewer #3:

This is an interesting review article that sought to identify target organ damage by echocardiography. However, there are some minor issues to be clarified:

1. For precision, please acknowledge other pioneering randomized studies that have identified changes in diastolic function with anti-hypertensive treatment from Wachtell K et al and Solomon SD et al to name a few. Thank you for your suggestion. The studies by Wachtell K et al and Solomon SD et al are now cited in the references of the new draft of the manuscript.

2. There is limited data that show the incremental prognostic significance of strain imaging. A recent population study by Modin D et al. showed that only left ventricular hypertrophy had incremental prognostic value over clinical risk factors and ECG in hypertensive patients while global longitudinal strain had incremental prognostic value in nonhypertensive patients. This needs to be clarified. As previously described, even if GLS was demonstrated to be able to detect an early systolic LV impairment in hypertensive patients, its prognostic impact is controversial in this setting. Because of the lack of evidence, we eliminated GLS from the list of echo parameters having a prognostic impact on arterial hypertension and also from Table 2.

Abbreviations:

AAA = Abdominal aorta aneurysm

AH = Arterial hypertension

AF= Atrial fibrillation

BSA = Body surface area

CMR = Cardiac magnetic resonance

CV = Cardiovascular

DD = Diastolic dysfunction

EDV = End-diastolic volume

GLS = Global longitudinal strain

HFpEF = Heart failure with preserved ejection fraction

LA = Left atrium

LV = Left ventricular

LVEF = Left ventricular ejection fraction

LVH = Left ventricular hypertrophy

LVM = Left ventricular mass

PWV = Pulse wave velocity

RWT = Relative wall thickness

STE = Speckle tracking echocardiography

TDI = Tissue Doppler imaging

Condensed Abstract

2018 ESC/ESH guidelines on arterial hypertension identified several echocardiographic parameters, like left ventricular mass, relative wall thickness and left atrial volume, for identification of organ damage. The present review highlights the advantage of additional echocardiographic parameters for detecting subclinical organ damage and selecting patients that could be more prone of overt heart failure development. Left ventricular diastolic measurement, both thoracic and abdominal aortic dimensions, and aortic valve diseases measurements could provide an exhaustive view of cardiovascular involvement in arterial hypertension. The combination of standard and advanced echocardiography should be contemplated to address management and stratify prognosis in hypertensive patients.

1 Identification of cardiac organ damage in arterial hypertension: 2 insights by echocardiography for a comprehensive assessment

3
4 Matteo Cameli^{1*}, Maria Lembo^{2*}, Carlotta Sciacaluga¹, Francesco Bandera³,
5 Marco Matteo Ciccone⁴, Antonello D'Andrea⁵, Flavio D'Ascenzi¹, Roberta Esposito²,
6 Vincenzo Evola⁶, Riccardo Liga⁷, Giulia Elena Mandoli¹, Pasquale Palmiero⁸, Ciro Santoro², Pietro
7 Scicchitano⁴, Regina Sorrentino², Annapaola Zito⁴, Roberto Pedrinelli⁷, Sergio Mondillo¹,
8 Anna Vittoria Mattioli⁹, and Maurizio Galderisi²

9 On behalf of Working Groups of Echocardiography and Arterial Hypertension of Italian Society of
10 Cardiology (SIC)

11 * Matteo Cameli and Maria Lembo equally contributed

12 ¹Department of Cardiovascular disease, University of Siena, Siena, Italy

13 ² Department of Advanced Biomedical Sciences, Federico II University Hospital, Via S. Pansini 5, Naples, Italy

14 ³ University of Milan, Cardiology University Department, Heart Failure Unit, IRCCS Policlinico San Donato, San Donato
15 Milanese, Milan, Italy

16 ⁴ Cardiovascular Diseases Section, Department of Emergency and Organ Transplantation (DETO), University of Bari,
17 Bari, Italy

18 ⁵ U.O.D. Diagnostica Cardiologica Integrata, Seconda Università degli Studi, AORN dei Colli-Monaldi, Napoli, Italy

19 ⁶ Department of Clinical and Experimental Medicine, University of Palermo, Palermo, Italy

20 ⁷ Department of Surgical, Medical, Molecular Pathology and Critical Area, University of Pisa, Pisa, Italy

21 ⁸ ASL Brindisi, Cardiology Equipe, District of Brindisi, Via Francia 47, 72100 Brindisi, Italy

22 ⁹ Department of Surgical, Medical and Dental Morphological Sciences related to Transplant, Oncology and
23 Regenerative Medicine, University of Modena and Reggio Emilia, Italy

24
25 Short title: Echocardiography and Heart in Hypertension

26 No conflict of interest to declare

27 2 Tables

28 4 Figures

29 Word count: 8579

30
31
32
33
34 Correspondence to

35 Maurizio Galderisi, MD, FESC

36 Interdepartmental Laboratory of Cardiac Imaging

37 Federico II University Hospital

38 Via Pansini 5, 80131 Naples, Italy.

39 Phone: +39-081-7464749

40 e-mail: mgalderi@unina.it

1 **Abstract**

2 Arterial hypertension (AH), a widespread disease, whose prevalence increases with age,
3 represents a major risk factor for cardiovascular events, causing damage in several organs,
4 including the heart. In this context, echocardiography has a clear and pivotal role, being able to
5 assess cardiac morphology and detect hemodynamic changes induced by this disease. 2018
6 ESC/ESH guidelines on arterial hypertension identified main echo parameters such as left
7 ventricular mass, relative wall thickness and left atrial volume, for detecting cardiac organ
8 damage. The present review highlights the advantage of additional echocardiographic parameters
9 such as diastolic measurement and both thoracic and abdominal aortic dimensions. An overlook
10 on aortic valve should also be suggested in order to detect aortic regurgitation and stenosis, both
11 frequent complications in hypertensive patients. In this kind of comprehensive assessment, the
12 combination of standard and advanced echocardiography (speckle tracking echocardiography and,
13 with a lesser extent, three-dimensional echocardiography) could be considered to improve the
14 diagnostic accuracy, stratify prognosis and address management in AH.

15

16

17 **Key words:** Arterial hypertension, Echocardiography, Cardiac organ damage, Left ventricular
18 hypertrophy, Diastolic dysfunction

19

20

21

22

23

1 **Condensed Abstract**

2

3 2018 ESC/ESH guidelines on arterial hypertension identified several echocardiographic
4 parameters, like left ventricular mass, relative wall thickness and left atrial volume, for
5 identification of organ damage. The present review highlights the advantage of additional
6 parameters for detecting subclinical organ damage and selecting patients that could be more
7 prone of overt heart failure development. Thus, diastolic measurement, both thoracic and
8 abdominal aortic dimensions, and aortic valve diseases should be considered for providing an
9 exhaustive view of cardiovascular involvement in arterial hypertension. The combination of
10 standard and advanced echocardiography should be contemplated to address management and
11 stratify prognosis in hypertensive patients.

12

13

14

15

16

17

18

19

20

21

22

23

24

25

26

27

28

29

30

31

32

33

34

1 **Abbreviations:**

2 AAA = Abdominal aorta aneurysm

3 AH = Arterial hypertension

4 AF= Atrial fibrillation

5 BSA = Body surface area

6 CMR = Cardiac magnetic resonance

7 CV = Cardiovascular

8 DD = Diastolic dysfunction

9 EDV = End-diastolic volume

10 GLS = Global longitudinal strain

11 HFpEF = Heart failure with preserved ejection fraction

12 LA = Left atrium

13 LV = Left ventricular

14 LVEF = Left ventricular ejection fraction

15 LVH = Left ventricular hypertrophy

16 LVM = Left ventricular mass

17 PWV = Pulse wave velocity

18 RWT = Relative wall thickness

19 STE = Speckle tracking echocardiography

20 TDI = Tissue Doppler imaging

21

22

23

24

25

26

27

28

29

1. Introduction

Arterial hypertension (AH) is one of the major contributors to the global burden of disease, showing a high prevalence which progressively increases as the age advances, reaching a value >60% in the population aged 60 years or over. [1] It is an important cardiovascular (CV) risk factor since it is independently associated with the occurrence of major CV events, including myocardial infarction, heart failure, peripheral artery disease, ischaemic and haemorrhagic stroke [2,3] and atrial fibrillation (AF) as well. [4] Subclinical target organ damage involves heart, brain, kidney, eyes, and is considered a marker of pre-clinical CV disease. [5] In order to avoid irreversible organ damage, it is important to promptly diagnose cardiac organ damage and to initiate an early and effective treatment to reduce the progression towards overt involvement. In this view, echocardiography plays a central role in detecting subclinical cardiac remodelling, which develops as a result of pressure overload. These changes include left ventricular (LV) concentric remodelling and hypertrophy (LVH), diastolic dysfunction (DD) and left atrial (LA) enlargement, all factors predisposing to heart failure. The detrimental effect of AH on aorta and its elastic properties induces a progressive wall stretching and increased arterial stiffness, which is a predictor of both aortic valve and aortic vessel disease.

The latest ESC/ESH guidelines [6] on AH recommend the use of echocardiography in presence of electrocardiographic abnormalities, suggesting the assessment of standard echo parameters such as LV mass (LVM), relative wall thickness (RWT) and LA volume, for the definition of organ damage. The present review aims to underline the possible advantage of using additional parameters, including aortic dimension and cardiac function, obtainable from standard and advanced echocardiography that could provide a wider view of CV involvement and identify subclinical organ damage in patients affected by AH.

1 **2. Left ventricle**

2 Left ventricle is directly affected by systemic AH. Elevated blood pressure is responsible for
3 increased LV afterload, which implies that the left ventricle must develop a higher pressure in
4 order to guarantee adequate cardiac output and peripheral organ perfusion. In response to AH, LV
5 wall stress increases, LV walls become thicker and LVM greater, due to interposition of interstitial
6 fibrosis among cardiomyocytes. The echocardiographic assessment is a cornerstone in this kind of
7 evaluation, it corresponding to the detection of LV geometric patterns and diagnosis of LVH.

8 *2.1 Left ventricular hypertrophy*

9 Echocardiographic derived LVH has proven to be a strong predictor of mortality in both the
10 general population and in patients affected by AH. [7] Furthermore, the regression of LVH during
11 anti-hypertensive treatment is a good predictor of improved prognosis. [8-10] Accordingly, an
12 exhaustive quantification of LVM in hypertensive patients is of paramount importance. As
13 reported in the ASE/EACVI Chamber Quantification recommendations [8,11], LVM can be
14 determined by linear measurements of septal and posterior wall thickness, and of LV internal
15 cavity dimension, all at end-diastole, by using 2D guided M-mode echocardiography or directly by
16 2D echocardiography [8]. These approaches imply the assumption of a geometric model and the
17 use of the following formula:

18
$$\text{LVM} = 0.8 \times 1.04 \times [(\text{IVST} + \text{LVID} + \text{PWT})^3 - \text{LVID}^3] + 0.6 \text{ g}$$

19 where IVS is the interventricular septal thickness, LVID is LV internal diameter and PWT is the
20 infero-lateral wall thickness. LVM determined by this formula has been successfully validated
21 against heart cardiac autopsy [12]. LVM can be calculated also by 2D echocardiography by using
22 area-length formula and the truncated ellipsoid formula. [13] The indexation of LVM is mandatory,

1 because it allows comparisons among subjects with different body sizes. In the hypertensive
2 setting, LV mass is usually indexed for body surface area (BSA) or for height raised to allometric
3 powers such as 2.7 [14] or 1.7 [15]. As reported in the ESC/ESH guidelines [6,11], the indexation
4 for height has advantages over indexing to BSA, in order to avoid the underestimation of the rate
5 of LVH in overweight/obese subjects. [16]

6 The standard echocardiographic approaches to LVM calculation presume a normal LV
7 shape and have several intrinsic technical limitations including the need of a geometric
8 assumption, frequent difficulties in the assessment due to beam orientation (often inducing off-
9 axis views), and inaccuracy in presence of dilated ventricles or asymmetric hypertrophy. For these
10 reasons, reproducibility of M-mode and 2D derived LVM appears in general to be suboptimal,
11 limiting sometimes the possibility to follow the evolution of LVM over time [17-18]. Conversely,
12 the novel 3D reconstruction of LVM potentially represents a more reliable method for the
13 assessment of LVM since does not need a geometric assumption and allows to obtain its direct
14 calculation, even in patients with abnormal LV shape [19]. 3D echo derived LVM has been
15 validated against cardiac magnetic resonance (CMR), i.e. the gold standard imaging technique for
16 the evaluation of this parameter [20-22] but is less expensive and more widely applicable in the
17 clinical practice than CMR. Some limitations of 3D LVM computation shall be acknowledged:
18 mainly the possible incorrect detection of LV epicardial contours and of LV apex and also the
19 impossibility of obtaining suitable 3D images in patients with basically 2D inadequate imaging.
20 Thus, at the present time, both the feasibility and reproducibility of 3D LVM determination are still
21 suboptimal. Nevertheless, technical advancement in temporal and spatial resolution allows to
22 acquire suitable 3D echo images, with the possibility of amplifying LV apex region (“virtual apex”),
23 which is the most critical part of the assessment. [23]

1 **Table 1** summarizes the cut-off values of abnormalcy of LVM with the different techniques.
2 The knowledge of the cut-off points by using the different imaging techniques should be carefully
3 considered. Notably, the cut-off points of LVM derived from standard echocardiography are
4 prognostically validated, whereas those obtainable by 3D echo is not. CMR derived LVM and LVH
5 were demonstrated to be prognosticators in AH [24].

6 The evaluation of differential diagnosis for LVH is important in order to exclude other
7 possible causes of increased LV parietal walls, such as hypertrophic cardiomyopathy. Regional
8 strain could be helpful in this context. Patients with hypertrophic cardiomyopathy present a more
9 impaired regional longitudinal strain, particularly in apical segments, compared to hypertensive-
10 LVH. [23, 25] The assessment of regional strain is also useful for differentiating myocardial effects
11 of AH from infiltrative diseases, as cardiac amyloidosis, being characterized by a regional
12 impairment of longitudinal function which spares the apical segments ("apical sparing") [26], and
13 storage cardiomyopathy, such as Anderson Fabry disease. [27]

14 *2.2 Left ventricular geometry*

15 In the early stages of AH, LV geometry remains generally normal, but as consequence of
16 increased afterload, the shape of the left ventricle is prone to morphological changes [28]. The
17 standard echocardiographic definition of LV geometry presumes the use of LVM and RWT; the
18 latter is commonly determined as the ratio between twice the posterior wall thickness and LV
19 diastolic diameter at end-diastole [29]. Adopting these two parameters, four geometrical patterns
20 are described: normal geometry, concentric remodelling, concentric LVH - which consists in
21 uniformly increased LV wall thickness, an increased LVM with normal cavity size [8, 30] - and
22 eccentric LVH, characterized by increased LV cavity size and LVM with normal LV wall thickness
23 (**Figure 1**). More recently, Khouri et al proposed a new classification of LV geometry patterns,

1 considering also LV dilatation. [30] By using this novel classification, survival was similar between
2 hypertensive patients with eccentric LVH and normal LVM, whereas it was progressively reduced
3 as LV dilatation occurred, achieving the lowest rate in patients with concentric LVH and LV
4 dilatation. [31-33]

5 An accurate evaluation of LV geometry is essential for the patient's risk stratification, to
6 guide anti-hypertensive therapy and to identify a target organ damage [6]. However, due to the
7 above mentioned limitations of 2D assessment, this approach can be even improved by using
8 LVM/end-diastolic volume (EDV) ratio, a novel index which has been firstly introduced by CMR.
9 [34]: higher the ratio greater the thickness to cavity ratio of the left ventricle. This ratio was also
10 found to correlate with myocardial fibrosis and outcome in hypertensive patients [34]. The
11 feasibility of this index has been recently shown by using 3D-echocardiography [34, 35]. 3D echo
12 derived LVM/EDV ratio was also able to detect a higher rate of LV concentric geometry in
13 comparison with 2D assessment; 3D LV mass/EDV ratio identified also patients with low stroke
14 volume in the context of LV remodelling due to AH. [34] This aspect is particularly relevant since it
15 might reveal an early functional impairment beyond the information carried by LV geometry alone
16 Accordingly, the use of 3D echo could be a good compromise between 2D echo and CMR in
17 characterizing subclinical organ damage in AH. **Table 1** shows the main parameters and their cut-
18 off points of abnormalcy used for assessment of LV geometry by echo techniques.

19 *2.3 Left ventricular function*

20 Currently 2D echocardiographic derived LV ejection fraction (LVEF) is the most frequently
21 used parameter for the assessment of LV systolic function. Nevertheless, LVEF suffers the limit of
22 geometric assumption, it has poor reproducibility (day-to day variability of about 10%) [36-37] and
23 therefore it is able to detect LV dysfunction only in clinically overt stages. [38] In addition, LVEF is

1 deeply influenced by load conditions and changes of LV geometry [39, 40], both critical points in
2 hypertensive patients [41]. Accordingly, LVEF is poorly accurate for detecting subclinical LV
3 dysfunction in the clinical setting. In the 1980s this concept was firstly highlighted by the
4 calculation of midwall fractional shortening, an index which, incorporating half part of the
5 myocardial wall, allows to identify early LV systolic dysfunction in presence of LV concentric
6 geometry, when LVEF is still normal [39]. To date, the assessment of myocardial mechanics can be
7 much more easily performed by using pulsed Tissue Doppler imaging (TDI) or, better, speckle
8 tracking echocardiography (STE), depending on the available level of technology [41]. TDI has
9 demonstrated the diagnostic capability of differentiating between physiological and pathological
10 LVH. [42] STE is angle-independent and very reproducible, being also relatively operator
11 independent. It allows quantifying the different directional components of myocardial
12 deformation such as longitudinal, circumferential and radial strain, and LV twisting as well.
13 Although all these strain components well correlate with LVEF, global longitudinal strain (GLS)
14 appears to be superior because of its largely better feasibility and reproducibility (about 6%). [43]
15 Moreover, despite being load dependent similarly to LVEF, GLS can be altered independently on
16 changes of LV geometry. [44] Accordingly, a decline in GLS, has been shown to be evident even in
17 presence of LVEF, being useful to identify preclinical stages of LV involvement in AH [45]. GLS has
18 been found to be also associated with both the degree of LV filling pressures and the extent of
19 myocardial fibrosis in uncomplicated hypertensive patients. [46-50] Preliminary experience
20 showed the potential usefulness of 3D strain rate imaging in AH [51]. However, this technique is
21 not ready yet to be used in the clinical practice, due to its limited availability and feasibility.

22 **3. Diastolic function**

1 In early stages of AH, LV diastolic dysfunction (DD) generally occurs long before LVEF is
2 compromised [52]. Persisting elevated blood pressure levels promotes LV DD through various
3 mechanisms, including increased afterload, myocardial ischemia [53], and myocardial fibrosis,
4 which constitutes the main determinant of diastolic properties' alteration, it being characterized
5 by an altered myocardial relaxation that interferes with normal LV diastolic filling. [54]

6 According to the latest ASE/EACVI recommendations on diastolic function [54], when LVEF
7 is above 50%, and any myocardial disease (e.g., presence of LVH, ischaemic or significant valvular
8 heart disease) is excluded, recommendations suggest the use of four variables to determine the
9 presence of DD (septal $e' < 7$ or lateral $e' < 10$ cm/s, average $E/e' > 14$, tricuspid regurgitation
10 systolic jet velocity > 2.8 m/s, LA maximum volume index > 34 ml/m²) (**Figure 2**) On the contrary, in
11 presence of myocardial disease, even in presence of normal LVEF, recommendations suggest to
12 apply the same algorithm used for patients with reduced LVEF to estimate LV filling pressures
13 degree (**Figure 3**) [54]. Thus, if LVH is present or not, the second or the first algorithm should be
14 used respectively.

15 Interestingly, DD is strongly related with LV longitudinal systolic dysfunction, and it might
16 occur even before the development of LV concentric geometry [55]. This implies that subtle
17 systolic dysfunction might be responsible for an increase in LV filling pressures, which is a strong
18 predictor of both prognosis and clinical functioning [56]. It has to be stressed that AH generally
19 clusters with other CV risk factors [56], and diabetes mellitus, impaired renal function, aging and
20 obesity augment the progression of DD in these patients. [57] Furthermore, DD tends to improve
21 during anti-hypertensive treatment [58-60], which makes it a valuable tool to test therapy efficacy,
22 since it is also easily assessed through the echocardiographic exam.

23 *3.1 The role of hypertensive-induced DD in heart failure*

1 AH is one of the main risk factor for the development of heart failure, in particular in
2 presence of preserved LVEF (HFpEF). Traditionally, HFpEF pathophysiology was explained by
3 several conditions that induced an increased LV work due to high afterload, while emerging
4 models have highlighted the role of systemic pro-inflammatory changes determined by different
5 comorbidities, including AH. [61, 62] In fact, one of the first signs of an increased LV afterload
6 corresponds to DD. When this pressure overload is sustained over time, diastolic function appears
7 more impaired, LV remodelling becomes progressively decompensated, and HFpEF ensues.[63-64]

8

9 **4. Left atrium**

10 LA is the other cardiac chamber affected by the pressure overload that accompanies AH. In
11 fact, when DD has developed, the contribute of LA to LV filling becomes essential, therefore LA
12 pressure tends to progressively increase, [65] which then leads to a gradual LA dilatation. It has
13 been proven that LA enlargement is proportional to the severity of DD and to the duration of the
14 hemodynamic overload [66], representing the memory of chronic increase of LA pressure in AH. As
15 a matter of fact, an increase of LA size frequently occurs in hypertensive patients, and besides DD,
16 it appears to correlate also with obesity, older age and particularly with a clear-cut LVH [67] LV
17 geometry and mechanics are important factors influencing LA afterload.

18 While 2018 ESC/ESH guidelines propose to identify LA dilation computing LA size as LA
19 volume indexed to height powered to 2 [6,68], the current ASE/EACVI echocardiographic
20 recommendations on diastolic function suggest that LA size should be assessed by measuring LA
21 volume indexed for BSA, a measure that is highly validated and commonly used in the clinical
22 practice. [11, 54] LA antero-posterior diameter, measurable in the parasternal long-axis view,

1 preferably using the 2D mode, despite largely applied in the past, does not accurately represent
2 the size of this chamber which is tridimensional. LA volume should be preferably assessed through
3 the biplane disk summation technique, since it is characterized by fewer geometric assumptions,
4 rather than through the area-length method. [11] In both cases, LA endocardial borders are traced
5 in the apical four- and two- chamber views. 3D-echocardiographic assessment of LA volume has
6 been shown promising results, it being more accurate in comparison with CMR. [67] Also 3D echo
7 derived LA phasic volumes have been demonstrated to correlate with hypertensive organ damage
8 (a LA active stroke volume index of 5.9 ml/m² predicted end-organ damage with a sensitivity of
9 82% and a specificity of 92%) [69] and with the severity of hypertensive retinopathy. [70]
10 However, these experiences are preliminary and 3D echo of LA volume should not be considered
11 in the routinely assess of AH.

12 STE could also help to assess LA function. A reduced LA strain was found in patients with
13 suboptimal control of blood pressure [71], it occurring before the onset of clear-cut LA dilatation
14 [72] and independently on LV longitudinal dysfunction. [73] In addition, when AH is complicated
15 by paroxysmal AF, STE-derived LA reservoir, conduit and pump function are early impaired. [74]

16

17 **5. Aorta**

18 Current ESC/ESH guidelines on AH put emphasis on the importance of evaluating arterial
19 stiffness [6,75] but not examining the aortic size at both ascending and abdominal level. Arterial
20 stiffness can be used to define asymptomatic organ damage in AH and is a substrate for the
21 development of resistant hypertension. It refers to the elastic properties of the aorta, which affect
22 vessel dimension, pressure and blood flow across every cardiac cycle [75]. It is also known to be a

1 predictor of adverse CV outcomes. [76] ESC/ESH guidelines propose the carotid-femoral pulse
2 wave velocity (PWV) as the gold standard to assess arterial stiffness [6,77]: the stiffer the arteries,
3 the higher the PWV. Therefore, correctly diagnosing and treating patients at the beginning of the
4 disease could prevent this further complication by limiting the aortic damage [78-79]. However,
5 this tool is not currently used in the clinical practice.

6 Although aorta is greatly affected by chronically elevated blood pressure, it is not
7 frequently evaluated in the routine echocardiographic work up of hypertensive patients.
8 Nevertheless, several studies demonstrated that AH accelerates the aging dependent enlargement
9 of thoracic aorta and particularly affects ascending aorta and aortic arch. This process can induce a
10 progressive dilatation and loss of shape of sino-tubular junction, causing aortic regurgitation. [80]
11 Functional classification of aortic root abnormalities responsible for aortic regurgitation provides
12 information for surgical management. This information can be useful for targeting the optimal
13 time and strategy for aortic valve-sparing surgery in ascending aorta aneurysms [81]. Hypertensive
14 induced ascending aorta dilation is also associated with both increased LVM and arterial stiffness.
15 [82-83] It is conceivable that AH could lead to a progressively increased mechanical stress on the
16 aortic wall, which in turn induces elastin fragmentation, and finally aortic dilatation. [83] Although
17 a certain degree of controversy exists about the effect of AH on the aortic root [84-86], recent
18 studies seem to demonstrate that elevation in diastolic blood pressure influences the aortic root
19 dilation, also in relation with the AH disease duration. [87]

20 According to these findings, the aortic diameters of hypertensive patients should be
21 determined at different levels with 2D echocardiography from the parasternal long-axis view.
22 According to the latest ASE/EACVI recommendations, [8] the aortic annulus should be measured
23 using the inner edge-to-inner edge, whereas it should be preferred the leading edge-to-leading

1 edge convention for measuring the aortic root and the ascending aorta. Notably, the ascending
2 aorta distensibility appears to be a non-invasive predictor of outcome and might therefore be
3 helpful for guiding the optimal anti-hypertensive treatment. [88] Recently, TDI has been used to
4 estimate the motion of the aortic wall; [89] the velocity values, expressing the aortic elasticity,
5 were found to be lower in hypertensive patients than in the normal population of the same age.
6 [90] In particular, the anterior wall motion velocity of the ascending aorta has been proven to be a
7 predictor of LV geometry and function. [91]

8 Also the abdominal aorta should be explored by ultrasound in hypertensive patients. AH is
9 one of the main risk factor for the development of abdominal aorta aneurysm (AAA). The
10 prognostic role of abdominal aorta evaluation has been recently investigated in patients awaiting
11 for endovascular repair of AAA [92], the dilation of abdominal aorta being independently
12 associated with long-term mortality in this cohort of patients. [93] These findings highlight the
13 possible screening power of abdominal aorta ultrasound assessment, which could be even
14 performed by using hand-held echocardiography [93]. Diameter measurements should be
15 performed in the plane perpendicular to the arterial axis, to avoid any overestimation of the actual
16 diameter.

17 **6. Aortic valve: aortic regurgitation and paradoxical Low flow low gradient aortic stenosis**

18 AH may induce a mechanical damage on the aortic valve, causing abnormally high stress on
19 aortic leaflets, turbulent flow and endothelial injury, and subsequent progression towards
20 alteration in aortic valve morphology, causing both aortic regurgitation and stenosis [94].
21 Therefore, the evaluation of aortic valve morphology and function represent a valuable point in
22 echo providing information. Aortic valve regurgitation may be due to accelerated AH induced
23 valve deterioration or it could be functional. In this second circumstance, functional aortic

1 regurgitation is mainly associated to tethering of the leaflets, it depending on the sino-tubular
2 junction/annulus mismatch, as a consequence of ascending aorta dilatation [81, 95].
3 AH and aortic stenosis are often concomitant diseases, particularly in the elderly patients [95-97].
4 Accordingly, the echocardiographic assessment of aortic valve area and gradients is extremely
5 useful for detecting and monitoring the progression of aortic stenosis in AH [98]. A particular type
6 of aortic stenosis, the paradoxical low flow low gradient aortic stenosis, has been typically
7 described in hypertensive patients. It is characterized by a mismatch between aortic valve area
8 and mean pressure gradient: aortic valve area is severely reduced in presence of low mean
9 pressure gradient. The diagnosis of paradoxical low flow low gradient aortic stenosis is performed
10 when valve area $<1 \text{ cm}^2$ with a peak velocity $<4\text{m/s}$, a mean pressure gradient $<40 \text{ mmHg}$ and
11 stroke volume index $<35 \text{ mL/m}^2$ despite normal LVEF. LV features of low flow low gradient aortic
12 stenosis include LV concentric geometry and small LV volume [98]. It is conceivable that the
13 hypertensive heart, characterized by deep remodelling with the presence of LV small diameters,
14 LV concentric geometry, high ventricular wall stiffness and reduced LV stroke volume, could not be
15 prone to bear the impact of aortic stenosis. Thus, paradoxical low flow low gradient aortic stenosis
16 is associated with poor prognosis. [99] In some cases it is often difficult to perform a differential
17 diagnosis between paradoxical low flow low gradient aortic stenosis and pseudo-severe aortic
18 stenosis. Evaluation of calcification degree with Agatston calcium score by multi-slice computed
19 tomography may be helpful in this setting and can resolve the diagnosis [98]. Based on the above
20 mentioned evidences, a thorough echocardiographic assessment in patients affected by AH should
21 not overlook valve evaluation.

22 23 **8. Echocardiographic parameters having a prognostic impact in AH**

1 An appropriate diagnosis of AH and correct assessment of CV risk are essential to initiate
2 antihypertensive treatment. Echocardiography is a very helpful tool in this context, not only for
3 the evaluation of organ damage, but also for defying the prognostic profile of a given hypertensive
4 patient. LVH and LV geometric pattern provide important prognostic information [7]. LV concentric
5 hypertrophy is associated with an increased rate of mortality and CV events, even after adjusting
6 for other CV risk factors including LVM, and showing the greatest mortality risk in patients with
7 suspected coronary artery disease [7,100,101]. Also increased LA volume is a prognostic indicator
8 of CV morbidity and mortality, and a LA volume greater than 34 ml/m² was associated with poor
9 prognosis including death, heart failure, AF, and ischemic stroke [102-103]. The most consistent
10 evidence regards LA volume rather than LA area and LA antero-posterior diameter [104-106]. LA
11 dilation is also expression of DD and increased LV filing pressures. Accordingly, DD and in
12 particular E/e' ratio have been shown to be strong predictors of heart failure and CV events,
13 independently on several confounders including LVM [54,55]. **Table 2** shows the main
14 echocardiographic parameters predicting poor prognosis in patients affected by AH.
15 **Unfortunately, evidence on sensitivity and specificity of those parameters in predicting CV events**
16 **is lacking in the hypertensive setting.**

17

18 **9. Conclusions**

19 The role of echocardiography in the thorough assessment of the hypertensive patient is
20 **very useful**, since it allows the measurement of several parameters that correlate with organ
21 damage. **Figure 4** summarizes the echocardiographic parameters that should be evaluated in
22 hypertensive patients. Besides LVH and LA enlargement identified from current ESC/ESH
23 guidelines on AH to detect cardiac injury, multiple echocardiographic parameters, such as GLS, LA

1 strain and diastolic evaluation could identify an early heart impairment. The evaluation of LV and
2 LA function, rather than the simple measure of their dimensions, has given promising results in
3 early detection of cardiac dysfunction, which might help identifying patients that can benefit from
4 a more aggressive treatment and a closer follow-up. Also the evaluation of DD is extremely
5 important, because it can occur before the development of LV geometry changes. Moreover, in a
6 complete overview on AH induced cardiac impairment the assessment of aortic dimension and
7 aortic valve function should not be overlooked. In this context, the combination of standard and
8 advanced echocardiographic techniques should be carefully considered in order to diagnose
9 subclinical cardiac organ damage, stratify prognosis and address management at the best.

10 In this view, based on a preliminary clinical assessment, the echocardiographic evaluation
11 could gather the maximum of relevant information on heart and aorta by influencing patients'
12 treatment, and also establishing correct timing of follow-up. Accordingly, under well defined
13 circumstances, echocardiography could present even a valuable cost/effectiveness ratio in
14 hypertensive patients.

15

16

17

18

19

20

21

22

23

24

25

26

27

28

29

30

1 References

- 2 1. Chow CK, Teo KK, Rangarajan S, Islam S, Gupta R, Avezum A et al. Prevalence, awareness, treatment,
3 and control of hypertension in rural and urban communities in high-, middle-, and low-income
4 countries. *JAMA*. 2013;310:959-96
- 5 2. Lewington S, Clarke R, Qizilbash N, Peto R, Collins R. Age-specific relevance of usual blood pressure to
6 vascular mortality: a meta-analysis of individual data for one million adults in 61 prospective studies.
7 *Lancet*. 2002;360:1903-1913.
- 8 3. Mattioli AV, Sciomer S, Moscucci F, Maiello M, Cugusi L, Gallina S, Dei Cas A, Lombardi C, Pengo M,
9 Parati G, Barilla F, Ciccone MM, Palmiero P, Mercurio G, Maffei S. Cardiovascular prevention in women:
10 a narrative review from the Italian Society of Cardiology working groups on 'Cardiovascular Prevention,
11 Hypertension and peripheral circulation' and on 'Women Disease'. *J Cardiovasc Med (Hagerstown)*.
12 2019;20:575-583.
- 13 4. Cameli M, Mandoli GE, Ambrosio G, Cerbai E, Coiro S, Emdin M, et al. Arterial hypertension and atrial
14 fibrillation: standard and advanced echocardiography from diagnosis to prognostication. *J Cardiovasc*
15 *Med (Hagerstown)*. 2018;19:51-61.
- 16 5. Devereux RB, Alderman MH. Role of preclinical cardiovascular disease in the evolution from risk factor
17 exposure to development of morbid events. *Circulation*. 1993;88:1444–1455
- 18 6. Williams B, Mancia G, Spiering W, Agabiti Rosei E, Azizi M, Burnier M, et al. ESC/ESH Guidelines for the
19 management of arterial hypertension. *J Hypertens*. 2018;36:1953-2041.
- 20 7. Levy D, Garrison RJ, Savage DD, Kannel WB, Castelli WP. Prognostic implications of
21 echocardiographically determined left ventricular mass in the Framingham Heart Study. *N Engl J Med*.
22 1990 ;322:1561-1566.
- 23 8. Lang RM, Badano LP, Mor-Avi V, Afilalo J, Armstrong A, Ernande L, et al. Recommendations for cardiac
24 chamber quantification by echocardiography in adults: an update from the American Society of
25 Echocardiography and the European Association of Cardiovascular Imaging. *J Am Soc Echocardiogr*.
26 2015;28:1-39.e14.
- 27 9. Salvetti M, Pains A, Bertacchini F, Stassaldi D, Aggiusti C, Agabiti Rosei C, et al. Changes in left
28 ventricular geometry during antihypertensive treatment. *Pharmacol Res*. 2018;134:193-199
- 29 10. Devereux RB, Wachtell K, Gerds E, Boman K, Nieminen MS, Papademetriou V, et al. Prognostic
30 significance of left ventricular mass change during treatment of hypertension. *JAMA*. 2004;292:2350-
31 2356.
- 32 11. Galderisi M, Cosyns B, Edvardsen T, Cardim N, Delgado V, Di Salvo G, et al. Standardization of adult
33 transthoracic echocardiography reporting in agreement with recent chamber quantification, diastolic
34 function, and heart valve disease recommendations: an expert consensus document of the European
35 Association of Cardiovascular Imaging. *Eur Heart J Cardiovasc Imaging*. 2017;18:1301-1310.
- 36 12. Devereux RB, Alonso DR, Lutas EM, Gottlieb GJ, Campo E, Sachs I, Reichek N. Echocardiographic
37 assessment of left ventricular hypertrophy: comparison to necropsy findings. *Am J Cardiol*.
38 1986;57:450-458.
- 39 13. Lang RM, Bierig M, Devereux RB, Flachskampf FA, Foster E, Pellikka PA, et al. Recommendations for
40 chamber quantification *Eur J Echocardiogr*. 2006;7:79-108.
- 41 14. de Simone G, Kizer JR, Chinali M, Roman MJ, Bella JN, Best LG, et al. Normalization for body size and
42 population-attributable risk of left ventricular hypertrophy: the Strong Heart Study. *Am J Hypertens*
43 2005;18:191-196.
- 44 15. Chirinos JA, Segers P, De Buyzere ML, Kronmal RA, Raja MW, De Bacquer D, et al. Left ventricular mass:
45 allometric scaling, normative values, effect of obesity, and prognostic performance. *Hypertension*.
46 2010;56:91-98.

- 1 16. Cuspidi C, Meani S, Negri F, Giudici V, Valerio C, Sala C, Zanchetti A, Mancia G. Indexation of left
2 ventricular mass to body surface area and height to allometric power of 2.7: is the difference limited to
3 obese hypertensives? *J Hum Hypertens.* 2009;23:728-734.
- 4 17. Gidding SS, Liu K, Colangelo LA, Cook NL, Goff DC, Glasser SP, Gardin JM, Lima JAC. Longitudinal
5 Determinants of Left Ventricular Mass and Geometry: The CARDIA Study. *Circ Cardiovasc Imaging.*
6 2013;6:769-775.
- 7 18. Gottdiener JS. Value and challenges of measuring left ventricular mass in clinical research: implications
8 for the practitioner. *Circ Cardiovasc Imaging.* 2013;6:612-613.
- 9 19. Takeuchi M, Nishikage T, Mor-Avi V, Sugeng L, Weinert L, Nakai H, et al. Measurement of left
10 ventricular mass by real-time three-dimensional echocardiography: validation against magnetic
11 resonance and comparison with two-dimensional and M-mode measurements. *J Am Soc Echocardiogr.*
12 2008;21:1001-1005.
- 13 20. Mor-Avi V, Sugeng L, Weinert L, MacEneaney P, Caiani EG, Koch R, et al. Fast measurement of left
14 ventricular mass with real-time three dimensional echocardiography: comparison with magnetic
15 resonance imaging. *Circulation* 2004; 110:1814-1818.
- 16 21. Yap SC, van Geuns RJ, Nemes A, Meijboom FJ, McGhie JS, Geleijnse ML, et al. Rapid and accurate
17 measurement of LV mass by biplane realtime 3D echocardiography in patients with concentric LV
18 hypertrophy: comparison to CMR. *Eur J Echocardiogr* 2008; 9:255-260.
- 19 22. Shimada YJ, Shiota T. Meta-analysis of accuracy of left ventricular mass measurement by three-
20 dimensional echocardiography. *Am J Cardiol.* 2012;110:445-452.
- 21 23. Krishnamoorthy A, Brown T, Ayers CR, Gupta S, Rame JE, Patel PC, et al. Progression from normal to
22 reduced left ventricular ejection fraction in patients with concentric left ventricular hypertrophy after
23 long-term follow-up. *Am J Cardiol.* 2011; 108:997-1001
- 24 24. Tsao CW, Gona PN, Salton CJ, Chuang ML, Levy D, Manning WJ, O'Donnell CJ. Left Ventricular Structure
25 and Risk of Cardiovascular Events: A Framingham Heart Study Cardiac Magnetic Resonance Study. *J Am*
26 *Heart Assoc.* 2015;4(9):e002188.
- 27 25. Cameli M, Lisi M, Righini FM, Massoni A, Mondillo S. Left ventricular remodeling and torsion dynamics
28 in hypertensive patients. *Int J Cardiovasc Imaging.* 2013;29:79-86.
- 29 26. D'Andrea A, Radmilovic J, Ballo P, Mele D, Agricola E, Cameli M, et al. Left ventricular hypertrophy or
30 storage disease? the incremental value of speckle tracking strain bull's-eye. *Echocardiography.*
31 2017;34:746-759.
- 32 27. Esposito R, Galderisi M, Santoro C, Imbriaco M, Riccio E, Maria Pellegrino A, et al. Prominent
33 longitudinal strain reduction of left ventricular basal segments in treatment-naïve Anderson-Fabry
34 disease patients. *Eur Heart J Cardiovasc Imaging.* 2019;20:438-445
- 35 28. Gaasch WH, Zile MR. Left ventricular structural remodeling in health and disease: with special emphasis
36 on volume, mass, and geometry. *J Am Coll Cardiol.* 2011;58: 1733-1740
- 37 29. de Simone G, Izzo R, Aurigemma GP, De Marco M, Rozza F, Trimarco V, et al. Cardiovascular risk in
38 relation to a new classification of hypertensive left ventricular geometric abnormalities. *J Hypertens*
39 2015;33:745-754.
- 40 30. Khouri MG, Peshock RM, Ayers CR, de Lemos JA, Drazner MH. A 4-tiered classification of left ventricular
41 hypertrophy based on left ventricular geometry: the Dallas heart study. *Circ Cardiovasc Imaging.* 2010;
42 3:164-171.
- 43 31. Bang CN, Gerds E, Aurigemma GP, Boman K, de Simone G, Dahlof B. Four-group classification of left
44 ventricular hypertrophy based on ventricular concentricity and dilatation identifies a low-risk subset of
45 eccentric hypertrophy in hypertensive patients. *Circ Cardiovasc Imaging.* 2014; 7:422-429.
- 46 32. Verdecchia P, Angeli F, Mazzotta G, Bartolini C, Garofoli M, Aita A, et al. Impact of Chamber Dilatation
47 on the Prognostic Value of Left Ventricular Geometry in Hypertension. *J Am Heart Assoc.* 2017;6, pii:
48 e005948.

- 1 33. Rodrigues JC, Amadu AM, Dastidar AG, Szantho GV, Lyen SM, Godsave C, et al. Comprehensive
2 characterisation of hypertensive heart disease left ventricular phenotypes. *Heart*. 2016;102:1671-1679
- 3 34. Lembo M, Esposito R, Santoro C, Lo Iudice F, Schiano-Lomoriello V, Fazio V, et al. Three-dimensional
4 echocardiographic ventricular mass/end-diastolic volume ratio in native hypertensive patients: relation
5 between stroke volume and geometry. *J Hypertens*. 2018;36:1697-1704.
- 6 35. Lembo M, Santoro C, Sorrentino R, Trimarco B, Galderisi M, Esposito R. Impact of left ventricular
7 mass/end-diastolic volume ratio by three-dimensional echocardiography on two-dimensional global
8 longitudinal strain and diastolic function in native hypertensive patients. *J Hypertens*. 2019;37:2041-
9 2047
- 10 36. Narayanan A, Aurigemma GP, Chinali M, Hill JC, Meyer TE, Tighe DA. Cardiac mechanics in mild
11 hypertensive heart disease: a speckle-strain imaging study. *Circ Cardiovasc Imaging*. 2009;2:382-390.
- 12 37. Thavendiranathan P, Grant AD, Negishi T, Plana JC, Popović ZB, Marwick TH. Reproducibility of
13 echocardiographic techniques for sequential assessment of left ventricular ejection fraction and
14 volumes: application to patients undergoing cancer chemotherapy. *J Am Coll Cardiol*. 2013;61:77-84.
- 15 38. Otterstad JE. Measuring left ventricular volume and ejection fraction with the biplane Simpson's
16 method. *Heart* 2002;88:559-560
- 17 39. de Simone G, Devereux RB, Koren MJ, Mensah GA, Casale PN, Laragh JH. Midwall left ventricular
18 mechanics. An independent predictor of cardiovascular risk in arterial hypertension. *Circulation*
19 1996;93:259-265.
- 20 40. Mérillon JP, Ennezat PV, Guiomard A, Masquet-Gourgon C, Aumont MC, Gourgon R. Left ventricular
21 performance is closely related to the physical properties of the arterial system: Landmark clinical
22 investigations in the 1970s and 1980s. *Arch Cardiovasc Dis*. 2014;107:554-562.
- 23 41. Cameli M, Mondillo S, Solari M, Righini FM, Andrei V, Contaldi C, De Marco E, Di Mauro M, Esposito R,
24 Gallina S, Montisci R, Rossi A, Galderisi M, Nistri S, Agricola E, Mele D. Echocardiographic assessment of
25 left ventricular systolic function: from ejection fraction to torsion. *Heart Fail Rev*. 2016;21:77-94.
- 26 42. Merillon JP, Masquet C, Dahan M, Juliard JM, Azancot I, Motte G, Gourgon R. Changes in left ventricular
27 performance during chronic pressure or volume overload: importance of physical properties of the
28 arterial system. *J Cardiovasc Pharmacol* 1985;7(Suppl. 2):S36-40.
- 29 43. Farsalinos KE, Daraban AM, Ünlü S, Thomas JD, Badano LP, Voigt JU. Head-to-Head Comparison of
30 Global Longitudinal Strain Measurements among Nine Different Vendors: The EACVI/ASE Inter-Vendor
31 Comparison Study. *J Am Soc Echocardiogr*. 2015;28:1171-1181
- 32 44. Tadic M, Cuspidi C, Majstorovic A, Kocijancic V, Celic V. The relationship between left ventricular
33 deformation and different geometric patterns according to the updated classification: findings from the
34 hypertensive population. *J Hypertens* 2015;33:1954-1961.
- 35 45. Lembo M, Esposito R, Lo Iudice F, Santoro C, Izzo R, De Luca N, et al. Impact of pulse pressure on left
36 ventricular global longitudinal strain in normotensive and newly diagnosed, untreated hypertensive
37 patients. *J Hypertens* 2016; 34:1201-1207.
- 38 46. Contaldi C, Imbriaco M, Alcidi G, Ponsiglione A, Santoro C, Puglia M, et al. Assessment of the
39 relationships between left ventricular filling pressures and longitudinal dysfunction with myocardial
40 fibrosis in uncomplicated hypertensive patients. *Int J Cardiol*. 2016;202:84-86.
- 41 47. Kalam K, Otahal P, Marwick TH. Prognostic implications of global LV dysfunction: a systematic review
42 and meta-analysis of global longitudinal strain and ejection fraction. *Heart*. 2014;100:1673-1680.
- 43 48. Imbalzano E, Zito C, Carerj, Oreto G, Mandraffino G, Cusmà-Piccione M et al. Left ventricular function in
44 hypertension: new insight by speckle tracking echocardiography. *Echocardiography*. 2011;28:649-657.
- 45 49. Galderisi M, Trimarco B. Global longitudinal strain: a novel hallmark of cardiac risk in arterial
46 hypertension. *J Hypertens*. 2016;34:1050-1051.
- 47 50. Cameli M, Mondillo S, Righini FM, Lisi M, Dokollari A, Lindqvist P, Maccherini M, Henein M. Left
48 Ventricular Deformation and Myocardial Fibrosis in Patients With Advanced Heart Failure Requiring
49 Transplantation. *J Card Fail*. 2016;22:901-907.

- 1 51. Galderisi M, Esposito R, Schiano-Lomoriello V, Santoro A, Ippolito R, Schiattarella P et al. Correlates of
2 global area strain in native hypertensive patients: a three-dimensional speckle-tracking
3 echocardiography study. *Eur Heart J Cardiovasc Imaging*. 2012;13:730-738.
- 4 52. Nadrux W, Shah AM, Solomon SD. Diastolic dysfunction and hypertension. *Med Clin North Am*. Am.
5 2017;101:7-17.
- 6 53. Wan SH, Vogel MW, Chen HH. Pre-clinical diastolic dysfunction. *J Am Coll Cardiol*. 2014;63:407-416.
- 7 54. Nagueh SF, Smiseth OA, Appleton CP, Byrd BF 3rd, Dokainish H, Edvardsen T, et al. Recommendations
8 for the Evaluation of Left Ventricular Diastolic Function by Echocardiography: An Update from the
9 American Society of Echocardiography and the European Association of Cardiovascular Imaging. *J Am
10 Soc Echocardiogr*. 2016;29:277-314.
- 11 55. Dini FL, Galderisi M, Nistri S, Buralli S, Ballo P, Mele D, et al. Abnormal left ventricular longitudinal
12 function assessed by echocardiographic and tissue Doppler imaging is a powerful predictor of diastolic
13 dysfunction in hypertensive patients: the SPHERE study. *Int J Cardiol*. 2013;168:3351-3358.
- 14 56. Redon J, Tellez-Plaza M, Orozco-Beltran D, Gil-Guillen V, Pita Fernandez S, Navarro-Pérez J, et al. Impact
15 of hypertension on mortality and cardiovascular disease burden in patients with cardiovascular risk
16 factors from a general practice setting: the ESCARVAL-risk study. *J Hypertens*. 2016;34:1075-1083.
- 17 57. Tapp RJ, Sharp A, Stanton AV, O'Brien E, Chaturvedi N, Poulter NR et al. Differential effects of
18 antihypertensive treatment on left ventricular diastolic function: an ASCOT (Anglo-Scandinavian Cardiac
19 Outcomes Trial) substudy. *J Am Coll Cardiol*. 2010;55:1875-1881.
- 20 58. Kwon BJ, Lee SH, Park CS, Kim DB, Park HJ, Jang SW, et al. Left ventricular diastolic dyssynchrony in
21 patients with treatment-naive hypertension and the effects of antihypertensive therapy. *J Hypertens*.
22 2015;33:354-65.
- 23 59. Wachtell K, Bella JN, Rokkedal J, Palmieri V, Papademetriou V, Dahlöf B et al. Change in diastolic left
24 ventricular filling after one year of antihypertensive treatment: The Losartan Intervention For Endpoint
25 Reduction in Hypertension (LIFE) Study. *Circulation*. 2002;105:1071-1076.
- 26 60. Solomon SD, Verma A, Desai A, Hassanein A, Izzo J, Oparil S et al. Effect of intensive versus standard
27 blood pressure lowering on diastolic function in patients with uncontrolled hypertension and diastolic
28 dysfunction. *Hypertension*. 2010;55:241-248.
- 29 61. Tam MC, Lee R, Cascino TM, Konerman MC, Hummel SL. Current Perspectives on Systemic
30 Hypertension in Heart Failure with Preserved Ejection Fraction. *Curr Hypertens Rep*. 2017;19:12
- 31 62. Messerli FH, Rimoldi AF, Bangalore S. The transition from hypertension to heart failure. *JACC: heart fail*.
32 2017;5:543-551.
- 33 63. Gaasch WH, Zile MR. Left ventricular diastolic dysfunction and diastolic heart failure. *Annu Rev Med*.
34 2004;55:373-94.
- 35 64. Oh JK, Hatle L, Tajik AJ, Little WC. Diastolic heart failure can be diagnosed by comprehensive two-
36 dimensional and Doppler echocardiography. *J Am Coll Cardiol*. 2006; 47:500-506.
- 37 65. Losi MA, Izzo R, Canciello G, Giamundo A, Manzi MV, Strisciuglio T, et al. Atrial Dilatation Development
38 in Hypertensive Treated Patients: The Campania-Salute Network. *Am J Hypertens*. 2016;29:1077-1084.
- 39 66. Mor-Avi V, Yodwut C, Jenkins C, Kuhl H, Nesser HJ, Marwick TH, et al. Real-time 3D echocardiographic
40 quantification of left atrial volume: multicenter study for validation with CMR. *JACC Cardiovasc
41 Imaging*. 2012;5:769-777.
- 42 67. Caselli S, Canali E, Foschi ML, Santini D, Di Angelantonio E, Pandian NG, De Castro S. Longterm
43 prognostic significance of three-dimensional echocardiographic parameters of the left ventricle and
44 left atrium. *Eur J Echocardiogr*. 2010;11:250-256.
- 45 68. Kuznetsova T, Haddad F, Tikhonoff V, Kloch-Badelek M, Ryabikov A, Knez J et al. Impact and pitfalls of
46 scaling of left ventricular and atrial structure in population-based studies. *J Hypertens*. 2016;34:1186-
47 1194.

- 1 69. Kanar B, Ozben B, Kanar HS, Arsan A, Tigen K. Left atrial volume changes are an early marker of end-
2 organ damage in essential hypertension: A multidisciplinary approach to an old problem.
3 Echocardiography. 2017;34:1895-1902.
- 4 70. Cuspidi C, Meani S, Valerio C, Fusi V, Catini E, Sala C et al. Prevalence and correlates of advanced
5 retinopathy in a large selected hypertensive population. Evaluation of Target Organ Damage in
6 Hypertension (ETODH) study. Blood Pressure. 2005;14:25-31.
- 7 71. Chen XJ, Chen C, Liang YJ, Gao XL, Jiang J, Kang Y, et al. Decreased left atrial myocardial strain in
8 patients with suboptimal blood pressure control. Clin Exp Hypertens. 2017;39:481-488.
- 9 72. Mondillo S, Cameli M, Caputo ML, Lisi M, Palmerini E, Padeletti M, Ballo P. Early detection of left atrial
10 strain abnormalities by speckle-tracking in hypertensive and diabetic patients with normal left atrial
11 size. J Am Soc Echocardiogr. 2011;24:898-908.
- 12 73. Cameli M, Mandoli GE, Lisi E, Ibrahim A, Incampo E, Buccoliero G, et al. Left atrial, ventricular and atrio-
13 ventricular strain in patients with subclinical heart dysfunction. Int J Cardiovasc Imaging. 2019;35:249-
14 258.
- 15 74. Jarasunas J, Aidietis A, Aidietiene S. Left atrial strain - an early marker of left ventricular diastolic
16 dysfunction in patients with hypertension and paroxysmal atrial fibrillation. Cardiovasc Ultrasound.
17 2018;16:29
- 18 75. Sharman JE, Boutouyrie P, Laurent S. Arterial (Aortic) Stiffness in Patients with Resistant Hypertension:
19 from Assessment to Treatment. Curr Hypertens Rep. 2017;19:2.
- 20 76. Muxfeldt ES, Cardoso CR, Dias VB, Nascimento AC, Salles GF. Prognostic impact of the ambulatory
21 arterial stiffness index in resistant hypertension. J Hypertens. 2010;28:1547-1553.
- 22 77. Mancia G, Fagard R, Narkiewicz K, Redón J, Zanchetti A, Böhm M, et al. ESH/ESC guidelines for the
23 management of arterial hypertension: the task force for the management of arterial hypertension of
24 the European Society of Hypertension (ESH) and of the European Society of Cardiology (ESC). J
25 Hypertens. 2013;31:1281-357.
- 26 78. Williams B. The aorta and resistant hypertension. J Am Coll Cardiol. 2009;53:452-4.
- 27 79. Lembo M, Sicari R, Esposito R, Rigo F, Cortigiani L, Lo Iudice F, et al. Association Between Elevated Pulse
28 Pressure and High Resting Coronary Blood Flow Velocity in Patients With Angiographically Normal
29 Epicardial Coronary Arteries. J Am Heart Assoc. 2017;6(7). pii: e005710.
- 30 80. Craiem D, Chironi G, Casciaro ME, Redheuil A, Mousseaux E, Simon A. Three-dimensional evaluation of
31 thoracic aorta enlargement and unfolding in hypertensive men using non-contrast computed
32 tomography. J Hum Hypertens. 2013;27:504-9.
- 33 81. Evangelista A, Flachskampf FA, Erbel R, Antonini-Canterin F, Vlachopoulos C, Rocchi G, et al.
34 Echocardiography in aortic diseases: EAE recommendations for clinical practice. Eur J Echocardiogr.
35 2010;11:645-58
- 36 82. Milan A, Tosello F, Naso D, Avenatti E, Leone D, Magnino C, Veglio F. Ascending aortic dilatation,
37 arterial stiffness and cardiac organ damage in essential hypertension. J Hypertens. 2013;31:109-16.
- 38 83. Cuspidi C, Meani S, Negri F, Sala C, Mancia G. Left ventricular hypertrophy and abdominal aorta size in
39 essential hypertension. J Hypertens. 2011;29:1213-9.
- 40 84. Vizzardi E, Maffessanti F, Lorusso R, Sciatti E, Bonadei I, Gelsomino S, et al. Ascending Aortic
41 Dimensions in Hypertensive Subjects: Reference Values for Two-Dimensional Echocardiography. J Am
42 Soc Echocardiogr. 2016;29:827-37
- 43 85. Mulè G, Nardi E, Morreale M, Castiglia A, Geraci G, Altieri D, et al. The Relationship Between Aortic
44 Root Size and Hypertension: An Unsolved Conundrum. Adv Exp Med Biol. 2017;956:427-445.
- 45 86. Campens L, Demulier L, De Groot K, Vandekerckhove K, De Wolf D, Roman MJ, et al. Reference values
46 for echocardiographic assessment of the diameter of the aortic root and ascending aorta spanning all
47 age categories. Am J Cardiol. 2014;114:914-920.
- 48 87. Teixido-Tura G, Almeida AL, Choi EY, Gjesdal O, Jacobs DR Jr, Dietz HC, et al. Determinants of aortic root
49 dilatation and reference values among young adults over a 20-year period: coronary artery risk
50 development in young adults study. Hypertension. 2015;66:23-29.

- 1 88. Jia CF, Wang ZQ, Sun XX, Yang ZQ, Zou YJ, Jiang YN. Ascending aortic distensibility and target organ
2 damage in primary hypertension without diabetes. *Int J Cardiovasc Imaging*. 2017;33:1245-1251.
- 3 89. Harada K, Yasuoka K, Shimada Y. Usefulness of tissue doppler imaging for assessing aortic wall stiffness
4 in children with the Marfan syndrome. *Am J Cardiol*. 2004;93:1072-1075
- 5 90. Lu Y, Deng Y, Wang Q, Chen F, Huang Y, Lv Y et al. Assessment of ascending aortic elasticity in
6 hypertension patients by quantitative tissue velocity imaging. *J Huazhong Univ Sci Technolog Med Sci*.
7 2009;29:782-5.
- 8 91. Luo C, Liu Y, Li Z, Lin J, Chen R, Zhang T, et al. Correlations between anterior wall motion velocity of
9 ascending aorta measured by quantitative tissue velocity image and left ventricular geometry as well as
10 left heart function in hypertension patients. *Minerva Cardioangiol*. 2018;66:136-142
- 11 92. O'Driscoll JM, Bahia SS, Gravina A, Di Fino S, Thompson MM, Karthikesalingam A, et al. Transthoracic
12 Echocardiography Provides Important Long-Term Prognostic Information in Selected Patients
13 Undergoing Endovascular Abdominal Aortic Repair. *Circ Cardiovasc Imaging*. 2016;9:e003557.
- 14 93. Esposito R, Ilardi F, Schiano Lomoriello V, Sorrentino R, Sellitto V, Giugliano G, et al. Identification of the
15 main determinants of abdominal aorta size: a screening by Pocket Size Imaging Device. *Cardiovasc*
16 *Ultrasound*. 2017;15:2.
- 17 94. Liakos CI, Grassos CA, Papadopoulos DP, Dimitriadis KS, Tsioufis CP, Tousoulis D. Arterial hypertension
18 and aortic valve stenosis: Shedding light on a common "liaison". *Hellenic J Cardiol*. 2017;58:261-266.
- 19 95. Katsi V, Georgiopoulos G, Oikonomou D, Aggeli C, Grassos C, Papadopoulos DP et al. Aortic Stenosis,
20 Aortic Regurgitation and Arterial Hypertension. *Curr Vasc Pharmacol*. 2019;17:180-190.
- 21 96. Rieck ÅE, Cramariuc D, Boman K, Gohlke-Bärwolf C, Staal EM, Lønnebakken MT, et al. Hypertension in
22 aortic stenosis: implications for left ventricular structure and cardiovascular events. *Hypertension*.
23 2012;60:90-97.
- 24 97. Saeed S, Mancia G, Rajani R, Parkin D, Chambers JB. Hypertension in aortic stenosis: relationship with
25 revealed symptoms and functional measures on treadmill exercise. *J Hypertens*. 2019 May 30. doi:
26 10.1097/HJH.0000000000002149. [Epub ahead of print]
- 27 98. Baumgartner H, Hung J, Bermejo J, Chambers JB, Edvardsen T, Goldstein S, et al. Recommendations on
28 the Echocardiographic Assessment of Aortic Valve Stenosis: A Focused Update from the European
29 Association of Cardiovascular Imaging and the American Society of Echocardiography. *J Am Soc*
30 *Echocardiogr*. 2017;30:372-392.
- 31 99. Pibarot P, Dumesnil JG. Paradoxical low-flow, low-gradient aortic stenosis: new evidence, more
32 questions. *Circulation*. 2013;128:1729-1732.
- 33 100. Krumholz HM, Larson M, Levy D. Prognosis of left ventricular geometric patterns in the Framingham
34 heart study. *J Am Coll Cardiol*. 1995;25:879-884.
- 35 101. Ghali JK, Liao Y, Cooper RS. Influence of left ventricular geometric patterns on prognosis in patients
36 with or without coronary artery disease. *J Am Coll Cardiol*. 1998;31:1635-1640.
- 37 102. Russo C, Jin Z, Homma S, Rundek T, Elkind MS, Sacco RL, et al. Left atrial minimum volume and
38 reservoir function as correlates of left ventricular diastolic function: impact of left ventricular systolic
39 function. *Heart*. 2012;98:813-820.
- 40 103. Piotrowski G, Banach M, Gerdtts E, Mikhailidis DP, Hannam S, Gawor R, et al. Left atrial size in
41 hypertension and stroke. *J Hypertens*. 2011;29:1988-1993.
- 42 104. Tsang TS, Barnes ME, Bailey KR, Leibson CL, Montgomery SC, Takemoto Y, et al. Left atrial volume:
43 important risk marker of incident atrial fibrillation in 1655 older men and women. *Mayo Clin Proc*.
44 2001;76:467-475.
- 45 105. Verdecchia P, Reboldi G, Gattobigio R, Bentivoglio M, Borgioni C, Angeli F, et al. Atrial fibrillation in
46 hypertension: predictors and outcome. *Hypertension* 2003; 41:218–223.

- 1 106. Gardin JM, McClelland R, Kitzman D, Lima JA, Bommer W, Klopfenstein HS, et al. M-mode
2 echocardiographic predictors of six- to seven-year incidence of coronary heart disease, stroke,
3 congestive heart failure, and mortality in an elderly cohort (the Cardiovascular Health Study). *Am J*
4 *Cardiol* 2001;87:1051-1057.
- 5 107. Ilercil A, O'Grady MJ, Roman MJ, Paranicas M, Lee ET, Welty TK et al. Reference values for
6 echocardiographic measurements in urban and rural populations of differing ethnicity: the Strong Heart
7 Study. *J Am Soc Echocardiogr*. 2001;14:601-611.
- 8 108. Devereux RB, Roman MJ, de Simone G, O'Grady MJ, Paranicas M, Yeh JL et al. Relations of left
9 ventricular mass to demographic and hemodynamic variables in American Indians: the Strong Heart
10 Study. *Circulation*. 1997;96:1416-1423.
- 11 109. de Simone G, Daniels SR, Devereux RB, Meyer RA, Roman MJ, de Divitiis O, Alderman MH. Left
12 ventricular mass and body size in normotensive children and adults: assessment of allometric relations
13 and impact of overweight. *J Am Coll Cardiol*. 1992;20:1251-1260.
- 14 110. Ganau A, Devereux RB, Roman MJ, de Simone G, Pickering TG, Saba PS et al. Patterns of left
15 ventricular hypertrophy and geometric remodeling in essential hypertension. *J Am Coll Cardiol*.
16 1992;19:1550-1558.
- 17 111. Park SH, Shub C, Nobrega TP, Bailey KR, Seward JB. Two-dimensional echocardiographic calculation
18 of left ventricular mass as recommended by the American Society of Echocardiography: correlation
19 with autopsy and M-mode echocardiography. *J Am Soc Echocardiogr*. 1996;9:119-128.
- 20 112. Mizukoshi K, Takeuchi M, Nagata Y, Addetia K, Lang RM, Akashi YJ, Otsuji Y. Normal Values of Left
21 Ventricular Mass Index Assessed by Transthoracic Three-Dimensional Echocardiography. *J Am Soc*
22 *Echocardiogr*. 2016;29:51-61.
- 23 113. Maceira AM, Prasad SK, Khan M, Pennell DJ. Normalized left ventricular systolic and diastolic
24 function by steady state free precession cardiovascular magnetic resonance. *J Cardiovasc Magn Reson*.
25 2006;8:417-426.
- 26 114. Rider OJ, Lewandowski A, Nethononda R, Petersen SE, Francis JM, Pitcher A. Gender-specific
27 differences in left ventricular remodeling in obesity: insights from cardiovascular magnetic resonance
28 imaging. *Eur Heart J*. 2013;34:292-299.
- 29 115. Armstrong AC, Gidding S, Gjesdal O, Wu C, Bluemke DA, Lima JA. LV mass assessed by
30 echocardiography and CMR, cardiovascular outcomes, and medical practice. *JACC Cardiovasc Imaging*.
31 2012;5:837-848.
- 32 116. Gosse P, Cremer A, Vircoulon M, Coulon P, Jan E, Papaioannou G, Yeim S. Prognostic value of the
33 extent of left ventricular hypertrophy and its evolution in the hypertensive patient. *J Hypertens*.
34 2012;30:2403-2409.
- 35 117. Abhayaratna WP, Seward JB, Appleton CP, Douglas PS, Oh JK, Tajik AJ, Tsang TS. Left atrial size:
36 physiologic determinants and clinical applications. *J Am Coll Cardiol*. 2006;47:2357-2363.
- 37 118. Aljaroudi W, Alraies MC, Halley C, Rodriguez L, Grimm RA, Thomas JD, Jaber WA. Impact of
38 progression of diastolic dysfunction on mortality in patients with normal ejection fraction. *Circulation*.
39 2012;125:782-788.

1 119. Bella JN, Palmieri V, Roman MJ, Liu JE, Welty TK, Lee ET et al. Mitral ratio of peak early to late
2 diastolic filling velocity as a predictor of mortality in middle-aged and elderly adults: the Strong Heart
3 Study. *Circulation*. 2002;105:1928-1933.

4
5
6
7
8
9
10
11
12
13
14
15
16
17
18
19
20
21
22
23
24
25
26

1 **Acknowledgements**

2 Dr. Maria Lembo, Dr. Ciro Santoro and Dr. Regina Sorrentino are supported by the International
3 PhD program in Cardiovascular Pathophysiology and Therapeutics, CardioPath

4
5
6
7
8
9
10
11
12
13
14
15
16
17
18
19
20
21
22
23
24
25
26
27
28
29
30
31
32
33
34
35
36
37
38
39
40
41
42
43
44

1 **Legend of Figures**

2 **Figure 1.** Schema showing different LV geometry based on the LVM index and RWT.

3 LV= left ventricular, LVM= left ventricular mass, RWT= relative wall thickness.

4

5 **Figure 2.** Diagnostic algorithm for diastolic dysfunction in hypertensive patients with normal LVEF
6 and absence of myocardial disease.

7 LA= left atrium, LV= left ventricular, LVEF= left ventricular ejection fraction, LVH= left ventricular
8 hypertrophy, TR= tricuspid regurgitation.

9

10 **Figure 3.** Diagnostic algorithm for diastolic dysfunction in patients with reduced LVEF or normal
11 left ventricular ejection fraction and concomitant myocardial disease.

12 LA= left atrium, LV= left ventricular, LVEF= left ventricular ejection fraction, LVH= left ventricular
13 hypertrophy, TR= tricuspid regurgitation.

14

15 **Figure 4.** Picture showing the echo parameters useful in the evaluation of the hypertensive
16 patient. **In bold letters the parameters that should always be assessed in hypertensive patients.**

17 EDV= end-diastolic volume, GLS= global longitudinal strain, LA= left atrium, LV= left ventricular,
18 LVEF= left ventricular ejection fraction, LVM= left ventricular mass, PWV= pulsed wave velocity,
19 RWT= relative wall thickness, TDI= tissue Doppler imaging, TR= tricuspid regurgitation.

20

21

22

Table 1. Parameters used for assessment of left ventricular geometry

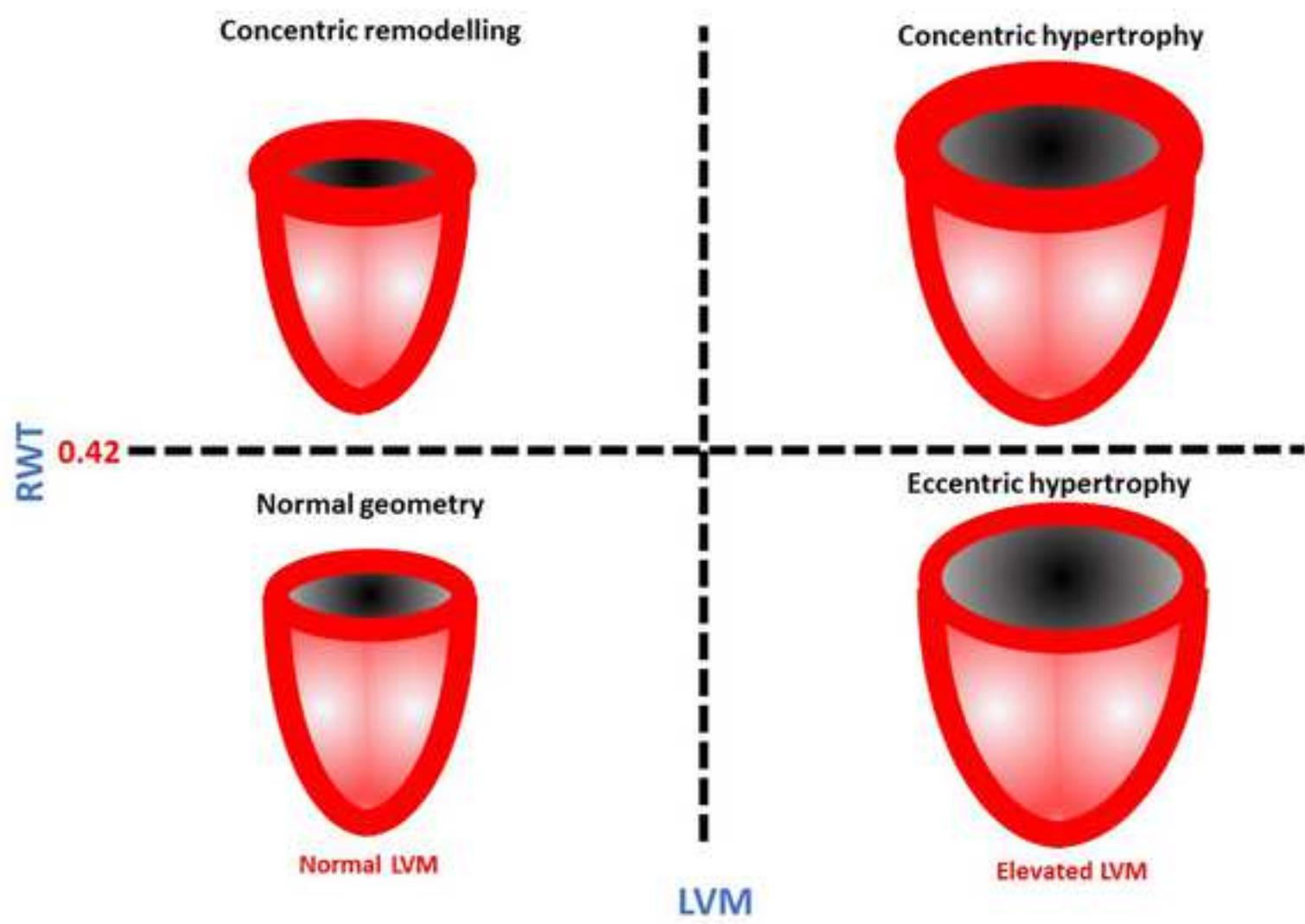
Method	Parameter	Thresholds of normalcy		References
Echo Linear method	LV mass (g)	Women ≤ 162	Men ≤ 224	1) Lang RM et al. Eur J Echocardiogr. 2006 Mar;7(2):79-108. [13] 2) Ilıcil A et al. J Am Soc Echocardiogr 2001;14:601e11. [107]
	LV mass/BSA (g/m^2)	Women ≤ 95	Men ≤ 115	1) Lang RM et al. Eur J Echocardiogr. 2006 Mar;7(2):79-108. [13] 2) Devereux RB et al. Circulation 1997;96:1416e23. [108]
	LV mass/height (g/m) ^{2.7}	Women ≤ 45	Men ≤ 49	1) Lang RM et al. Eur J Echocardiogr. 2006 Mar;7(2):79-108. [13] 2) de Simone G et al. J Am Coll Cardiol. 1992;20:1251-60. [109]
	LV mass/height (g/m) ^{1.7}	Women ≤ 60	Men ≤ 81	Chirinos JA et al. Hypertension. 2010;56:91-98. [15]
	Relative wall thickness (cm)	Women < 0.42	Men < 0.42	1) Lang RM et al. J Am Soc Echocardiogr. 2015;28:1-39.e14. [8] 2) Ganau A et al. J Am Coll Cardiol 1992; 19:1550-1558. [110]
Echo 2D method	LV mass (g)	Women ≤ 150	Men ≤ 200	1) Lang RM et al. J Am Soc Echocardiogr. 2015;28:1-39.e14. [8] 2) Park SH et al. J Am Soc Echocardiogr 1996;9:119-228.[111]
	LV mass/BSA (g/m^2)	Women ≤ 88	Men ≤ 102	Lang RM et al. J Am Soc Echocardiogr. 2015;28:1-39.e14. [8]
	LV mass/height (g/m) ^{2.7}	Women ≤ 47	Men ≤ 50	de Simone G et al. Am J Hypertens 2005;18:191-196. [14]
Echo 3D method	LV mass (g)	Women ≤ 130	Men ≤ 170	Mizukoshi K et al. J Am Soc Echocardiogr. 2016 Jan;29(1):51-61. [112]
	LV mass/BSA (g/m^2)	Women ≤ 80	Men ≤ 88	Mizukoshi K et al. J Am Soc Echocardiogr. 2016 Jan;29(1):51-61. [112]
	LV mass/EDV ratio	Women < 1.23	Men < 1.22	Lembo M et al. J Hypertens. 2018;36:1697-1704. [34]
MRI method	LV mass (g)	Women ≤ 146	Men ≤ 186	Maceira AM et al. J Cardiovasc Magn Reson. 2006; 8:417-426. [113]
	LV mass/BSA (g/m^2)	Women ≤ 77	Men ≤ 93	Maceira AM et al. J Cardiovasc Magn Reson. 2006; 8:417-426. [113]
	LV mass/EDV ratio	Women < 1.0	Men < 1.12	Rider OJ et al. Eur Heart J. 2013;34:292-299. [114]

BSA= body surface area, EDV= end diastolic volume, LV= left ventricular

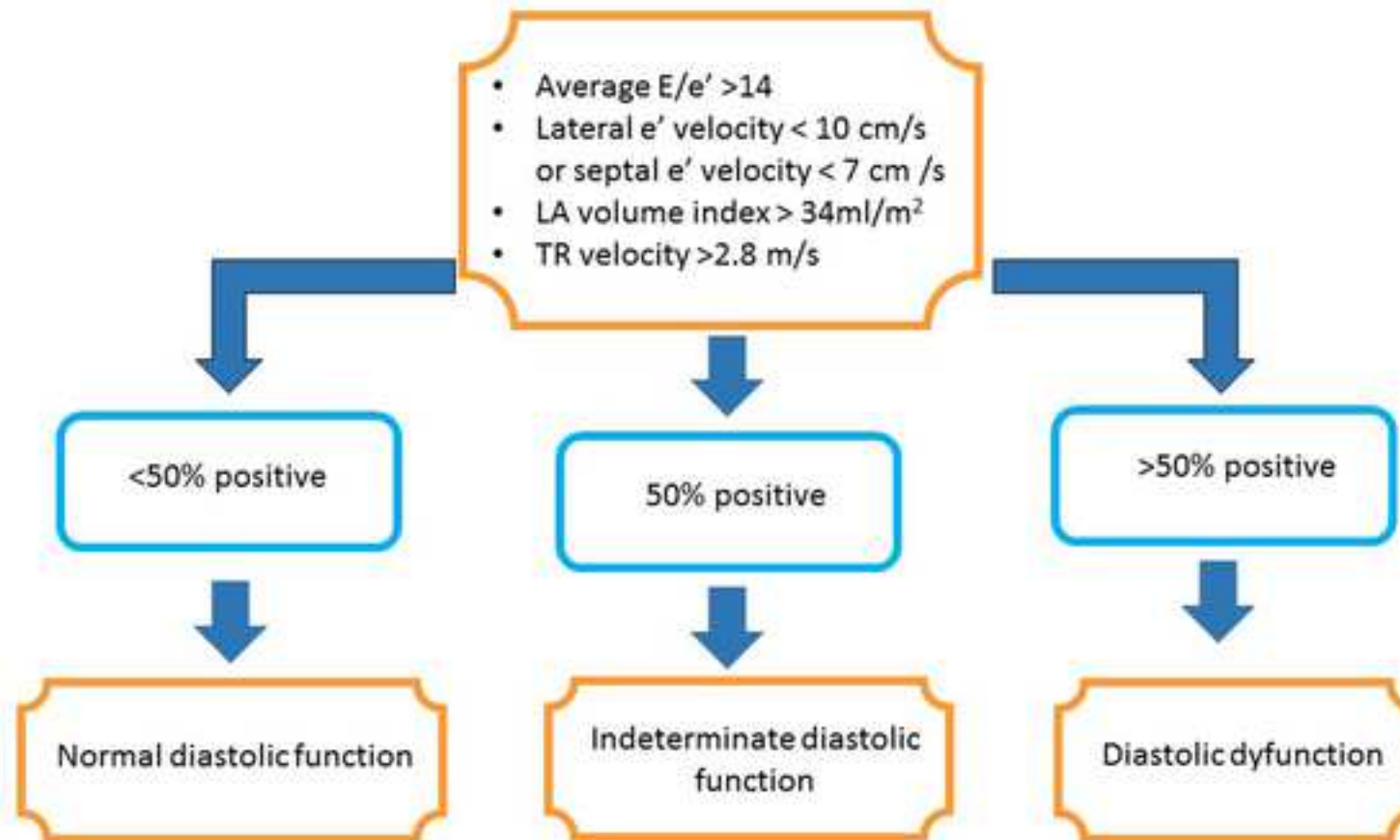
Table 2. Echocardiographic parameters predicting poor prognosis in patients affected by arterial hypertension, their cut-off values of normalcy and references.

Parameter	Thresholds of normalcy	References
LVM	<p>LVM/height^{2.7} (g/m^{2.7}) ≤50 men, ≤47 women</p> <p>LVM/BSA (g/m²) ≤115 men, ≤95 women</p>	<p>1) Levy D et al. N Engl J Med. 1990;322:1561-1566.[7]</p> <p>2) Ghali JK et al. J Am Coll Cardiol. 1998;31:1635-1640. [101]</p> <p>3) Armstrong AC et al. JACC Cardiovasc Imaging 2012;5:837-48.[115]</p> <p>4) de Simone G et al. AM J Hypertens 2005;18: 191-196. [14]</p> <p>5) Krumholz HM et al. J Am Coll Cardiol. 1995;25:879-884.[100]</p> <p>6) Gosse P et al. J Hypertens. 2012;30:2403-2409.[116]</p> <p>7) Verdecchia P et al. J Am Heart Assoc. 2017;6. pii: e005948.[32]</p>
RWT	<0.42	<p>1) Ghali JK et al. J Am CollCardiol. 1998;31:1635-1640.[101]</p> <p>2) Gaasch WH et al. J Am CollCardiol. 2011;58: 1733-1740 [28]</p>
LA size	<p>LA volume index <34 ml/m²</p> <p>LA AP diameter (cm) <4.0 men, <3.8 women</p>	<p>1) Abhayaratna WP et al. J Am CollCardiol. 2006;47:2357-2363. [117]</p> <p>2) Verdecchia P et al. Hypertension 2003; 41:218-223</p> <p>3) Gardin JM et al. Am J Cardiol 2001;87:1051-1057.</p>
Diastolic function	<p>First or second algorithm according to recommendations</p> <p>septal e' ≥7 or lateral e' ≥10 cm/s,</p> <p>average E/e' <14,</p> <p>tricuspid regurgitation systolic jet velocity <2.8 m/s,</p> <p>LA volume index<34 ml/m²</p>	<p>1) Aljaroudi W et al. Circulation 2012;125:782-8. [118]</p> <p>2) Bella JN et al. Circulation 2002;105:1928-33. [119]</p> <p>3) Dini FL et al. Int J Cardiol. 2013;168:3351-3358. [55]</p> <p>4) Oh JK et al. J Am Coll Cardiol. 2006; 47:500-506. [64]</p>

AP = Antero posterior, BSA = Body surface area, LA = Left atrial, LVM = Left ventricular mass, RWT = Relative wall thickness.



**Diastolic function algorithm for hypertensive patients with normal LVEF (> 50%)
and without myocardial disease (e.g., presence of LVH, ischaemic or significant valvular heart disease)**



Diastolic dysfunction algorithm for hypertensive patients with abnormal LVEF (< 50%) or normal LVEF and concomitant myocardial disease (e.g., presence of LVH, ischaemic or significant valvular heart disease)

