

Oral bisphosphonate-induced osteonecrosis complications in patients undergoing tooth extraction: a systematic review and literature updates

M. DIOGUARDI¹, M. DI COSOLA¹, C. COPELLI², S. CANTORE^{3,4}, C. QUARTA¹, G. NITSCH¹, D. SOVERETO¹, F. SPIRITO¹, G.A. CALORO⁵, A.P. CAZZOLLA¹, R. AIUTO⁶, E. CASCARDI^{7,8}, A. GRECO LUCCHINA⁹, L. LO MUZIO¹, A. BALLINI^{1,3}, F. MASTRANGELO¹

¹Department of Clinical and Experimental Medicine, University of Foggia, Foggia, Italy

²Department of Interdisciplinary Medicine, University of Bari "Aldo Moro", Bari, Italy

³Department of Precision Medicine, University of Campania "Luigi Vanvitelli", Naples, Italy

⁴Independent Research, Sorriso & Benessere – Ricerca e Clinica, Bari, Italy

⁵Unità Operativa Nefrologia e Dialisi, Presidio Ospedaliero Scorrano, ASL (Azienda Sanitaria Locale) Scorrano, Lecce, Italy

⁶Department of Biomedical, Surgical, and Dental Science, University of Milan, Milan, Italy

⁷Department of Medical Sciences, University of Turin, Turin, Italy

⁸Pathology Unit, FPO-IRCCS Candiolo Cancer Institute, Candiolo, Turin, Italy

⁹UniCamillus, Saint Camillus International University of Health Sciences, Rome, Italy

Abstract. – OBJECTIVE: Bisphosphonates, the most common anti-resorptive medications, are internalized by osteoclasts, where they inhibit the macrophage colony-stimulating factor (M-CSF) pathway, preventing their differentiation, inhibiting anchorage to the cell membrane, and inducing apoptosis. In patients undergoing oral bisphosphonate therapy, oral surgery involves a high risk of developing drug-related osteonecrosis of the jaws (BRONJ/MRONJ), among the possible complications.

MATERIALS AND METHODS: A systematic search was carried out on the PubMed, Scopus and Cochrane Library search engines, using the keywords "oral bisphosphonates AND tooth extraction", "third molar extraction AND oral bisphosphonates". In addition, we manually evaluated the articles included in references from other sources and an analysis of the Gray Literature was performed. A secondary outcome was to evaluate the assessment of pharmacological (antibiotics) use in the BRONJ/MRONJ management. The revision protocol followed the indications of the Cochrane Handbook, and was registered in the INPLASY database, while the drafting of the manuscript was based on PRISMA.

RESULTS: The results of the systematic review, after the study identification and selection process, included a total of 7 studies: 4 ret-

rospective studies, 2 prospective studies and 1 case report. The main complication was represented by osteonecrosis of the jaws, which appears to be related to the duration of treatment with bisphosphonates; in addition, data regarding the anatomical location of post-extraction sites, the sex and age of patients, comorbidities and various systemic risk factors were extrapolated. The most frequent post-extraction complication in patients treated with oral bisphosphonates is osteonecrosis of the jaws, with a significant prevalence in the posterior region of the mandible. In some cases, delayed healing of the surgical wound was also found; moreover, the duration of exposure to oral bisphosphonates influences the onset of complications.

CONCLUSIONS: Ongoing studies continue to unravel the role of the oral environment response in alveolar bone homeostasis and how it might contribute to the induction of BRONJ/MRONJ. Approaching the problem from this perspective could provide new directions for the prevention of BRONJ/MRONJ and expand our understanding of the unique oral microenvironment.

Key Words:

Oral bisphosphonates, Antibiotics in ONJ, BRONJ, MRONJ, Osteonecrosis.

Introduction

Bisphosphonates (BPs) are synthetic analogues of inorganic pyrophosphate with high affinity for Calcium (Ca²⁺)¹. BPs strong affinity for bone, and not for other tissues, makes them potent inhibitors of bone resorption and bone remodeling activity, with limited potential for side effects in non-skeletal tissues². All BPs compounds, accumulate over long periods of time in the mineralized bone matrix³, modifying in this way bone metabolism, inhibiting osteoclastic activity^{4,5}, and promoting osteoclast apoptosis^{6,7}.

The new BPs generation contains a nitrogenous group constitute, a class of drugs with greater pharmacological strength, varying in efficacy, clinical use, and method of administration, making direct comparison difficult^{1,5}.

The Food and Drug Administration (FDA) has approved⁸⁻¹⁰ the use of Pamidronate and Zoledronate for the treatment of malignant hypercalcemia, multiple myeloma, and for the treatment of patients with bone metastases from solid tumors (i.e., breast, prostate, and lung) along with cancer therapy. Furthermore, the use of oral BPs for patients with Paget's disease and postmenopausal osteoporosis, has proven to be an effective treatment, becoming the first-line drug of medical therapy^{11,12}. It is important to draw attention to a worrying correlation that has emerged in the last years, between osteonecrosis of the jaw bones (ONJ) and the systemic administration of amino BPs¹³. In a 2017 study, Jeong et al¹⁴, citing previous data, from the O'Ryan and Lo¹⁵ study (2012), reported that the overall bisphosphonate-related osteonecrosis of the jaw (BRONJ) rate in patients under BPs therapy was around 0.03-0.1%, taking into account that the incidence rate increased following surgical procedures, such as tooth extraction¹⁵⁻¹⁸.

In 2014, the American Association of Oral and Maxillofacial Surgeons (AAOMS)¹⁹, suggested a nomenclature change from BRONJ to Medication-related osteonecrosis of the jaw (MRONJ), to accommodate the growing number of oral osteonecrosis cases associated with other antiresorptive (denosumab) and antiangiogenic therapies. The exact etiopathology of BRONJ/MRONJ is not well known, but several factors affecting its development have been reported¹. Most cases of BRONJ described in the literature are preceded by "trigger events", and dental extractions and dentoalveolar surgical procedures have been considered as risk factors for the occurrence of BRONJ²⁰.

In the study by Chiu et al²¹, tooth extraction was evaluated as a statistically significant factor for the increased risk of developing ONJ, among osteoporotic patients receiving alendronate, despite the therapy period. Considering the latter discriminating factor, the author found that the risk of developing ONJ in osteoporotic patients undergoing therapy was significantly lower compared to patients undergoing oral BPs therapy for more than three years (24% vs. 92%), highlighting the influence of the duration of the therapy as a risk²¹.

A conservative approach of MRONJ management, based on previous study outcomes^{19,22}, included systemic antibiotics as well as antiseptic therapy with 0.2% chlorhexidine mouthwash and 1% chlorhexidine gel applied to exposed necrotic bone. Furthermore, one aspect on which there is no univocal protocol, is the use of a specific antibiotic therapy administered before the extraction, or in the post-operative period, in patients at MRONJ risk.

It is clear that, in the treatment of MRONJ, perioperative antibiotic therapy is used, as reported by Zirk et al²³, to prevent recurrence and similarly in dentoalveolar surgery performed in patients taking drugs at risk of osteonecrosis. Moreover, there is no uniqueness of treatment as reported and confirmed in a recent systematic review conducted by Azher and Pate²⁴. Preventively administered antibiotic therapy has reduced post-operative complications, but the data²⁴ are still limited to antibiotic use for prophylactic reasons.

Therefore, the aim of the present study was to correlate post-extraction complications in patients receiving oral BPs, with a secondary aim to extract data concerning the use of antibiotics in the preoperative and postoperative management of BRONJ/MRONJ.

Materials and Methods

Protocol and Registration

This systematic review was performed following the guidelines reported in the Cochrane Handbook for Systematic Reviews of Interventions, following the PRISMA Statement (Preferred Reporting Items for Systematic reviews and Meta-Analysis)²⁵⁻²⁸. Moreover, the review protocol was registered on INPLASY (the International Platform of Registered Systematic Review and Meta-analysis Protocols), with registration number INPLASY2022110035 and DOI number 10.37766/inplasy2022.11.0035.

The PICOS questions (Patient, Intervention, Comparison, Outcome and Study design) were: what are the risk factors that influence the onset of post-extraction complications in patients receiving oral BPs? How often do post-extraction complications occur in these patients?

Search Strategy

Between 28 October 2022 and 6 November 2022, a systematic search was conducted in the PubMed, Scopus and Cochrane library databases to identify publications suitable for inclusion in the study, using the following keywords: “oral bisphosphonates AND tooth extraction”, “third molar extraction AND oral bisphosphonates”.

Specifically, the search terms used on PubMed are the following:

Search: (oral bisphosphonates AND tooth extraction) OR (third molar extraction AND oral bisphosphonates);

Sort by:

- 1) Most Recent: ((“mouth”[MeSH Terms] OR “mouth”[All Fields] OR “oral”[All Fields]) AND (“bisphosphonated”[All Fields] OR “bisphosphonic”[All Fields] OR “diphosphonates”[MeSH Terms] OR “diphosphonates”[All Fields] OR “bisphosphonate”[All Fields] OR “bisphosphonates”[All Fields]) AND (“tooth extraction”[MeSH Terms] OR (“tooth”[All Fields] AND “extraction”[All Fields]) OR “tooth extraction”[All Fields])) OR ((“molar, third”[MeSH Terms] OR (“molar”[All Fields] AND “third”[All Fields]) OR “third molar”[All Fields] OR (“third”[All Fields] AND “molar”[All Fields])) AND (“extract”[All Fields] OR “extract s”[All Fields] OR “extractabilities”[All Fields] OR “extractability”[All Fields] OR “extractable”[All Fields] OR “extractables”[All Fields] OR “extractant”[All Fields] OR “extractants”[All Fields] OR “extracted”[All Fields] OR “extractibility”[All Fields] OR “extractible”[All Fields] OR “extracting”[All Fields] OR “extraction”[All Fields] OR “extractions”[All Fields] OR “extractive”[All Fields] OR “extractives”[All Fields] OR “extracts”[All Fields]) AND ((“mouth”[MeSH Terms] OR “mouth”[All Fields] OR “oral”[All Fields]) AND (“bisphosphonated”[All Fields] OR “bisphosphonic”[All Fields] OR “diphosphonates”[MeSH Terms] OR “diphosphonates”[All Fields] OR “bisphosphonate”[All Fields] OR “bisphosphonates”[All Fields]));
- 2) oral: “mouth”[MeSH Terms] OR “mouth”[All Fields] OR “oral”[All Fields] bi-

sphosphonates: “bisphosphonated”[All Fields] OR “bisphosphonic”[All Fields] OR “diphosphonates”[MeSH Terms] OR “diphosphonates”[All Fields] OR “bisphosphonate”[All Fields] OR “bisphosphonates”[All Fields];

3) tooth extraction: “tooth extraction”[MeSH Terms] OR (“tooth”[All Fields] AND “extraction”[All Fields]) OR “tooth extraction”[All Fields]; third molar: “molar, third”[MeSH Terms] OR (“molar”[All Fields] AND “third”[All Fields]) OR “third molar”[All Fields] OR (“third”[All Fields] AND “molar”[All Fields]);

4) extraction: “extract”[All Fields] OR “extract’s”[All Fields] OR “extractabilities”[All Fields] OR “extractability”[All Fields] OR “extractable”[All Fields] OR “extractables”[All Fields] OR “extractant”[All Fields] OR “extractants”[All Fields] OR “extracted”[All Fields] OR “extractibility”[All Fields] OR “extractible”[All Fields] OR “extracting”[All Fields] OR “extraction”[All Fields] OR “extractions”[All Fields] OR “extractive”[All Fields] OR “extractives”[All Fields] OR “extracts”[All Fields];

5) bisphosphonates: “bisphosphonated”[All Fields] OR “bisphosphonic”[All Fields] OR “diphosphonates”[MeSH Terms] OR “diphosphonates”[All Fields] OR “bisphosphonate”[All Fields] OR “bisphosphonates”[All Fields].

The search for publications related to the extraction complications in specific teeth (as in the case of the 3rd molar), did not provide enough data; therefore, to complete this research, we manually evaluated the articles included in the bibliographic references of other sources, selecting the citations considered relevant. In addition, a search was conducted in the Gray Literature sources, specifically on Google Scholar, Science Direct, and OPENGREY.EU - Gray Literature Database (DANS EASY Archive), in order to reduce and minimize Publication Bias. The latest update of the literature was conducted on November 7, 2022.

Eligibility Criteria

The investigation, such as the selection of the studies to be included, was performed independently by 2 reviewers (M.D. and M.D.C.), while 3 reviewers (C.C., S.C., and A.B.) resolved the conflicts or doubts between the 2 reviewers. To assess the suitability of the studies, all publications, titles, and abstracts generated by the

search strategy were consulted. The full text of the articles was retrieved in studies that appeared to meet the screening criteria and in studies in which the title and abstract needed to give more information to decide whether to include the study.

The inclusion and exclusion criteria were decided before the research and selection phase. All studies evaluating complications from oral BPs in patients undergoing tooth extraction were included.

The selected studies were retrospective, prospective, and case reports evaluating ONJ in patients treated with oral BPs, duration of therapy, indication for prescribing BPs, sex and age of patients, co-morbidities and possible therapies, associated pharmacological risk factors, and prevalence of complications.

All articles concerning studies on animal models, articles that do not consider oral BPs, and those that do not provide sufficient data relating to the clinical cases selected were excluded from the search.

Data Charting Process

Data items

For each study, the data relating to the 1st author, the year of publication, the study design, the sex and age of the patients, the number of

post-extraction sites, and the anatomical site of the extraction, the name of the oral BPs used, the period of therapy, any other drugs taken by the patient, the presence of comorbidities and any systemic risk factors, the category of antibiotic administered, the route of administration and the duration of the antibiotic treatment were selected.

The data were extracted and reported in Tables independently by the two reviewers and subsequently compared to reduce the risk of error in reporting the data. The extraction of these data shows the frequency of complications about the variables' distribution.

Results

The studies included were: 7 articles, of which four retrospectives (Yarom et al²⁹, Jeong et al¹⁴, Lain and Ajwani³⁰, Hasegawa et al³¹), two prospective studies (Shudo et al³², Hasegawa et al³³), and a case report (Pan et al³⁴).

The entire procedure of identification, selection and inclusion of the studies is shown in Figure 1 flowchart.

The data extracted from the articles examined were labeled in a descriptive manner in Tables I-VIII. Information about the author,

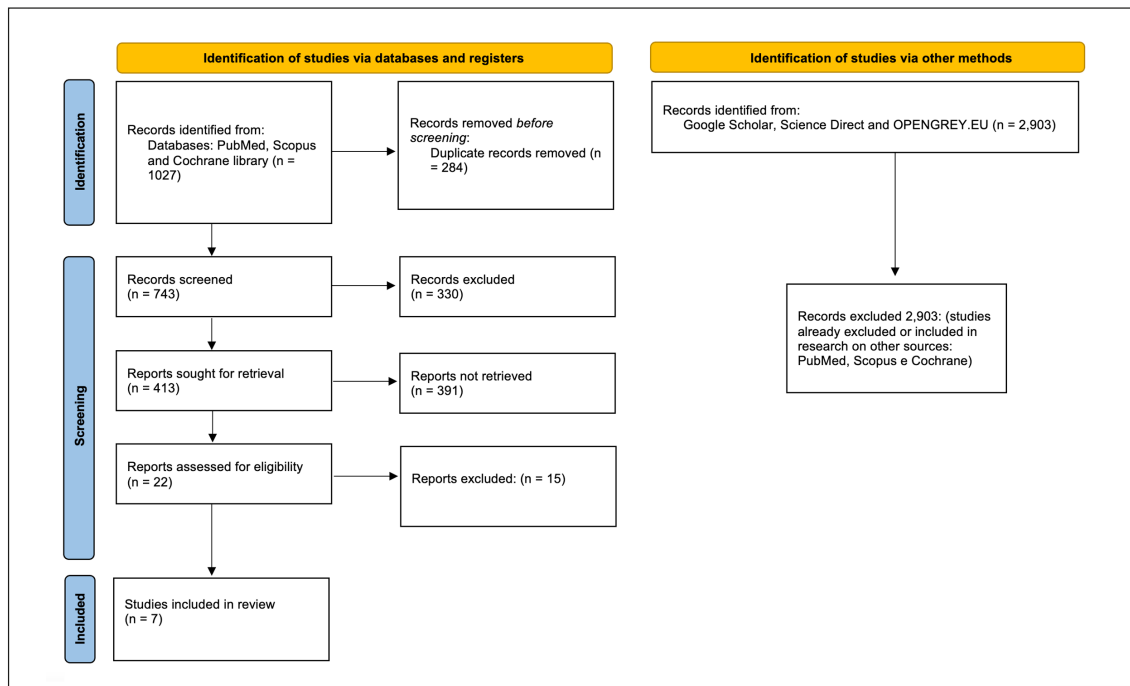


Figure 1. Entire selection and screening procedures are described in the PRISMA flowchart.

Table I. Anatomical region of the extraction sites and frequency of complications in relation to the anatomical region.

First author, year	Type of study	Number of teeth extractions	Anatomical localization	Frequency of complications
Yarom et al ²⁹ 2007	Retrospective	6 teeth 1 implant	Posterior mandible (3) Posterior maxilla (2) Anterior maxilla (1)	ONJ in all cases Delayed healing in all observed groups
Shudo et al ³² 2018	Prospective	274 teeth	Anterior mandible (33) Mandible region premolar and molar (76) Anterior maxilla (64) Maxillary premolar and molar region (101)	
Pan et al ³⁴ 2017	Case report	1 tooth	Mandible molar region	Osteonecrosis following the extraction of the 3 rd lower left molar
Jeong et al ¹⁴ 2017	Retrospective	651 teeth	Anterior mandible (74) Mandible premolar region (67) Mandible molar region (145) Anterior maxilla (94) Maxillary premolar region (84) Maxillary molar region (187)	BRONJ: 2 maxillary premolar region; 1 maxillary molar region; 5 anterior mandible; 2 mandible premolar region; 8 mandible molar region r
Lain and Ajwani ³⁰ 2016	Retrospective	266 teeth	Maxillary (136) Mandible (130) (Anterior region (93) Posterior region (173)	Complications such as delayed healing, bone exposure, infection, pain/swelling, wound breakage, are localized: 13 maxillary, 13 mandible, 5 anterior region, 21 posterior region.
Hasegawa et al ³¹ 2017	Retrospective	2,458 teeth	Mandible (1,218) Maxillary (1,240) Molar region (1,591) Anterior region (1,231)	MRONJ: 14 maxillary, 27 mandible, 36 in the molar region, 5 in the anterior region
Hasegawa et al ³³ 2013	Prospective	434 teeth	Anterior region (155) Premolar region (104) Molar region (175)	Delayed healing in 2 cases: 2 nd maxillary right premolar, 1 st left mandibular molar; BRONJ stage 1 in one case: 2 nd premolar right mandibular

date and publication of the article was reported; all the articles included have a publication date ranging from 2007 to 2018. In addition, different outcomes of particular interest were examined.

Table I shows the data regarding the frequency of complications showed by patients, expressed for each single study, compared to the complication's occurrence site.

On the basis of the available data, it was possible to differentiate the ONJ onset and any other complications between the upper and lower jaw (Table II), as well between the anterior and posterior sites (Table III).

In addition, Table IV was drawn up to compare the incidence of BRONJ and other collateral oral BPs manifestations in patients who have developed post-extraction complications.

Based on the records shown in Table IV, the following data were calculated:

- incidence of complications in the upper and lower jaws;
- incidence of complications in the anterior and posterior regions of the jaws;
- incidence of BRONJ compared to other manifestations in patients who have developed complications.

Table II. Incidence of maxillary and mandibular complications.

First author, year	Number of mandibular tooth extractions	Manifestations of mandibular complications	Incidence of mandibular complications (%)	Number of maxillary tooth extractions	Manifestations of maxillary complications	Incidence of maxillary complications (%)
Shudo et al ³² 2018	109	109 delays in healing	100	165	165 delays in healing	100
Jeong et al ¹⁴ 2017	289	15 BRONJ	5.24	365	3 BRONJ	0.8
Lain and Ajwani ³⁰ 2016	130	13 other complications	10	136	13 other complications	9.55
Hasegawa et al ³¹ 2017	1,218	27 MRONJ	2.17	1,240	14 MRONJ	1.15
Hasegawa et al ³³ 2013	\	\	\	\	\	\

The data were represented as follow: Patients undergoing extraction (N), patients who develop BRONJ (n), patients who develop other complications (n1) (Table IV).

From the articles examined, it emerges that out of a total of 2,095 patients (N), with 47 (n) presenting osteonecrosis, and 29 patient (n1) presenting other types of complications following tooth extraction, as shown in Table IV.

The incidence rate ($n * 100 / N$) of BRONJ in patients taking oral bisphosphonate therapy found

in our review is 2.24%. Assuming that in the examined studies, further complications were also taken into account, in the examined patient's sample size, their incidence ($n1*100/N$) reaches a rate of 1.38%.

The drug used, and the duration of therapy in each study were assessed with respect to the manifestations of complications (Table V).

Data on BPs administration have been extrapolated: Alendronate was administered in 9 cases on 12 patients who developed complications, whose therapy was precisely known.

Table III. Incidence of complications in the anterior and posterior region of both jaws.

First author, data	Number of extractions in the jaw (mandibular, maxillary) anterior regions	Number of complications in the jaw (mandibular, maxillary) anterior regions	Incidence rate of complications in the anterior regions (%)	Number of extractions in the jaw (mandibular, maxillary), posterior regions	Number of complications in the jaw (mandibular, maxillary) posterior regions	Incidence rate of complications in the posterior regions (%)
Shudo et al ³² 2018	97	97	100	177	177	100
Jeong et al ¹⁴ 2017	168	5	2.97	483	13	2.69
Lain and Ajwani ³⁰ 2016	93	5	5.37	173	21	12.13
Hasegawa et al ³¹ 2017	1,231	5	0.4	1,591	36	2.26
Hasegawa et al ³³ 2013	155	0	0	279	3	1.07

Table IV. Incidence of BRONJ and other manifestations among patients who have developed complications.

First author, year	Patients undergoing extraction (N)	Patients who develop BRONJ (n)	Patients who develop other complications (n1)
Shudo et al ¹³² 2018	132	0	0
Jeong et al ¹⁴ 2017	320	11	/
Lain and Ajwani ³⁰ 2016	266	0	26
Hasegawa et al ³¹ 2017	1,175	35	/
Pan et al ³⁴ 2017	1	0	1
Hasegawa et al ³³ 2013	201	1	2
Incidence of BRONJ in patients who have developed post-extraction complications (n* 100/N)		2.24%	
Incidence of other manifestations in patients who developed post-extraction complications (n1* 100/N)		1.38%	

Studies about the specific drug taken by each patient with complications are lacking, not allowing calculation of the drug most often associated with complications.

The data relating to the sex and age of the patients enrolled in the studies are described in detail in Table VI; in the included studies, a sample around 65 years of average age was common.

For each study, data on comorbidities or systemic risk factors (osteoporosis, cardiovascular disease, diabetes, asthma, arrhythmia, rheumatoid arthritis, hypercholesterolemia, glucocorticoid administration, steroid, and immunosuppressive therapy, cancer, smoking) were extracted as shown in Table VII.

Most risk factors affect the inflammatory response and represent an incentive for complications, such as delayed healing, fistulas, and exposed bone, up to the BRONJ diagnosis.

In addition, data were extracted regarding the use of antibiotics to prevent osteonecrosis in patients taking drugs such as BPs, or at risk of ONJ. Table VIII shows the data about only six included studies^{14,29,31-33}, all studies reported using antibiotics pre-operatively and/or after surgery, and only 3 studies^{14,32,33} clearly indicated post-operative therapy.

Discussion

From the analysis of the data extrapolated from the articles selected for this systematic review, it emerges that osteonecrosis of the jaws is the main post-extraction complication in patients being

treated with oral BPs; this medical condition is reported in various studies^{2,13} with different acronyms (ONJ, MRONJ, BRONJ); however, in other cases, a lengthening of the post-extraction site healing times, was found.

In accordance with the examined data, it emerged that in a total of 2,095 patients, 47 osteonecrosis are presented as an event following a dental element extraction. The incidence rate of BRONJ in patients taking therapy with oral BPS is 2.24%, while the incidence of complications other than BRONJ is 1.38%. This amount was estimated by evaluating the ratio between the number of patients (n = 47) who developed BRONJ, and the total number of patients assuming BPs, undergoing tooth extraction (n = 2,095).

The retrospective study of Yarom et al²⁹, was excluded from the study design, not for the nature of the study, but because the sample of patients enrolled was evaluated based on the positivity for ONJ manifestation and not for other outcomes, i.e., patients who were positive for BPs therapy or for other risk factors, such as age or the diagnosis of osteoporosis. Unlike other retrospective studies, in which patients were enrolled based on age (i.e., > or < 60 years), or underwent BPs therapy, the patients risk factors were not excluded²⁹.

The data obtained are quite distant from other data recorded in the literature. In other studies³⁵, the incidence of ONJ after tooth extraction in patients assuming oral BPs is relatively low, around 0.09-0.5%.

Therefore, it is challenging to correctly assess the risk factors for osteonecrosis in patients receiving oral BPs.

Table V. Duration of oral bisphosphonate therapy and frequency of complications in relation to the exposure period.

First author, year	User drug and duration of therapy	Frequency of complications
Yarom et al ²⁹ 2007	Alendronate 1 patient: 4 years 1 patient: 3.5 years 2 patients: 5 years 1 patient: 2 years 1 patient: 1.5 years	In all cases
Shudo et al ³² 2018	Alendronate (59) Risedronate (37) Minodronate (31) Ibandronate (5) average period: 40.4 months	Patients were divided into 4 groups based on the duration of therapy: Group 1: < 2 years (51) Group 2: 2-5 years (41) Group 3: 5-10 years (28) Group 4: > 10 years (12) Delayed healing increases with increasing duration of therapy
Pan et al ³⁴ 2017	Alendronate > 3 years	\
Jeong et al ¹⁴ 2017	Alendronate (161) Ibandronate (20) Risedronate (73) 140 cases for a period < 3 years 113 cases for a period > 3 years	2 cases of BRONJ with duration of therapy < 3 years 9 cases of BRONJ with duration of therapy > 3 years
Lain and Ajwani ³⁰ 2016	Alendronate (203) Risedronate (55) Ethidronate (1) The duration of therapy is not known	\
Hasegawa et al ³¹ 2017	Alendronate (695) Risedronate (304) Minodronate (106) Others (8) Alendronate/risedronate (27) Alendronate/Minodronate (19) Alendronate/others 1 Risedronate/Minodronate 3 Minodronate/others (1) Not specified (11) Average period: 38.5 ± 37.7 (months)	12 cases: more than 4 years of exposure 18 cases: less than 4 years of exposure 11 cases: not known
Hasegawa et al ³³ 2013	Alendronate (123) Risedronate (77) Minodronate (1) Alendronate/risedronate (7) Not known (4) Group with discontinuation of the drug 3 months earlier extraction: 23.6 months (average period of exposure) Group that did not discontinue the drug: 32.6 months (Average period of exposure)	2 cases of delayed healing (drug withdrawal group); 1 case of BRONJ stage 1 (group that did not discontinue the drug)

The most interesting procedural factors to investigate, regarding tooth extraction in osteoporotic patients assuming oral BPs, were the need for drug holiday, as well as the most useful surgical management for wound closure; there

are not enough studies that analyze these factors, therefore, in this systematic review, these points were not been primarily analyzed.

However, it was possible to make some considerations regarding these aspects, to pay attention

Table VI. Gender and age of patients undergoing dental extraction and complications related to sex and age.

First author, year	Gender and age	Frequency of complications
Yarom et al ²⁹ 2007	6 females (63, 79, 74, 67, 76, 66 years)	In all cases
Shudo et al ³² 2018	20 males 112 females 71.9 ± 11.4 years (range 40-94 years)	In all cases
Pan et al ³⁴ 2017	Female 83 years	/
Jeong et al ¹⁴ 2017	298 females 22 males 111 aged < 65 years 209 aged > 65 years	11 cases in female aged > 65 years
Lain and Ajwani ³⁰ 2016	58 males 208 females 73.3 ± 6.9 years	5 males 21 females 8 (60-69 years) 10 (70-79 years) 8 (> 80 years)
Hasegawa et al ³¹ 2017	161 males 1,014 females 70.7 ± 11.7 years (range 23-102 years)	5 males 36 females Average age: 74.8 ± 8.9 (range 51-93)
Hasegawa et al ³³ 2013	18 males 183 females 71.5 ± 9.6 years (range 35-94 years)	2 males (51 and 62 years): delayed healing 1 female (81 years old): BRONJ stage 1

during the extraction procedure. Indeed, some studies^{1,13} have shown that, due to the risk of ONJ in patients undergoing long-term BPs therapy, it is preferable to avoid unnecessary invasive dental procedures. However, dentoalveolar surgery is not contraindicated in osteoporotic patients taking oral BPs.

Moreover, in patients assuming oral BPs therapy for less than four years, and who do not present concomitant risk factors, there is no need to delay oral surgery procedures¹⁹.

In general, a limited periosteal detachment is recommended, especially in high-risk patients¹⁹.

The most innovative approaches to dental tissues and recent BRONJ treatments show a reduction in the incidence and severity of osteonecrosis, but BRONJ can still affect the quality of life and produce substantial comorbidities³⁶.

In fact, several studies^{36,37} have reported that existing infectious conditions, such as periodontitis / periapical lesions and basal bone osteomyelitis, were greater risk factors for the development of BRONJ than for tooth extraction. Additionally, avoiding extraction and maintaining a chronic inflammatory state, can cause BRONJ, so tooth extraction may be required to remove the cause of the inflammation³².

Considering the sex and age of the patients, the studies included in the review show that the population that has major post-extraction complications from oral BPs is mainly composed of women with an average age over 65 years old; this finding is related to the indication for oral BPs for osteoporosis and osteopenia, and underlines the fact that ONJ induced by oral BPs is mainly a concern for the health of post-menopause women. Steroid-induced osteoporosis, which is one of the systemic risk factors considered, is also prevalent in women because the most common autoimmune diseases, such as rheumatoid arthritis and systemic lupus erythematosus, have a strong correlation with the female sex³⁸.

Therefore, as claimed by Jeong et al¹⁴, special attention must be paid to osteoporotic patients treated with oral BPs, aged over 65, who have been in therapy for more than three years, and a follow-up period, with very short intervals of time, is required in case of BRONJ manifestation¹⁴.

The comorbidities of patients with osteonecrosis are generally variable, and some of them cannot be quantified; data from this review show that concomitant malignant diseases, as well as any exposure to chemotherapy, radiotherapy and

Table VII. Comorbidities and risk factors in patients undergoing tooth extraction and complications related to these comorbidities and systemic risk factors.

First author, year	Comorbidities and systemic risk factors	Frequency of complications
Yarom et al ²⁹ 2007	1 patient: hypertension, osteoporosis; 1 patient: diabetes mellitus, asthma, hypertension, hypothyroidism, osteoporosis; 1 patient: hypertension, arrhythmia, hypercholesterolemia, rheumatoid arthritis; 1 patient: hypertension, asthma, osteoporosis; 2 other patients with osteoporosis.	Hyperthyroidism (1) Osteoporosis (5) Diabetes mellitus (1) Asthma (2) Hypertension (4) Arrhythmia (1) Hypercholesterolemia (1)
Shudo et al ³² 2018	Administration of glucocorticoids (55); Diabetes mellitus (28); Rheumatoid Arthritis (23); Systemic Lupus Erythematosus (4); Renal dialysis (3); Osteoporosis (77).	The cases in which there are systemic risk factors and comorbidities are: Group 1: 31 Group 2: 22 Group 3: 16 Group 4: 10
Pan et al ³⁴ 2017	Osteoporosis	\
Jeong et al ¹⁴ 2017	Osteoporosis (320)	Osteoporosis (11)
Lain and Ajwani ³⁰ 2016	Hypertension (139) Diabetes (56) Cardiovascular disease (63) Asthma (35) Osteoporosis (259) Cancer (14) Smoke (27)	In the 26 cases of complications, one or more comorbidities/risk factors are present: Hypertension (15) Diabetes (6) Cardiovascular Disease (7) Cancer (2) Osteoporosis (24) Smoking (4)
Hasegawa et al ³¹ 2017	Osteoporosis (943) Rheumatism (110) Diabetes mellitus (102) Cancer (61) Kidney failure including dialysis (6) Steroid therapy (910) Immunosuppressive therapy (197) Smoking (103)	In the 41 cases of complications, one or more comorbidities/risk factors are present: osteoporosis in 33 cases, cancer in 3 cases, rheumatism in 3 cases, diabetes mellitus in 9 cases; Other factors: 17 cases of steroid therapy, 3 cases of immunosuppressive therapy; smoke in at least one case
Hasegawa et al ³³ 2013	Osteoporosis (148) Hypertension (56) Rheumatism (28) Diabetes mellitus (23) Cancer (20) Angina pectoris (12) Cerebral infarction (11) Myocardial infarction (4) Kidney failure including dialysis (1) Immunosuppressive therapy (16) Steroid therapy (59) Anticancer therapy (20)	Cases of delayed healing: Pemphigus, steroid and immunosuppressive therapy (in one patient); Pemphigus, diabetes mellitus, steroid therapy (another patient); in the case of BRONJ stage 1: osteoporosis.

steroids, have a relevant effect on the complication's prevalence.

In the works of Lain and Ajwani³⁰ in 2016 and Hasegawa et al³¹ in 2017, cases of post-extractive complications in smoking patients were presented; it is known that cigarette smoking negatively

affects wound healing in the oral cavity and could compromise the outcome of different oral surgical procedures^{39,40}. Besides, in combination with long-term BPs therapy, cigarette smoking can develop complications even with simple oral interventions.

Table VIII. The data relating to the administration of antibiotics in patients taking drugs at risk of osteonecrosis are reported; OR (oral), IV (intravenous).

First author, year	Patients	Pre-operative	Post operative
Shudo et al ³² 2018	132	OR: 250 mg amoxicillin or 200 mg clarithromycin; 1 hour before	OR: 1,000 mg Amoxicillin or 400 mg clarithromycin; for up to 2 days
Jeong et al ¹⁴ 2017	320	Antibiotics 1 hour before	Antibiotics for up to 3 days
Hasegawa et al ³³ 2013	201	IV: viccillin, ampicilline-sulbactam, cefmetazole, clindamycin OR: amoxicillin, cefditoren pivoxil, cefcapene pivoxil, azithromycin, clarithromycin, roxithromycin	Antibiotics for up to 12 weeks after extraction (2 patient)
Lain and Ajwani ³⁰ 2016	266	Antibiotic use showed wide variation, with some pre-operative, some post operative and many with no use of antibiotics	
Hasegawa et al ³¹ 2017	1,175	Preoperative antibiotics administration	
Yarom et al ²⁹ 2007	11	MRONJ: therapy consisting of daily doses of amoxicillin (1.5-3 g) or doxycycline (100-200 mg).	

According to the anatomical sites, cases of osteonecrosis mainly occur in the posterior maxillae; in general, the preference for the molar area, and specifically the mandibular molar area is common for all types of BPs, considering their basic mechanism of action⁴¹⁻⁴⁴.

The turnover of the mandibular alveolar bone has a frequency equal to 10 times that of long bones such as the tibia^{45,46}; this explains why bone exposure from BPs begins from the alveolar bone, and perhaps in the molar region, where the chewing loads are greater and create a more active bone turnover with consequent greater vulnerability to drugs that affect the function of osteoclasts for a prolonged period^{38,47}.

BPs bind to hydroxyapatite crystals with high affinity, inhibiting bone resorption and promoting osteoclast apoptosis³⁴. The drugs administered to the patients enrolled in the selected studies, belong to the group of new generation bisphosphonates, containing a nitrogenous group.

The accumulation of BPs in the bone matrix occurs from the beginning of therapy; these drugs remain in the matrix for an extended time, given their very long half-life; in the studies examined, the BPs administered are mainly Alendronate, Risendronate, Minodronate, Ibadronate and Etidronate. On the other hand, intravenous BPs drug therapy represented the criteria for excluding patients from the study.

In any case, Alendronate is the first-choice bisphosphonate: this is sometimes employed alone,

in other cases, in association with Risedronate and Minedronate²².

Interestingly, in the study conducted by Hasegawa et al³³ in 2013, the suspension of therapy is evaluated before oral surgery. The goal of the drug holiday, prior to the oral surgery procedure, was to achieve an improvement in bone remodeling conditions³³. The BPs accumulated in the bone tissue present a half-life of a few years, therefore, the interruption of the bisphosphonate therapy for a few months has a reduced effect on the BPs already deposited in the bone matrix. However, other drug side effects, such as antiangiogenic activity and inhibition of proliferation and migration of epithelial cells, could be significantly reduced, facilitating the healing of the mucosa overlying the post-extraction socket³¹.

In the American Association of Oral and Maxillofacial Surgeons' (AAOMS) Position Paper¹⁵, updated in 2014, it is recommended that oral medications are discontinued at least 2 months prior to an invasive oral procedure in osteoporotic patients undergoing oral BPs therapy, except for individuals who are under therapy for less than 3 years, without other associated risk factors, due to the very low risk of developing ONJ associated with this patients subgroup²¹.

Also, according to Farrugia et al⁴⁸, discontinuation of bisphosphonate therapy should only be considered in special cases, especially if surgery has already been planned, although the benefits of this drug holiday have not been fully evaluated⁴⁸.

The included studies report, with a certain degree of agreement, the use of antibiotic therapy administered pre-operatively in patients taking BPs; the drugs mainly recommended seem to be amoxicillin and claritromycin, administered *per os*, one hour before the oral/maxillofacial surgery (250 mg amoxicillin or 200 mg clarithromycin). In addition, the antibiotic treatment is continued in the postoperative period from 2 to 3 days *via* oral administration³² (Table VIII).

As reported by Lain and Ajwani³⁰ in 2016, the use of antibiotics has presented a considerable diversification; in many studies³⁰, there has not been a precise and clear protocol in the category of antibiotic, its route of administration, and the treatment duration (pre or postoperative). However, it is clear that most of the authors agree that, in the case of post-operative BRONJ/MRONJ complications, the antibiotic therapy should be prolonged up to 3 months until the patient reaches full oral surgery management (bone curettage, sequestrectomies, marginal or segmental resective surgery), in case of exposed bone and osteonecrosis.

An initial pharmacological phase based on antibiotic and antiseptic agents is useful to gradually isolate bone sequestration in BRONJ/MRONJ patients and facilitate a subsequent surgical phase.

The diagnostic and therapeutic aspects are always in constant evolution and updating, as emerges from the AAOMS Position Paper⁴⁹ in 2022 in the field of osteonecrosis of the jaws, and it is important to disseminate this information to all health professionals. This topic should be evaluated in further studies with different designs, according to the evidence-based-dentistry/medicine⁵⁰.

Conclusions

Based on the data investigated in this systematic review, it emerges that osteonecrosis is the most frequent post-extraction complication affecting the jaw bones in patients treated with oral BPs, with a significant prevalence in the mandible posterior region. The most affected subjects' were women over the age of 65 years old, related to the fact that BPs are indicated for the treatment of osteoporosis and osteopenia, mainly in postmenopausal women.

Comorbidities are variable and significant, and together with any exposure to chemotherapy, radiotherapy, and steroids, have a relevant effect on the prevalence of complications.

This summary review was limited to BRONJ/MRONJ and did not involve other forms of osteonecrosis. Ongoing studies continue to unravel the role of the oral immune response in alveolar bone homeostasis and how it might contribute to the induction of BRONJ/MRONJ.

Conflict of Interest

The Authors declare that they have no conflict of interests.

Authors' Contribution

Conceptualization, M.D., S.C., M.D.C. and F.M., a methodology, M.D. C.C., and M.D.C.; software, F.S. A.G.L. and M.D.; validation, F.S., R.A., A.M., and A.B.; formal analysis, M.D., M.D.C., S.C. and C.Q.; investigation, M.D., S.C. and G.A.C.; data curation, M.D., A.P.C. and A.G.L. bibliographic research, G.A.C., M.D.C., and D.S.; writing-original draft preparation, M.D., D.S., G.N. and M.D.C.; writing-review and editing, M.D., S.C. and A.B.; visualization, C.C., E.C., L.L.M.; critical revision of the manuscript for important intellectual content, M.D., M.D.C.; S.C., and A.B.; supervision, M.D.C., L.L.M., S.C., and M.D.; project administration M.D.C., and C.C.; Finally, Mario Dioguardi and Michele Di Cosola equally contributed as co-first authors, Andrea Ballini and Filiberto Mastrangelo, equally contributed as co-last authors. All authors have read and agreed to the published version of the manuscript.

Funding

Not applicable.

Ethics Approval

Not applicable.

Informed Consent

Not applicable.

Data Availability

Not applicable.

ORCID ID

Mario Dioguardi: 0000-0003-0949-3457
Michele Di Cosola: 0000-0002-2756-3212
Chiara Copelli: 0000-0003-2992-893X
Stefania Cantore: 0000-0001-9521-2521
Christian Quarta: 0000-0003-0843-1430
Giulia Nitsch: 0009-0000-1839-9126
Diego Sovereto: 0000-0001-8636-9113
Francesca Spirito: 0000-0002-8364-2425
Giorgia Apollonia Caloro: 0009-0004-2315-0172
Angela Pia Cazzolla: 0000-0003-0842-7351
Riccardo Aiuto: 0000-0001-8116-9614
Eliano Cascardi: 0000-0003-1287-4285
Alberta Greco Lucchina: 0000-0002-1985-4263
Lorenzo Lo Muzio: 0000-0003-4633-4893
Andrea Ballini: 0000-0001-8758-1415
Filiberto Mastrangelo: 0000-0002-3746-5675.

References

- 1) Dioguardi M, Spirito F, Alovisi M, Aiuto R, Garovich D, Crincoli V, Ballini A, Caloro GA, Lo Muzio L. Location and Gender Differences in Osteonecrosis of the Jaws in Patients Treated with Antiresorptive and Antineoplastic Drugs Undergoing Dentoalveolar Surgical, Systematic Review with Meta-Analysis and Trial Sequential Analysis. *J Clin Med* 2023; 12: 3299.
- 2) Goker F, Grecchi E, Grecchi F, Francetti L, Del Fabbro M. Treatment of medication-related osteonecrosis of the jaw (MRONJ). A systematic review. *Eur Rev Med Pharmacol Sci* 2021; 25: 2662-2673.
- 3) Sat Aydin I, Sehitoglu I, Ozer E, Kalkan Y, Tumkaya L, Cure MC, Cure E. High dose zoledronic acid increases ischemia-reperfusion damage of the liver. *Eur Rev Med Pharmacol Sci* 2021; 25: 3567-3575.
- 4) Serra E, Paolantonio M, Spoto G, Mastrangelo F, Tetè S, Dolci M. Bevacizumab-related osteonecrosis of the jaw. *Int J Immunopathol Pharmacol* 2009; 22: 1121-1123.
- 5) Zhurakivska K, Troiano G, Caponio VCA, Dioguardi M, Laino L, Maffione AB, Lo Muzio L. Do Changes in Oral Microbiota Correlate With Plasma Nitrite Response? A Systematic Review. *Front Physiol* 2019; 10: 1029.
- 6) Mori G, Brunetti G, Colucci S, Oranger A, Ciccolella F, Sardone F, Pignataro P, Mori C, Karapanou V, Ballini A, Mastrangelo F, Tete S, Grassi FR, Grano M. Osteoblast apoptosis in periodontal disease: role of TNF-related apoptosis-inducing ligand. *Int J Immunopathol Pharmacol* 2009; 22: 95-103.
- 7) Mori G, Brunetti G, Colucci S, Ciccolella F, Corricciati M, Pignataro P, Oranger A, Ballini A, Farronato D, Mastrangelo F, Tetè S, Grassi FR, Grano M. Alteration of activity and survival of osteoblasts obtained from human periodontitis patients: role of TRAIL. *J Biol Regul Homeost Agents* 2007; 21: 105-14.
- 8) Grassini D, Cascardi E, Sarotto I, Annaratone L, Sapino A, Berrino E, Marchiò C. Unusual Patterns of HER2 Expression in Breast Cancer: Insights and Perspectives. *Pathobiology* 2022; 89: 278-296.
- 9) Di Cosola M, Cazzolla AP, Scivetti M, Testa NF, Lo Muzio L, Favia G, Carrillo de Albornoz A, Bascones A. Rendu-osler-weber syndrome or hereditary hemorrhagic telangiectasia (HHT): Description of two cases and literature review. *Av Odontostomatol* 2005; 21-6: 305-310.
- 10) Cazzato G, Cascardi E, Colagrande A, Belsito V, Lospalluti L, Foti C, Arezzo F, Dellino M, Casatta N, Lupo C, Buongiorno L, Stellacci A, Marrone M, Ingravallo G, Maiorano E, Resta L. PRAME Immunoexpression in 275 Cutaneous Melanocytic Lesions: A Double Institutional Experience. *Diagnostics (Basel)* 2022; 12: 2197.
- 11) Drake WM, Kendler DL, Brown JP. Consensus statement on the modern therapy of Paget's disease of bone from a Western Osteoporosis Alliance symposium. Biannual Foothills Meeting on Osteoporosis, Calgary, Alberta, Canada, September 9-10, 2000. *Clin Ther* 2001; 23: 620-626.
- 12) Limongelli L, Cascardi E, Capodiferro S, Favia G, Corsalini M, Tempesta A, Maiorano E. Multifocal Amelanotic Melanoma of the Hard Palate: A Challenging Case. *Diagnostics (Basel)* 2020; 10: 424.
- 13) Crincoli V, Ballini A, Di Comite M, Tettamanti L, Coscia MF, Mastrangelo F, De Vito D. Microbiological investigation of medication-related osteonecrosis of the jaw: preliminary results. *J Biol Regul Homeost Agents* 2015; 29: 977-983.
- 14) Jeong HG, Hwang JJ, Lee JH, Kim YH, Na JY, Han SS. Risk factors of osteonecrosis of the jaw after tooth extraction in osteoporotic patients on oral bisphosphonates. *Imaging Sci Dent* 2017; 47: 45-50.
- 15) O'Ryan FS, Lo JC. Bisphosphonate-related osteonecrosis of the jaw in patients with oral bisphosphonate exposure: clinical course and outcomes. *J Oral Maxillofac Surg* 2012; 70: 1844-1853.
- 16) Hellstein JW, Marek CL. Bisphosphonate osteonecrosis (bis-phossy jaw): is this phossy jaw of the 21st century? *J Oral Maxillofac Surg* 2005; 63: 682-689.
- 17) Marx RE. Pamidronate (Aredia) and zoledronate (Zometa) induced avascular necrosis of the jaws: a growing epidemic. *J Oral Maxillofac Surg* 2003; 61: 1115-1117.
- 18) Ruggiero SL, Dodson TB, Assael LA, Landesberg R, Marx RE, Mehrotra B. American Association of Oral and Maxillofacial Surgeons position paper on bisphosphonate-related osteonecrosis of the jaws-2009 update. *J Oral Maxillofac Surg* 2009; 67: 2-12.
- 19) Ruggiero SL, Dodson TB, Fantasia J, Goodday R, Aghaloo T, Mehrotra B, O'Ryan F. American Association of Oral and Maxillofacial Surgeons position paper on medication-related osteonecrosis of the jaw-2014 update. *J Oral Maxillofac Surg* 2014; 72: 1938-1956.
- 20) Otto S, Tröltzsch M, Jambrovic V, Panya S, Probst F, Ristow O, Ehrenfeld M, Pautke C. Tooth extraction in patients receiving oral or intravenous bisphosphonate administration: A trigger for BRONJ development? *J Craniomaxillofac Surg* 2015; 43: 847-854.
- 21) Chiu WY, Yang WS, Chien JY, Lee JJ, Tsai KS. The influence of alendronate and tooth extraction on the incidence of osteonecrosis of the jaw among osteoporotic subjects. *PLoS One* 2018; 13: e0196419.
- 22) Schubert M, Klätte I, Linek W, Müller B, Döring K, Eckelt U, Hemprich A, Berger U, Hendricks J. The saxon bisphosphonate register - therapy and prevention of bisphosphonate-related osteonecrosis of the jaws. *Oral Oncology* 2012; 48: 349-354.

- 23) Zirk M, Kreppel M, Buller J, Pristup J, Peters F, Dreiseidler T, Zinser M, Zöller JE. The impact of surgical intervention and antibiotics on MRONJ stage II and III - Retrospective study. *J Cranio-maxillofac Surg* 2017; 45: 1183-1189.
- 24) Azher S, Patel A. Antibiotics in Dentoalveolar Surgery, a Closer Look at Infection, Alveolar Osteitis and Adverse Drug Reaction. *J Oral Maxillofac Surg* 2021; 79: 2203-2214.
- 25) Dioguardi M, Cantore S, Scacco S, Quarta C, Sovereto D, Spirito F, Alovise M, Troiano G, Aiuto R, Garcovich D, Crincoli V, Laino L, Covelli M, Malcangi A, Lo Muzio L, Ballini A, Di Cosola M. From Bench to Bedside in Precision Medicine: Diabetes Mellitus and Peri-Implantitis Clinical Indices with a Short-Term Follow-Up: A Systematic Review and Meta-Analysis. *J Pers Med* 2022; 12: 235.
- 26) Dioguardi M, Spirito F, Sovereto D, Alovise M, Aiuto R, Garcovich D, Crincoli V, Laino L, Cazzolla AP, Caloro GA, Di Cosola M, Ballini A, Lo Muzio L, Troiano G. The Prognostic Role of miR-31 in Head and Neck Squamous Cell Carcinoma: Systematic Review and Meta-Analysis with Trial Sequential Analysis. *Int J Environ Res Public Health* 2022; 19: 5334.
- 27) Dioguardi M, Spirito F, Sovereto D, Alovise M, Troiano G, Aiuto R, Garcovich D, Crincoli V, Laino L, Cazzolla AP, Caloro GA, Di Cosola M, Lo Muzio L. MicroRNA-21 Expression as a Prognostic Biomarker in Oral Cancer: Systematic Review and Meta-Analysis. *Int J Environ Res Public Health* 2022; 19: 3396.
- 28) Dioguardi M, Spirito F, Sovereto D, La Femina L, Campobasso A, Cazzolla AP, Di Cosola M, Zhurakivska K, Cantore S, Ballini A, Lo Muzio L, Troiano G. Biological Prognostic Value of miR-155 for Survival Outcome in Head and Neck Squamous Cell Carcinomas: Systematic Review, Meta-Analysis and Trial Sequential Analysis. *Biology (Basel)* 2022; 11: 651.
- 29) Yarom N, Yahalom R, Shoshani Y, Hamed W, Regev E, Elad S. Osteonecrosis of the jaw induced by orally administered bisphosphonates: incidence, clinical features, predisposing factors and treatment outcome. *Osteoporos Int* 2007; 18: 1363-1370.
- 30) Lain R, Ajwani S. Minor post-extraction complications other than BRONJ in older patients on oral bisphosphonates - a retrospective study. *Gerodontology* 2017; 34: 171-179.
- 31) Hasegawa T, Kawakita A, Ueda N, Funahara R, Tachibana A, Kobayashi M, Kondou E, Takeda D, Kojima Y, Sato S, Yanamoto S, Komatsubara H, Umeda M, Kirita T, Kurita H, Shibuya Y, Komori T; Japanese Study Group of Cooperative Dentistry with Medicine (JCDDM). A multicenter retrospective study of the risk factors associated with medication-related osteonecrosis of the jaw after tooth extraction in patients receiving oral bisphosphonate therapy: can primary wound closure and a drug holiday really prevent MRONJ? *Osteoporos Int* 2017; 28: 2465-2473.
- 32) Shudo A, Kishimoto H, Takaoka K, Noguchi K. Long-term oral bisphosphonates delay healing after tooth extraction: a single institutional prospective study. *Osteoporos Int* 2018; 29: 2315-2321.
- 33) Hasegawa T, Ri S, Umeda M, Komatsubara H, Kobayashi M, Shigeta T, Yoshitomi I, Ikeda H, Shibuya Y, Asahina I, Komori T. The observational study of delayed wound healing after tooth extraction in patients receiving oral bisphosphonate therapy. *J Craniomaxillofac Surg* 2013; 41: 558-563.
- 34) Pan WL, Chen PL, Lin CY, Pan YC, Ju YR, Chan CP, Hsu RW. Strontium ranelate treatment in a postmenopausal woman with osteonecrosis of the jaw after long-term oral bisphosphonate administration: a case report. *Clin Interv Aging* 2017; 12: 1089-1093.
- 35) Mavrokokki T, Cheng A, Stein B, Goss A. Nature and frequency of bisphosphonate-associated osteonecrosis of the jaws in Australia. *J Oral Maxillofac Surg* 2007; 65: 415-423.
- 36) Saia G, Blandamura S, Bettini G, Tronchet A, Totola A, Bedogni G, Ferronato G, Nocini PF, Bedogni A. Occurrence of bisphosphonate-related osteonecrosis of the jaw after surgical tooth extraction. *J Oral Maxillofac Surg* 2010; 68: 797-804.
- 37) Yamazaki T, Yamori M, Ishizaki T, Asai K, Goto K, Takahashi K, Nakayama T, Bessho K. Increased incidence of osteonecrosis of the jaw after tooth extraction in patients treated with bisphosphonates: a cohort study. *Int J Oral Maxillofac Surg* 2012; 41: 1397-1403.
- 38) Marx RE, Cillo JE Jr, Ulloa JJ. Oral bisphosphonate-induced osteonecrosis: risk factors, prediction of risk using serum CTX testing, prevention, and treatment. *J Oral Maxillofac Surg* 2007; 65: 2397-2410.
- 39) Levin L, Herzberg R, Dolev E, Schwartz-Arad D. Smoking and complications of onlay bone grafts and sinus lift operations. *Int J Oral Maxillofac Implants* 2004; 19: 369-373.
- 40) Laino L, Troiano G, Dioguardi M, Perillo L, Laino G, Lo Muzio L, Cicciù M. Patient Discomfort During and After Surgically Assisted Rapid Maxillary Expansion Under Local Anaesthesia. *J Craniofac Surg* 2016; 27: 772-775.
- 41) Rogers MJ, Gordon S, Benford HL, Coxon FP, Luckman SP, Monkkonen J, Frith JC. Cellular and molecular mechanisms of action of bisphosphonates. *Cancer* 2000; 88: 2961-2978.
- 42) Odvina CV, Zerwekh JE, Rao DS, Maalouf N, Gottschalk FA, Pak CY. Severely suppressed bone turnover: a potential complication of alendronate therapy. *J Clin Endocrinol Metab* 2005; 90: 1294-1301.
- 43) Calabrese L, Nocini R, Spirito F, Gazzini L, Dallari V, Girolami I, Lo Muzio L. The role of the depth of invasion (DOI) in minor salivary glands tu-

- mors according to the 8th TNM classification: Pitfalls and potential misinterpretations. *Oral Oncol* 2022; 126: 105751.
- 44) Amato A, Iandolo A, Scelza G, Spirito F, Martina S. COVID-19: The Patients' Perceived Impact on Dental Care. *Eur J Dent* 2022; 16: 333-338.
- 45) Wang QR, Yang ZY, Zhang WL, Li QH, Kang PD. Abnormal hyperplasia of chondrocytes in a rat model of glucocorticoid-induced osteonecrosis of the femoral head. *Eur Rev Med Pharmacol Sci* 2022; 26: 6536-6549.
- 46) Pisacane A, Cascardi E, Berrino E, Polidori A, Sarotto I, Casorzo L, Panero M, Boccaccio C, Verginelli F, Benvenuti S, Dellino M, Comoglio P, Montemurro F, Geuna E, Marchiò C, Sapino A. Real-world histopathological approach to malignancy of undefined primary origin (MUO) to diagnose cancers of unknown primary (CUPs). *Virchows Arch* 2023; 482: 463-475.
- 47) Mascitti M, Togni L, Troiano G, Caponio VCA, Sabatucci A, Balercia A, Rubini C, Lo Muzio L, Santarelli A. Odontogenic tumours: a 25-year epidemiological study in the Marche region of Italy. *Eur Arch Otorhinolaryngol* 2020; 277: 527-538.
- 48) Farrugia MC, Summerlin DJ, Krowiak E, Huntley T, Freeman S, Borrowdale R, Tomich C. Osteonecrosis of the mandible or maxilla associated with the use of new generation bisphosphonates. *Laryngoscope* 2006; 116: 115-120.
- 49) Ruggiero SL, Dodson TB, Aghaloo T, Carlson ER, Ward BB, Kademani D. American Association of Oral and Maxillofacial Surgeons' Position Paper on Medication-Related Osteonecrosis of the Jaws-2022 Update. *J Oral Maxillofac Surg* 2022; 80: 920-943.
- 50) Ballini A, Capodiferro S, Toia M, Cantore S, Favia G, De Frenza G, Grassi FR. Evidence-based dentistry: what's new? *Int J Med Sci* 2007; 4: 174-178.