

## REVIEW

## Isolated Cervical Dystonia: Diagnosis and Classification

Alberto Albanese, MD,<sup>1\*</sup> Kailash P. Bhatia, MD,<sup>2</sup> Francisco Cardoso, MD, PhD,<sup>3</sup> Cynthia Comella, MD,<sup>4</sup> Giovanni Defazio, MD,<sup>5</sup> Victor S.C. Fung, MD,<sup>6,7</sup> Mark Hallett, MD,<sup>8</sup> Joseph Jankovic, MD,<sup>9</sup> Hyder A. Jinnah, MD,<sup>10</sup> Ryuji Kajii, MD,<sup>11</sup> Joachim K. Krauss, MD,<sup>12</sup> Anthony Lang, MD,<sup>13</sup> Eng King Tan, MD,<sup>14</sup> Marina A.J. Tijssen, MD, PhD,<sup>15</sup> and Marie Vidailhet, MD<sup>16,17</sup>

<sup>1</sup>Department of Neurology, IRCCS Humanitas Research Hospital, Rozzano, Italy

<sup>2</sup>Department of Clinical and Movement Neurosciences, UCL, Queen Square, Institute of Neurology, University College London, London, UK

<sup>3</sup>Movement Disorders Unit Hospital das Clínicas, Federal University of Minas Gerais, Belo Horizonte, Brazil

<sup>4</sup>Department of Neurological Sciences, Rush University Medical Center, Chicago, Illinois, USA

<sup>5</sup>Department of Translational Biomedicine and Neuroscience, University of Bari, Bari, Italy

<sup>6</sup>Sydney Medical School, Faculty of Medicine and Health, University of Sydney, Sydney, Australia

<sup>7</sup>Movement Disorders Unit, Neurology Department, Westmead Hospital, Westmead, Australia

<sup>8</sup>National Institute of Neurological Disorders and Stroke, National Institutes of Health, Bethesda, Maryland, USA

<sup>9</sup>Parkinson's Disease Center and Movement Disorders Clinic, Department of Neurology, Baylor College of Medicine, Houston, Texas, USA

<sup>10</sup>Departments of Neurology, Human Genetics, and Pediatrics, Emory University School of Medicine, Atlanta, Georgia, USA

<sup>11</sup>Department of Neurology, National Hospital Organization Utano National Hospital, Kyoto, Japan

<sup>12</sup>Department of Neurosurgery, Medical School Hannover, Hannover, Germany

<sup>13</sup>Edmond J. Safra Program in Parkinson's Disease, Toronto Western Hospital, University of Toronto, Toronto, Canada

<sup>14</sup>Department of Neurology, National Neuroscience Institute, Singapore General Hospital, Singapore, Singapore

<sup>15</sup>Expertise Center Movement Disorders Groningen, Department of Neurology, University Medical Center Groningen, University of Groningen, Groningen, The Netherlands

<sup>16</sup>Department of Neurology, Sorbonne Université, Paris, France

<sup>17</sup>Institut du Cerveau et de la Moelle épinière-Inserm U1127, Groupe Hospitalier Pitié-Salpêtrière, Paris, France

**ABSTRACT:** This document presents a consensus on the diagnosis and classification of isolated cervical dystonia (iCD) with a review of proposed terminology. The International Parkinson and Movement Disorder Society Dystonia Study Group convened a panel of experts to review the main clinical and diagnostic issues related to iCD and to arrive at a consensus on diagnostic criteria and classification. These criteria are intended for use in clinical research, but also may be used to guide clinical practice. The benchmark is expert clinical observation and evaluation. The criteria aim to systematize the use of terminology as well as the diagnostic process, to make it reproducible across centers and applicable by expert and non-expert clinicians.

Although motor abnormalities remain central, increasing recognition has been given to nonmotor manifestations, which are incorporated into the current criteria. Three iCD presentations are described in some detail: idiopathic (focal or segmental) iCD, genetic iCD, and acquired iCD. The relationship between iCD and isolated head tremor is also reviewed. Recognition of idiopathic iCD has two levels of certainty, definite or probable, supported by specific diagnostic criteria. Although a probable diagnosis is appropriate for clinical practice, a higher diagnostic level may be required for specific research studies. The consensus retains elements proven valuable in previous criteria and omits aspects that are no longer justified, thereby

This is an open access article under the terms of the [Creative Commons Attribution-NonCommercial-NoDerivs](#) License, which permits use and distribution in any medium, provided the original work is properly cited, the use is non-commercial and no modifications or adaptations are made.

\*Correspondence to: Dr. Alberto Albanese, Department of Neurology, IRCCS Humanitas Research Hospital, Rozzano, 20089, Milan, Italy; E-mail: [alberto.albanese@unicatt.it](mailto:alberto.albanese@unicatt.it)

**Relevant conflicts of interest/financial disclosures:** There are no conflicts of interest related to this research activity.

**Funding:** This work was supported by the Italian Ministry of Health (RF-2019-12369919).

**Received:** 20 December 2022; **Revised:** 25 February 2023; **Accepted:** 7 March 2023

**Published online 29 March 2023 in Wiley Online Library** ([wileyonlinelibrary.com](http://wileyonlinelibrary.com)). DOI: 10.1002/mds.29387

encapsulating diagnosis according to current knowledge. As understanding of iCD expands, these criteria will need continuous revision to accommodate new advances. © 2023 The Authors. *Movement Disorders*

published by Wiley Periodicals LLC on behalf of International Parkinson and Movement Disorder Society.

**Key Words:** classification; diagnosis; Dystonia

## Introduction

Prevalence studies have shown that the cervical region is more frequently affected by dystonia compared to other body areas, such as the eyes or the upper limbs.<sup>1</sup> According to current terminology, dystonia is called isolated when it is the only motor feature (except for tremor) and called combined when it occurs with other movement disorders (such as myoclonus, parkinsonism, etc.)<sup>2</sup> Dystonia affecting the cervical region is often isolated. The peculiar motor features and body topography of isolated cervical dystonia (iCD) have been recognized since the early descriptions,<sup>3,4</sup> and the terminology used to describe it has evolved over time, with terms such as torticollis historically being used synonymously with iCD.<sup>5,6</sup> Despite being the most common dystonia type observed in movement disorders clinics, definition and diagnostic criteria for iCD are still lacking.

In 2013, a group of experts provided a consensus statement with recommendations for the diagnosis and classification for all dystonia types.<sup>2</sup> These recommendations have been widely adopted and successfully applied.<sup>7</sup> However, a recent analysis found that the delineation of iCD is not fully accounted for by the previously proposed general dystonia consensus.<sup>8,9</sup> In addition, the relationship between tremor and dystonia is particularly relevant for iCD patients, as approximately a half of them have head, neck, or upper limb tremor.<sup>10</sup> Currently, there is no test to definitively diagnose iCD, and the gold standard is a clinical diagnosis based on history, clinical features, and phenomenology. Studies on iCD have often relied on clinicians' experience to identify diagnostic features, but differences of opinion have emerged, even among experts, particularly if features are subtle or less severe.<sup>11-13</sup> The International Parkinson and Movement Disorder Society's Dystonia Study Group convened a consensus panel to characterize the clinical features of iCD, review terminology, and suggest internationally agreed diagnostic criteria.

## Methodology

An International Consensus Committee, consisting of investigators with years of experience in dystonia, was formed to review the literature on iCD and provide a consensus on classification, terminology, and features relevant for diagnosis of iCD.

Considering that PubMed MeSH terms list "torticollis" instead of "cervical dystonia", computerized PubMed searches were conducted using the MeSH heading "torticollis", and a combination of the title word "cervical" with the MeSH heading "dystonia". The two searches were limited to human studies and included publications until October 2022; the resulting publication lists were merged. The reference lists of all known primary articles were searched for additional, relevant citations. No language restrictions were applied. Four online meetings and numerous mail exchanges were organized between October 2021 and April 2022 to discuss three structured rounds of questions (see Supporting Data). The meetings used a consensus development panel methodology to reach agreement.<sup>14</sup> A first draft of the manuscript was prepared based on the results of the literature review, data analysis, discussion, and comments from the committee members. The document was progressively refined until a final consensus was reached.

## Results

Search of "Torticollis"[mh] retrieved 3913 publications; search of "Dystonia"[mh] AND "cervical"[ti] yielded 1053 publications. The merged list encompassed 4058 titles (86% already detected by the first search), indicating that MeSH heading "Torticollis" accounts for most publications on cervical dystonia.

### Clinical Features

iCD refers to dystonia affecting the cervical (neck) region and occurring in isolation, without other neurological abnormalities.<sup>2</sup> iCD is the most common form of adult-onset dystonia coming to medical attention, with a recent estimated incidence of ~1.18 per 100,000 person-years<sup>15</sup> and a prevalence of at least 30 cases per million.<sup>16</sup> This condition influences daily functioning in the working and familial environments.<sup>17</sup> Table 1 summarizes the abnormal head and neck postures that have been described in iCD patients. The terms torticollis, or spasmodic torticollis, are older, currently inaccurate, expressions used to describe iCD,<sup>5,6</sup> as well as to other conditions associated with abnormal head posturing. Particularly in children, the term torticollis is used in association with a myriad of conditions that range from benign to fatal, such as torticollis caused by positional plagiocephaly, gastroesophageal reflux, brain neoplasms, and retropharyngeal abscesses. Most of these

**TABLE 1** Terminology used to describe abnormal cervical positions in iCD

Traditional terms	Col-cap terms <sup>a</sup>	Description
Torticollis <sup>b</sup>	Torticaput	Rotation to the right or left
Anterocollis	Anterocaput	Forward flexion
Retrocollis	Retrocaput	Backward extension
Laterocollis	Laterocaput	Lateral tilt
Lateral shift		Base of the neck shifted over toward one shoulder
Anterior or posterior shift		Base of the neck shifted forward or backward

<sup>a</sup>These terms were introduced to indicate that fulcrum of the abnormal posture is in the upper cervical spine.<sup>18</sup>

<sup>b</sup>The term torticollis is currently used in pediatric neurology to indicate a common finding in children that is associated to many conditions that are considered cervical dystonia mimics (Table 2).

Abbreviation: iCD, isolated cervical dystonia.

conditions are listed among cervical dystonia mimics (Table 2).

The phenomenology of iCD can vary from patient to patient, with each displaying a relatively characteristic individual motor pattern. Patients with more severe symptoms are generally unable to fully control head position at will. Some patients may have limited or no postural abnormalities and present only a head tremor, whereas at the other extreme of the spectrum there are patients with prominent abnormal postures and few mobile components. Head or neck tremor can be irregular and jerky, with individual movements occasionally so fast as to have been historically called “myoclonic”, but are now considered within the spectrum of cervical dystonia phenomenology.<sup>19</sup> The mobile component of iCD may raise uncertainty whether dystonia is isolated or combined with another movement disorder, particularly with a non-dystonic tremor disorder (eg, essential tremor [ET]), myoclonus or tics.<sup>20-23</sup> The varied motor phenomenology of iCD has not been consistently organized into distinct motor subtypes.

The term iCD refers to the involvement of cervical muscles, but shoulder muscles may also be involved resulting in abnormal head, neck, shoulder movements, and postures. The term iCD, however, does not apply to shoulder involvement without a cervical component. The expression “focal iCD” indicates that the condition affects the cervical region and variably involves the head, neck, and shoulders, but no other body regions. Furthermore, cervical involvement has also been described in patients with segmental, multifocal, or generalized dystonia where additional body regions are affected: in one study of 1258 patients with cervical

dystonia, 28.3% had dystonia outside of the neck region.<sup>8</sup> Distinguishing the focal and segmental forms from cervical involvement associated with more widespread dystonia is a relevant clinical need, particularly when performing clinical trials.

Besides a characteristic phenomenology, iCD frequently displays two specific clinical features that are instrumental for diagnostic purposes: alleviating maneuvers (sensory trick, also called geste antagoniste) and pain or discomfort involving the neck and shoulders.

1. Alleviating maneuvers occur in up to 90% of iCD patients.<sup>24</sup> They usually consist of touching the face with fingertips to temporary ameliorate the dystonic posture or to reduce the abnormal movements and associated discomfort.<sup>25</sup> A slight touch of the chin, cheek, or neck is usually sufficient to relieve symptoms.<sup>26</sup> Sometimes, mere imagination of the gesture without touching the face, head or neck are described as useful to alleviate the symptoms of iCD.<sup>27</sup> The diagnostic relevance of alleviating maneuvers has been recognized, but their specific sensitivity and specificity are not known.<sup>28</sup> Although observed in almost 90% of iCD patients, alleviating maneuvers are effective in ~40%<sup>24</sup> and their effectiveness may diminish with time. The phenomenology of these maneuvers is variable, but consistent in each individual patient. A common phenomenon consists of placement of a finger on the chin or hand in the occipital area of the head<sup>12</sup>; others include touching the lower face or the posterior neck, and, less commonly, the upper face.<sup>24</sup> Another maneuver involves raising the arms without touching the head.<sup>29</sup> Actual pushing of the head into position is typically not needed, but when this is the case, it has been called a “forcible trick”.<sup>27</sup>

2. Pain is also a frequent and distinctive feature of iCD not usually present in other focal or even generalized dystonia types, affecting 67% to 75% of iCD patients<sup>30-33</sup> and significantly influencing their quality of life.<sup>34</sup> Pain does not always correlate with motor symptomatology or changes in posture.<sup>31</sup> It is mostly perceived in the neck and shoulders (68% of patients), but may spread to the upper back region with some radiations directed up to the head on the bent side and down to the ipsilateral upper limb.<sup>31,35</sup> Cervical pain responds efficiently to botulinum neurotoxin treatments and is often an early symptom to reappear following treatment cycles.<sup>36</sup> The mechanism of pain in iCD is considered to be in part related to muscle overactivity and partly caused by non-muscle related mechanisms, such as abnormal transmission and processing of nociceptive stimuli, dysfunction of descending pain inhibitory pathways as well as structural central network changes.<sup>36</sup> The diagnostic value, sensitivity and specificity of iCD-associated pain have not been assessed. Sensitivity is negatively influenced by the observation that that neck and shoulder pain is reported by some

**TABLE 2** List of common cervical dystonia mimics

Condition	Description
Congenital muscular torticollis	This disorder is characterized by abnormal head postures in newborns or young children, often caused by abnormal shortening and fibrosis of specific neck muscles. The most common presentation involves the sternocleidomastoid with ipsilateral head tilt and contralateral rotation of the chin. It presents in newborn infants or young children with reported incidence ranging from 0.3% to 2%.
Benign paroxysmal torticollis	Benign paroxysmal torticollis has been described as a self-limiting under-diagnosed condition of infancy. It is characterized by periods of unusual, sustained posture of the head and neck, during which the head tilts to one side. Episodes are often accompanied by marked autonomic features, irritability, ataxia, apathy, and drowsiness. These episodes last several hours to a few days and are often recurring every few weeks. They subside within the pre-school years, but during later childhood a tendency to develop migraine has been reported. The main difference with iCD is the paroxysmal nature of this disorder.
Atlanto-axial subluxation	This is a rare and potentially fatal disturbance to the normal occipital-cervical anatomy that is usually asymptomatic, but may cause vague neck pain, occipital headache, or occasionally intermittent (and potentially fatal) cervical spinal cord compression. It may cause permanent neurologic deficits or sagittal deformity if not treated in a timely and appropriate manner. Atlantoaxial subluxation can result from major trauma or can occur without trauma in patients with rheumatoid arthritis, juvenile idiopathic arthritis, or ankylosing spondylitis (Grisel's syndrome). The rotatory subluxation is associated with a specific posture that should be mentioned: tilt and turn ("robin listening to the ground for the worm")
Cervical tics	Motor tics involving the neck can have a dystonia-like appearance (dystonic tics). If severe, tics can be complicated by cervical myelopathy, particularly when they cause repetitive neck flexion-extension.
Neck sprain	Neck sprain may occur as a result of trauma, such as a whiplash incident, a fall, or even sudden twisting movement of the spine. A sprain affects ligaments, which are forced beyond normal limits. This can happen all at once, as in a whiplash event resulting from a rear-end car accident, or slowly over time as a result of poor posture especially while sitting.
Sandifer's syndrome	This is rare paroxysmal movement of the back and neck that is often associated with gastroesophageal reflux in children. Often there is exacerbation of the abnormal posturing immediately after eating and improvement in between feeds. Some parents describe intermittent episodes of torticollis that change from one side to another with feeds. The sternocleidomastoid muscle is normal.
Functional (psychogenic) dystonia	Functional dystonia can present a varied phenomenology, including head tremor and head or neck posturing. Often this is associated with fixed postures but repetitive movements that are atypical for iCD also may be seen.
Compensation in fourth cranial nerve palsy	Diseases or injuries to the fourth cranial nerve can cause a paralysis of the superior oblique muscle that turns the eye inward and downward. Consequently, the images from both eyes appear one above the other, or above and to the side of the other. The patients spontaneously hold the head at a tilt to compensate for double or blurred vision.
Compensation in hemianopia	Patients with homonymous hemianopia tend to compensate and adapt to visual field loss by turning the head and eyes to keep visual targets within the residual visual field.
Compensation in nystagmus	Patients with nystagmus may have head shaking, particularly when attentive, that can be phase-locked to the nystagmus with resemblances in wave form and direction.
Spasmus nutans	This is a rare, usually benign, condition in infants and young children characterized by nystagmus with high frequency and small amplitude. Compensatory head nodding and rotation are typically associated.
Oculomotor apraxia	This is a defect in the ability to perform voluntary eye movements. Patients are unable to willingly draw their eyes to an object that grabs their attention but can otherwise freely gaze left and right. When their attention is drawn, these patients exhibit head thrusting or shaking to bring the object into their gaze.
Bezold's abscess	This is a rare deep neck abscess and is an intratemporal complication of a coalescent mastoiditis via direct extension into the perimastoid tissues. Neck pain and stiffness may resemble iCD, although fever, swelling, otalgia and hearing loss represent specific features.

Note: Some of these descriptions have historical value and are reported here for the sake of completeness using the most widely accepted terminology/definitions. Abbreviation: iCD, isolated cervical dystonia.

patients with tic disorders with strong cervical tics (eg, dystonic tics).<sup>37</sup> Specificity is negatively influenced by the observation that a proportion of patients are pain-free, even with dystonic movements of similar severity and duration to those of patients with pain.<sup>36</sup>

Furthermore, patients with a variety of longstanding abnormal movements involving the neck may also experience osteoarticular sources of pain.

Besides pain, other non-motor manifestations of iCD include anxiety, depression, and perception of social

stigmatization.<sup>38-41</sup> Sleep disturbances reported in patients with iCD may be because of the involuntary head and neck movement, pain, or co-morbid depression.<sup>41,42</sup>

### Pathophysiology

The pathophysiology of iCD, like other adult-onset focal dystonias, is characterized by loss of inhibition of brain circuits at brainstem and cortical levels.<sup>43,44</sup> Abnormalities of multiple neurotransmitter systems including GABA, dopamine, and acetylcholine have been identified.<sup>45-47</sup> The involuntary movement is a product of a resultant network dysfunction involving brainstem, basal ganglia, cerebellum, and cortex.<sup>48-50</sup>

Compared to other dystonia types, involuntary head and neck movements additionally involve control of gaze, vestibular function, and visuospatial integration.<sup>51,52</sup> The abnormal head positions may result from dysfunction of a brainstem integrator.<sup>53</sup> The interesting feature of alleviating maneuver may involve normalization of the network involving the supplementary motor area.<sup>54</sup>

### Progression

Symptom spread occurs in fewer patients with isolated iCD compared to other focal dystonia types.<sup>55-57</sup> In general, iCD has focal or segmental distribution.<sup>58</sup> In a large cohort, it was reported that spread to other body regions occurred in only 8.4% of patients presenting with focal iCD within the first 3.5 years from onset.<sup>57</sup> The most involved extra-cervical regions were the upper limbs, with hand involvement in 46% of cases and upper arm involvement in 25%. Upper limb tremor occurs in >15% of patients with iCD,<sup>58</sup> raising the question on the classification of patients who have prominent iCD associated with mild upper limb features. iCD may spread to contiguous body parts or less commonly begins as a component of segmental dystonia or develops after dystonia has emerged in another body part.<sup>58</sup> A review of 1477 cases collected by the Dystonia Coalition showed that the site of dystonia was the neck in 78.5%; in 13.3% of patients there was focal onset elsewhere with later segmental spread to neck, and in 8.2% there was segmental onset with initial neck involvement.<sup>58</sup> Extra-cervical involvement is not always appreciated, as 28.3% of subjects given a diagnosis of focal iCD had dystonia outside of the neck region.<sup>8</sup> Patients with iCD with associated head tremor are more likely to have a segmental distribution (with frequent arm involvement), associated arm tremor and a positive family history, suggesting a genetic etiology in this subgroup of patients.<sup>59,60</sup>

The natural course of iCD has not been well characterized by prospective longitudinal studies, although many experts agree that the symptoms usually progress

in the first 5 to 10 years, after which it remains relatively stable.<sup>61,62</sup> However, in some patients who initially fulfil criteria for iCD the condition evolves to involve other body regions,<sup>57</sup> particularly when iCD is inherited or there is head tremor. Some patients presenting as isolated iCD may evolve to develop a segmental or generalized distribution, or become combined with additional movement disorders, such as myoclonus or ataxia. Observation of large cohorts has shown that focal and segmental involvement is by far more common than multifocal or generalized.<sup>8,58</sup> Therefore, the term iCD is reserved here for cases with focal or segmental body distribution.

### Diagnosis of iCD

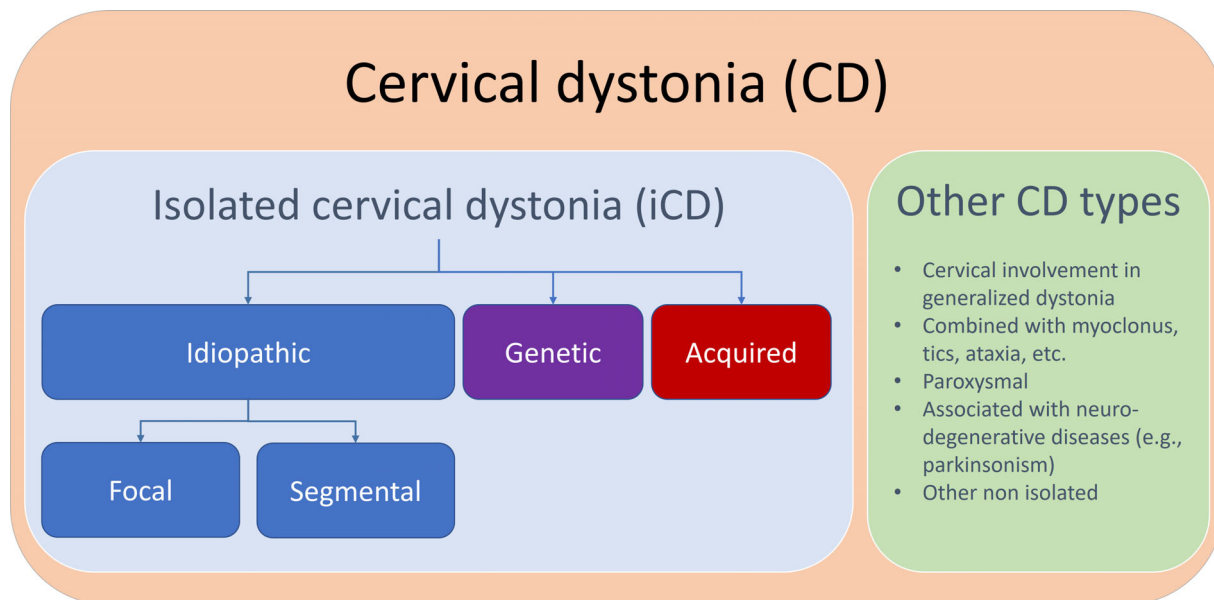
Since its original descriptions, the clinical diagnosis of cervical dystonia has centered on a defined motor syndrome. The centrality of the motor syndrome remains the core feature by which cervical dystonia is clinically defined. The panel agreed on the following general definition of cervical dystonia.

Cervical dystonia is characterized by sustained or intermittent neck movements caused by involuntary muscle contractions, resulting in abnormal movements and postures of head, neck, and/or shoulders. Movements are often patterned and tremor may be present.

This definition recognizes that the observation of dystonic postural abnormalities in combination with faster mobile components is instrumental for the recognition of dystonia.<sup>63</sup> Table 2 lists a few cervical dystonia mimics that are considered outside this diagnostic spectrum.

iCD is a specific presentation of cervical dystonia (Fig. 1). The diagnosis of iCD requires fulfilling phenomenological criteria based on the general definition supported by the presence of alleviating maneuvers as well as pain. Sensitivity and specificity of these criteria have not been assessed yet. Until definitive validated diagnostic markers are available, clinical expert opinion remains the gold standard for the diagnosis of iCD.

Diagnosis of iCD further requires that dystonia is not accompanied by other movement disorders (except for tremor) or additional neurological or medical features. Diagnostic workup assesses whether there are other non-dystonic movement disorders affecting the cervical region, such as chorea, tics, or myoclonus. Dystonia coexisting with other movement disorders, not being isolated, remains outside the scope of the present article. However, the case is different for tremor that is closely associated with dystonia, particularly in the cervical region, with either regular or irregular and jerky appearance.<sup>10</sup> The separation between tremor and dystonia is sometimes challenging,<sup>64</sup> to the extent that isolated head tremor poses diagnostic difficulties in



**FIG. 1.** Isolated cervical dystonia (iCD) and its presentations are shown within the larger set of cervical dystonia. Idiopathic iCD (either focal or segmental) is distinguished from genetic and acquire iCD. Combined, paroxysmal and other CD types are outside the clinical spectrum of iCD. [Color figure can be viewed at [wileyonlinelibrary.com](http://wileyonlinelibrary.com)]

determining whether tremor is part of the iCD phenotype or a separate condition (see below).

According to etiological Axis II, diagnostic workup requires identifying the occurrence of morphological nervous system abnormalities and recognizing the etiology, whether idiopathic, genetic or acquired. Morphological abnormalities are usually assessed by routine brain imaging, which is typically normal in most iCD patients, although occasionally a focal brain lesion can cause symptoms of iCD.<sup>65</sup> Overall, the panel members felt that routine brain imaging is unnecessary in the assessment of patients with iCD in the absence of atypical features or other justification. This may change with future advances, considering that recent studies, with rapid progress in neuroimaging techniques and new methodologies, have found widespread brain structural and functional changes in patients with iCD, which are identifiable only in group averages.

Clinical practice on routine neuroimaging, however, is not homogeneous across countries and also varies according to treatment modality. Performing magnetic resonance imaging (MRI) may be difficult in the awake patient, as many will not be able to keep their head still long enough to permit good imaging. Some iCD clinical trials required normal routine MRI, others excluded patients with structural brain lesions or brain atrophy; small vessel ischemic disease was considered acceptable in a few clinical trials, but a reason for exclusion in others.<sup>13</sup> Currently there is no consensus recommendation on MRI for the diagnosis of cervical dystonia; in general, criteria on morphology are often stricter when dealing with surgical rather than medical treatments.

Lab testing may be instrumental to identify several acquired conditions, but provides little affirmative

support when unremarkable. Clinical judgement should guide the decision on diagnostic testing, based on neurological assessment. Neurophysiological studies on iCD have shown increased muscle-muscle coherence,<sup>66</sup> abnormal temporal discrimination threshold, and blink reflex recovery curve,<sup>67</sup> but their value as endophenotypic markers has not been ascertained. Attempts to identify iCD subtypes based on neurophysiology have not been successful to date.

iCD is mainly a sporadic condition, with familial occurrence in ~14% of patients,<sup>68</sup> particularly when there is head tremor.<sup>60</sup> Genetic testing is usually unrevealing in iCD, particularly when onset is in adulthood. Genetic iCD has been associated with different dystonia genes that account for only a small proportion of the familial cases.<sup>69</sup> Genes causing iCD (familial and sporadic) currently include *GNAL*, *THAP1*, *ANO3*, and less commonly other genes, with a significant degree of phenotypic heterogeneity and intrafamilial variability.<sup>70-73</sup>

Diagnosis of iCD serves different purposes when applied to clinical practice or research. Effective treatments are available for iCD (including botulinum neurotoxins, selective peripheral denervation, and stereotactic neurosurgery) and new treatments are currently being investigated. To account for both clinical and research needs, the panel included two distinct levels of diagnostic certainty reported below, which consider the relative importance of false negatives versus false positives: definite and probable. A diagnostic level of definite iCD is recommended for inclusion of patients in studies where high specificity is required. This level demands a more detailed and expensive

workup and is not recommended for standard clinical practice, where the probable level provides adequate sensitivity and sufficient specificity.

### The Problem of Isolated Head Tremor

Although dystonia and tremor are considered distinct disorders, they are closely related. In iCD, it is commonly observed that tremor is part of the overall motor phenomenology, as also observed in other dystonia types.<sup>74</sup> The expressions “dystonic tremor” and “tremor associated with dystonia” were introduced to describe cases where tremor manifests in a body part affected by dystonia versus body parts different from the ones affected by dystonia.<sup>75</sup> Although both types of tremor have been recognized in patients with iCD, early observations have also noted that horizontal (“no-no”) and less commonly vertical (“yes-yes”) tremor can occur in isolation in these patients.<sup>76</sup>

The term isolated head tremor (iHT) indicates an involuntary oscillatory movement of the head without dystonic postures, or other systemic or neurological features. According to the current classification of tremors, iHT causes oscillations of the head in yes-yes, no-no, or variable directions, with no tremor in other body parts.<sup>77</sup> The relative frequency of the different directional components, which may also coexist, has not been ascertained. iHT can persist as an isolated focal head tremor, evolve to iCD (in ~75% of cases within 5 years from onset), or to ET.<sup>78</sup> Oscillations can be regular or jerky and there is no current consensus on physiological measures that are specific or diagnostic.

Before the current tremor classification, iHT was classified as a subtype of ET,<sup>79</sup> but this posed diagnostic difficulties, as it became recognized that iHT can be a presenting feature of iCD.<sup>78,80</sup> A diagnosis of ET currently requires observing an isolated syndrome of bilateral upper limb action tremor with at least 3 years duration.<sup>77</sup> iHT is an exclusion criterion for ET unless there is upper limb tremor of sufficient duration. However, diagnostic uncertainties may arise because ~25% of patients with iCD develop postural upper limb tremor that is phenomenologically like that of patients with ET although it may differ pathophysiologically.<sup>81</sup>

It has been reported that ET-related iHT is regular and may be associated with voice tremor, whereas dystonic tremor is usually irregular and may be associated with a “null point”, a specific position of the head that, when held by the patient, alleviates abnormal movements.<sup>82,83</sup> Sensitivity and specificity analyses of these observations are still lacking. Some iHT patients may develop alleviating maneuvers even when a full iCD picture has not developed,<sup>84</sup> suggesting an initial iCD stage. However, although most patients with iCD develop a recognizable clinical picture during the first 2 to 5 years from iHT onset, some may take a longer period before the complete phenomenology develops.

The recognition of cases where iHT is in fact a forme fruste or a prodromal iCD remains challenging.<sup>85</sup> Similarly to iCD, iHT has typical onset in adulthood,<sup>80</sup> and both dystonia and tremor affect the cervical region more than any other body part.<sup>10</sup> There is a potential risk of misdiagnosis for those iHT patients who also present upper limb tremor (even if mild), matching criteria for diagnosis of ET, and later develop a recognizable iCD phenomenology. These cases require a diagnostic revision and highlight the need for biomarkers that can distinguish between these different tremor syndromes.

### Supportive Criteria for iCD

These criteria are meant to facilitate analytical decision making and increase sensitivity of the diagnostic process by recognizing characteristic iCD clinical features.

1. At least two abnormal cervical positions are recognized. Although iCD patients may manifest movements or postures in a single direction or position, more often patients demonstrate more than one abnormal cervical head/neck position (Table 1) during clinical observation. For example, some patients present rotation (torticollis or torticaput) and tilt to the opposite direction (laterocollis or laterocaput); others may present forward flexion (anterocollis or anterocaput) combined with rotation.

2. Cervical dystonic movements commonly have consistent directionality and predictability. This criterion requires observation of two key features shared by almost all dystonic movements: a directional quality that is sustained (if only for an instant), and predictability (such that the same muscle groups are repeatedly involved).<sup>86</sup> These features are also observed when tremor is present.<sup>87</sup> There are, however, a small proportion of patients who have more chaotic movements that lack sufficient predictability.

3. Presence of alleviating maneuvers.

4. Pain is improved by botulinum neurotoxin injections in overactive muscles.

5. If head tremor is present, a null point is detected.

6. Age at onset is typical (between 30 and 70 years).

Supportive criteria are summarized in Table 3. Dystonic postures, dystonic movements, and alleviating maneuvers have been discussed in the preceding section, as well as pain relief by botulinum neurotoxin treatment. Although there is no clear experimental evidence, the presence of a null point is considered a supportive criterion for dystonic head tremor in iCD. Typical age at onset is also considered a relevant supportive criterion.

### Absolute Exclusion Criteria for iCD

For all absolute exclusion criteria, the criterion is assumed to not be met because of an alternate unrelated cause. For example, unilateral cerebellar

abnormalities or pyramidal tract signs attributable to a stroke would not necessarily be exclusion criteria.

The presence of any of these features rules out iCD.

1. Unequivocal occurrence of additional movement disorders (eg, myoclonus dystonia), ataxia, unexplained pyramidal tract signs, and other neurological or systemic features. If tremor is prominently jerky the occurrence of myoclonus needs to be investigated.

2. Unexplained intellectual disability or cognitive impairment.

3. Cervical dystonia is paroxysmal (ie, characterized by sudden self-limited episodes of dystonia usually induced by a trigger with return to preexisting neurological state.)

4. Dystonia with generalized involvement.

5. Diagnosis of any iCD mimics listed in Table 2.

Absolute exclusion criteria are listed in Table 4. Figure 2 depicts the diagnostic algorithm.

### Classification of iCD

Within the larger set of cervical dystonia, the panel identified three iCD types based on analysis of clinical series and individual cases. The most common iCD presentation is idiopathic iCD (either focal or segmental), to be distinguished from genetic and acquired iCD. Differentiating focal and segmental cases of idiopathic iCD is considered of relevance for appropriately classifying iCD patients. Idiopathic iCD represent the largest group, whereas genetic and acquired iCD identify smaller patient numbers based on a specific etiology.

### Idiopathic Focal iCD

Idiopathic focal iCD is the most prevalent iCD subtype where body distribution is limited to the neck and shoulders. Several earlier publications on iCD refer to this subtype. Dystonia is isolated, meaning that there are no other movement disorders than dystonia (with or without tremor); some patients may have isolated mild postural tremor in the upper limbs, and there are

**TABLE 3** Supportive criteria for diagnosis of iCD

Supportive criteria
1. At least two abnormal cervical positions (Table 1) are recognized as part of the individual phenomenology
2. Dystonic movements are patterned, having consistent directionality and predictability
3. Effective alleviating maneuvers are observed
4. Pain is improved by botulinum neurotoxin injections in overactive muscles
5. If there is dystonic head tremor a null point is detectable
6. Age at onset is typical (between 30 and 70 years)

Abbreviation: iCD, isolated cervical dystonia.

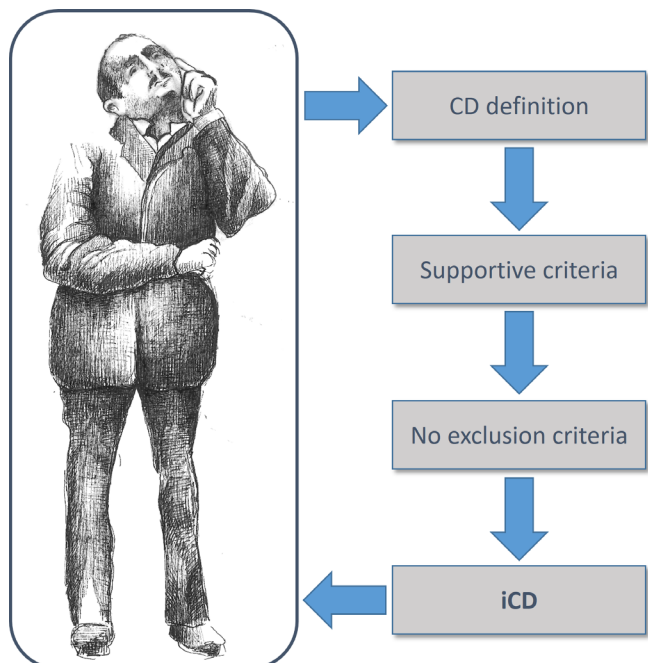
no additional neurological features except for recognized non-motor features.<sup>88,89</sup> Etiology is idiopathic; genetic and acquired forms are listed separately. Age of onset is typically between 30 and 70 years, on average around 41 years, with onset above 35 years in most patients.<sup>30,35</sup> Treatment with botulinum neurotoxin injections is considered a first line therapy.<sup>90,91</sup> If left untreated, some patients with long-standing iCD develop contractures resulting in limitation of range of neck movement.

The motor features combine variably in different patients to constitute a pleomorphic phenomenology<sup>92</sup>: some patients have head tremor, others have a predominance of irregular head jerks or postures.<sup>76</sup> Idiopathic iCD characteristically presents with pain and effective

**TABLE 4** Exclusion criteria for diagnosis of iCD

Exclusion criteria
1. Occurrence of additional movement disorders, ataxia, unexplained pyramidal tract signs, other neurological or systemic features
2. Unexplained cognitive impairment
3. Dystonia is paroxysmal
4. Dystonia is generalized
5. Conditions listed in Table 2

Abbreviation: iCD, isolated cervical dystonia.



**FIG. 2** Diagnostic flowchart for isolated cervical dystonia (iCD). Diagnosis is based on recognition of the descriptive feature of cervical dystonia (CD), the presence of supportive criteria, and absence of exclusion criteria. [Color figure can be viewed at [wileyonlinelibrary.com](http://wileyonlinelibrary.com)]

alleviating maneuvers.<sup>28,36,58</sup> There are two diagnostic levels.

For definite idiopathic focal iCD the following criteria are required.

- Clinical presentation consistent with the definition of cervical dystonia.
- No additional movement disorders, such as tics, myoclonus, ataxia, and parkinsonism and no other unexplained neurological features except for tremor and non-motor features of iCD.
- Supportive criteria 1 and 2 are both present (Table 3).
- At least two supportive criteria from 3 to 6 are present (Table 3).
- Exclusion criteria not present (Table 4).
- Acquired dystonia is excluded based on expert clinical judgement, imaging, and appropriate phenomenology-based workup.
- Criteria for genetic iCD are not met.

For probable idiopathic focal iCD the following criteria are required.

- Clinical presentation consistent with the definition of cervical dystonia.
- No additional movement disorders, such as tics, myoclonus, parkinsonism, etc., and no other unexplained neurological features except for tremor and non-motor features of iCD.
- At least one of supportive criteria from 1 to 2 is present (Table 3).
- At least one supportive criterion from 3 to 6 is present (Table 3).
- Exclusion criteria not present (Table 4).
- Acquired dystonia is excluded based on clinical judgement.
- Criteria for genetic iCD are not met.

### Idiopathic Segmental iCD

Idiopathic segmental iCD shares the same features of focal iCD with a segmental distribution, most commonly involving the upper limbs, the larynx or the cranial region. Progression from focal to segmental iCD occurs only in a proportion of focal iCD patients. If there is such progression, the patient's classification needs being relabeled to segmental even if the neck or shoulder remain the most severely affected regions.<sup>8</sup>

The same diagnostic levels of focal iCD are applied to segmental iCD: definite and probable. Genetic and acquired forms are listed separately.

### Genetic iCD

Families have been reported where affected members displayed a typical iCD phenotype,<sup>93,94</sup> and some gene variants have been considered pathogenic for an iCD phenotype. These discoveries led to reclassify as genetic

a minority of iCD cases originally considered idiopathic.<sup>68</sup> Onset is on average earlier than for idiopathic iCD, often in childhood or adolescence. Genetic forms of iCD are typically either familial autosomal dominant or sporadic, resulting from de novo gene variants. Less commonly other gene defects can show a similar phenomenology, at least for some time during the disease course. Variants in *THAP1* and *ANO3* commonly cause segmental cranio-cervical dystonia, whereas patients with heterozygous *GNAL* variants typically exhibit an adult-onset focal cervical, laryngeal, or segmental dystonia. However, focal iCD has been described for each of these genes.

Although rarely observed in currently known dystonia genes, the iCD phenotype may additionally be observed in future genetic studies. Identification of genetic iCD cases is particularly valuable for research purposes; recognizing these cases will be useful for studies testing gene-specific treatments. It must be considered that the low penetrance of dystonia genes will influence the negative predictive value of the absence of a family history of dystonia. The panel agreed to a broad inclusion under this heading of cases with pathogenic gene variants as well as of cases with a consistent familial occurrence. Identification of these cases will naturally depend on accurate history information and access to adequate diagnostic facilities.

For genetic iCD the following criteria are required.

- Clinical phenotype consistent with the definition of cervical dystonia.
- No additional movement disorders, such as tics, myoclonus, ataxia, parkinsonism, etc., and no other unexplained neurological features except for tremor and non-motor features of iCD.
- Exclusion criteria not present (Table 4).
- There is carrier status for a known recurrent pathogenic gene variant causing isolated dystonia.
- Acquired dystonia is excluded based on clinical judgement and appropriate assessments.

### Acquired iCD

Although on occasion patients with tardive dystonia may display a picture of iCD, posing a difficulty in differential diagnosis,<sup>95,96</sup> the presence of typical iCD phenomenology is uncommon in patients with structural brain lesions.<sup>97,98</sup> Single case reports indicate that acquired iCD can affect any age and be caused by lesions of the brain, posterior fossa structures, as well as spinal cord and surrounding neck structures. This condition is also commonly observed in children. A meta-analysis showed that in 39% of central nervous system tumors exhibiting signs of cervical dystonia, this presented as iCD.<sup>99</sup>

In acquired iCD extracervical involvement is common and often there is a unique abnormal head position,

typically in retrocollis for tardive cases<sup>100</sup> or in torticollis for structural abnormalities, particularly in children.<sup>101</sup>

For acquired iCD the following criteria are required.

- Clinical phenotype consistent with the definition of cervical dystonia.
- No additional movement disorders, such as tics, myoclonus, ataxia, parkinsonism, etc., and no other neurological features except for tremor and non-motor features of iC
- Exclusion criteria not present (Table 4)
- Acquired dystonia is suggested by history or demonstrated by diagnostic workup.

## Conclusions and Outlook

This document provides a systematic review of clinical presentations of iCD and proposes uniform terminology and key diagnostic criteria based on a consensus of movement disorder experts. The aim is not to accommodate all cervical dystonia types, rather to identify and classify a common clinical presentation, and facilitate clinical practice and research. The term iCD stands for a specific cervical dystonia type that historically has been consistently recognized and originally named torticollis, a term still retained in Medline subject headings. The term torticollis currently identifies an iCD posture as well as few cervical dystonia mimics of pediatric age. We provide here a modern definition of cervical dystonia, and diagnostic and classification criteria for iCD. Careful history taking and detailed clinical examination are essential for the diagnosis.

The proposed criteria are aimed to be broad to reflect the phenotypic heterogeneity of iCD, with a goal of accurately identifying as many individuals with the condition as possible. The most common presentation, idiopathic iCD has two diagnostic grades, indicating the number of observed supportive features, and is differentiated from genetic and acquired iCD, as well as from other cervical dystonia types and mimics. The identification of iCD subtypes may facilitate a more consistent approach to clinical practice as well as research. Although genetic and acquired forms will represent a minority of iCD cases, their recognition is considered useful particularly for research purposes. However, sensitivity and specificity need to be assessed, and the respective diagnostic and classification values need to be more precisely defined for practice and research.

This reappraisal of the general dystonia criteria is focused on the most prevalent dystonia type. Similar to the general dystonia criteria, methodology was based on expert consensus and clinical observation, as no gold standards are available for the diagnosis of cervical dystonia. The terminology introduced here conforms to the general dystonia classification and

implements Axis I and II criteria introduced therein. iCD is defined based on clinical characteristics (Axis I) and subclassified, according to etiology (Axis II), as idiopathic, genetic, or acquired. Patients who do not match the clinical features of iCD will fall into the broader category of cervical dystonia. The definitions introduced here are aimed at providing unequivocal language usage, thereby facilitating exchange between clinicians, researchers, and other health professionals. Rating tools used for cervical dystonia may be reassessed for clinimetric properties in patients selected according to these criteria. This effort may contribute to improve the design and implementation of future clinical studies on iCD, including research into pathophysiology and experimental therapeutics. ■

**Acknowledgment:** Dr. Tiziana De Santis kindly penciled the image depicted in Fig. 2. Open Access Funding provided by Università Cattolica del Sacro Cuore within the CRUI-CARE Agreement.

## Data Availability Statement

The data that support the findings of this study are available in PubMed at <https://pubmed.ncbi.nlm.nih.gov/> and can be retrieved using the research queries reported in the article.

## References

1. Medina A, Nilles C, Martino D, Pelletier C, Pringsheim T. The prevalence of idiopathic or inherited isolated dystonia: a systematic review and meta-analysis. *Mov Disord Clin Pract* 2022;9(7):860–868.
2. Albanese A, Bhatia K, Bressman SB, et al. Phenomenology and classification of dystonia: a consensus update. *Mov Disord* 2013;28(7):863–873.
3. Albanese A. How many Dystonias? Clinical evidence. *Front Neurol* 2017;8:18.
4. Newby RE, Thorpe DE, Kempster PA, Alty JE. A history of dystonia: ancient to modern. *Mov Disord Clin Pract* 2017;4(4):478–485.
5. Bressman SB, Warner TT, Almasy L, et al. Exclusion of the DYT1 locus in familial torticollis. *Ann Neurol* 1996;40(4):681–684.
6. Lekhel H, Popov K, Anastasopoulos D, et al. Postural responses to vibration of neck muscles in patients with idiopathic torticollis. *Brain* 1997;120(Pt 4):583–591.
7. Sasikumar S, Albanese A, Krauss JK, Fasano A. Implementation of the current dystonia classification from 2013 to 2018. *Mov Disord Clin Pract* 2019;6(3):250–253.
8. Kilic-Berkmen G, Pirio Richardson S, Perlmutter JS, et al. Current guidelines for classifying and diagnosing cervical dystonia: empirical evidence and recommendations. *Mov Disord Clin Pract* 2022;9(2):183–190.
9. Pandey S, Jost WH. Classification and diagnosis of cervical dystonia: revived call for consensus. *Mov Disord Clin Pract* 2022;9(5):717–718.
10. Shaikh AG, Beylergil SB, Scorr L, et al. Dystonia and tremor: a cross-sectional study of the dystonia coalition cohort. *Neurology* 2021;96(4):e563–e574.
11. Logroscino G, Livrea P, Analerio D, et al. Agreement among neurologists on the clinical diagnosis of dystonia at different body sites. *J Neurol Neurosurg Psychiatry* 2003;74(3):348–350.

12. Du W, Bain PG, Defazio G, et al. The conundrum of dystonia in essential tremor patients: how does one classify these cases? *Tremor Other Hyperkinet Mov* 2022;12:15.
13. Vergallo A, Cocco A, De Santis T, Lalli S, Albanese A. Eligibility criteria in clinical trials for cervical dystonia. *Parkinsonism Relat Disord* 2022;104:110–114.
14. Waggoner J, Carline JD, Durning SJ. Is there a consensus on consensus methodology? Descriptions and recommendations for future consensus research. *Acad Med* 2016;91(5):663–668.
15. LaHue SC, Albers K, Goldman S, et al. Cervical dystonia incidence and diagnostic delay in a multiethnic population. *Mov Disord* 2020;35(3):450–456.
16. Defazio G, Jankovic J, Giel JL, Papapetropoulos S. Descriptive epidemiology of cervical dystonia. *Tremor Other Hyperkinet Mov* 2013;3:1–8.
17. Skogseid IM, Kerty E. The course of cervical dystonia and patient satisfaction with long-term botulinum toxin a treatment. *Eur J Neurol* 2005;12(3):163–170.
18. Reichel G. Cervical dystonia: a new phenomenological classification for botulinum toxin therapy. *Basal Ganglia* 2011;1(1):5–12.
19. Obeso JA, Rothwell JC, Lang AE, Marsden CD. Myoclonic dystonia. *Neurology* 1983;33(7):825–830.
20. Jankovic J. Tourette's syndrome. *N Engl J Med* 2001;345(16):1184–1192.
21. Foncke EMJ, Tijssen MAJ. Myoclonus-dystonia/essential myoclonus. In: Kompoliti K, Verhagen Metman L, eds. *Encyclopedia of Movement Disorders*. Amsterdam: Academic Press; 2010:248–251.
22. Erro R, Martino D, Ganos C, Damasio J, Batla A, Bhatia KP. Adult-onset primary dystonic tics: a different entity? *Mov Disord Clin Pract* 2014;1(1):62–66.
23. van der Veen S, Zutt R, Klein C, et al. Nomenclature of genetically determined myoclonus syndromes: recommendations of the International Parkinson and Movement Disorder Society task force. *Mov Disord* 2019;34(11):1602–1613.
24. Patel N, Hanfelt J, Marsh L, Jankovic J, members of the Dystonia C. Alleviating manoeuvres (sensory tricks) in cervical dystonia. *J Neurol Neurosurg Psychiatry* 2014;85(8):882–884.
25. Poisson A, Krack P, Thobois S, et al. History of the 'geste antagoniste' sign in cervical dystonia. *J Neurol* 2012;259(8):1580–1584.
26. Schramm A, Reiners K, Naumann M. Complex mechanisms of sensory tricks in cervical dystonia. *Mov Disord* 2004;19(4):452–458.
27. Ramos VF, Karp BI, Hallett M. Tricks in dystonia: ordering the complexity. *J Neurol Neurosurg Psychiatry* 2014;85(9):987–993.
28. Defazio G, Albanese A, Pellicciari R, et al. Expert recommendations for diagnosing cervical, oromandibular, and limb dystonia. *Neurol Sci* 2019;40(1):89–95.
29. Cisneros E, Vu JP, Lee HY, et al. Does raising the arms modify head tremor severity in cervical dystonia? *Tremor Other Hyperkinet Mov* 2021;11:21.
30. Chan J, Brin MF, Fahn S. Idiopathic cervical dystonia: clinical characteristics. *Mov Disord* 1991;6(2):119–126.
31. Kutvonen O, Dastidar P, Nurmikko T. Pain in spasmodic torticollis. *Pain* 1997;69(3):279–286.
32. Charles PD, Adler CH, Stacy M, et al. Cervical dystonia and pain: characteristics and treatment patterns from CD PROBE (cervical dystonia patient registry for observation of OnabotulinumtoxinA efficacy). *J Neurol* 2014;261(7):1309–1319.
33. Avenali M, De Icco R, Tinazzi M, et al. Pain in focal dystonias—a focused review to address an important component of the disease. *Parkinsonism Relat Disord* 2018;54:17–24.
34. Muller J, Kemmler G, Wissel J, et al. The impact of blepharospasm and cervical dystonia on health-related quality of life and depression. *J Neurol* 2002;249(7):842–846.
35. Stacy M. Epidemiology, clinical presentation, and diagnosis of cervical dystonia. *Neurol Clin* 2008;26(Suppl 1):23–42.
36. Rosales RL, Cuffe L, Regnault B, Trosch RM. Pain in cervical dystonia: mechanisms, assessment and treatment. *Expert Rev Neurother* 2021;21(10):1125–1134.
37. Riley DE, Lang AE. Pain in Gilles de la Tourette syndrome and related tic disorders. *Can J Neurol Sci* 1989;16(4):439–441.
38. Moraru E, Schnider P, Wimmer A, et al. Relation between depression and anxiety in dystonic patients: implications for clinical management. *Depress Anxiety* 2002;16(3):100–103.
39. Rinnerthaler M, Mueller J, Weichbold V, Wenning GK, Poewe W. Social stigmatization in patients with cranial and cervical dystonia. *Mov Disord* 2006;21(10):1636–1640.
40. Fabbrini G, Berardelli I, Moretti G, et al. Psychiatric disorders in adult-onset focal dystonia: a case-control study. *Mov Disord* 2010;25(4):459–465.
41. Yang J, Shao N, Song W, et al. Nonmotor symptoms in primary adult-onset cervical dystonia and blepharospasm. *Brain Behav* 2017;7(2):e00592.
42. Avanzino L, Martino D, Marchese R, et al. Quality of sleep in primary focal dystonia: a case-control study. *Eur J Neurol* 2010;17(4):576–581.
43. Hallett M. Neurophysiology of dystonia: the role of inhibition. *Neurobiol Dis* 2011;42(2):177–184.
44. Quartarone A, Hallett M. Emerging concepts in the physiological basis of dystonia. *Mov Disord* 2013;28(7):958–967.
45. Groen JL, Simon-Sanchez J, Ritz K, et al. Cervical dystonia and genetic common variation in the dopamine pathway. *Parkinsonism Relat Disord* 2013;19(3):346–349.
46. Simonyan K, Cho H, Hamzehei Sichani A, Rubien-Thomas E, Hallett M. The direct basal ganglia pathway is hyperfunctional in focal dystonia. *Brain* 2017;140(12):3179–3190.
47. Mente K, Edwards NA, Urbano D, et al. Pedunculopontine nucleus cholinergic deficiency in cervical dystonia. *Mov Disord* 2018;33(5):827–834.
48. Jinnah HA, Neychev V, Hess EJ. The anatomical basis for dystonia: the motor network model. *Tremor Other Hyperkinet Mov* 2017;7:506.
49. Hallett M, de Haan W, Deco G, et al. Human brain connectivity: clinical applications for clinical neurophysiology. *Clin Neurophysiol* 2020;131(7):1621–1651.
50. Semenova U, Medvednik R, Popov V, Jinnah HA, Shaikh AG, Sedov A. Neuronal activity of Pallidal versus cerebellar receiving thalamus in patients with cervical dystonia. *Cerebellum* 2021;20(2):151–159.
51. Munchau A, Corna S, Gresty MA, et al. Abnormal interaction between vestibular and voluntary head control in patients with spasmodic torticollis. *Brain* 2001;124(Pt 1):47–59.
52. Shaikh AG, Wong AL, Zee DS, Jinnah HA. Keeping your head on target. *J Neurosci* 2013;33(27):11281–11295.
53. Shaikh AG, Zee DS, Crawford JD, Jinnah HA. Cervical dystonia: a neural integrator disorder. *Brain* 2016;139(Pt 10):2590–2599.
54. Cho HJ, Waugh R, Wu T, et al. Role of supplementary motor area in cervical dystonia and sensory tricks. *Sci Rep* 2022;12(1):21206.
55. Weiss EM, Hershey T, Karimi M, et al. Relative risk of spread of symptoms among the focal onset primary dystonias. *Mov Disord* 2006;21(8):1175–1181.
56. Martino D, Berardelli A, Abbruzzese G, et al. Age at onset and symptom spread in primary adult-onset blepharospasm and cervical dystonia. *Mov Disord* 2012;27(11):1447–1450.
57. Berman BD, Groth CL, Sillau SH, et al. Risk of spread in adult-onset isolated focal dystonia: a prospective international cohort study. *J Neurol Neurosurg Psychiatry* 2020;91(3):314–320.
58. Norris SA, Jinnah HA, Espay AJ, et al. Clinical and demographic characteristics related to onset site and spread of cervical dystonia. *Mov Disord* 2016;31(12):1874–1882.
59. Pal PK, Samii A, Schulzer M, Mak E, Tsui JK. Head tremor in cervical dystonia. *Can J Neurol Sci* 2000;27(2):137–142.

60. Rubio-Agusti I, Parees I, Kojovic M, et al. Tremulous cervical dystonia is likely to be familial: clinical characteristics of a large cohort. *Parkinsonism Relat Disord* 2013;19(6):634–638.
61. Jahanshahi M, Marion MH, Marsden CD. Natural history of adult-onset idiopathic torticollis. *Arch Neurol* 1990;47(5):548–552.
62. Van Zandijcke M. Cervical dystonia (spasmodic torticollis). Some aspects of the natural history. *Acta Neurol Belg* 1995;95(4):210–215.
63. Albanese A, Di Giovanni M, Lalli S. Dystonia: diagnosis and management. *Eur J Neurol* 2019;26(1):5–17.
64. Defazio G, Conte A, Gigante AF, Fabbrini G, Berardelli A. Is tremor in dystonia a phenotypic feature of dystonia? *Neurology* 2015;84(10):1053–1059.
65. Corp DT, Joutsa J, Darby RR, et al. Network localization of cervical dystonia based on causal brain lesions. *Brain* 2019;142(6):1660–1674.
66. Nijmeijer SW, de Bruijn E, Forbes PA, et al. EMG coherence and spectral analysis in cervical dystonia: discriminative tools to identify dystonic muscles? *J Neurol Sci* 2014;347(1–2):167–173.
67. Junker J, Paulus T, Brandt V, et al. Temporal discrimination threshold and blink reflex recovery cycle in cervical dystonia - two sides of the same coin? *Parkinsonism Relat Disord* 2019;68:4–7.
68. LeDoux MS, Vemula SR, Xiao J, et al. Clinical and genetic features of cervical dystonia in a large multicenter cohort. *Neurol Genet* 2016;2(3):e69.
69. Sun YV, Li C, Hui Q, et al. A multi-center genome-wide association study of cervical dystonia. *Mov Disord* 2021;36(12):2795–2801.
70. Xiromerisiou G, Houlden H, Scarmeas N, et al. THAP1 mutations and dystonia phenotypes: genotype phenotype correlations. *Mov Disord* 2012;27(10):1290–1294.
71. Charlesworth G, Plagnol V, Holmstrom KM, et al. Mutations in ANO3 cause dominant craniocervical dystonia: ion channel implicated in pathogenesis. *Am J Hum Genet* 2012;91(6):1041–1050.
72. Fuchs T, Saunders-Pullman R, Masuho I, et al. Mutations in GNAL cause primary torsion dystonia. *Nat Genet* 2013;45(1):88–92.
73. Kumar KR, Lohmann K, Masuho I, et al. Mutations in GNAL: a novel cause of craniocervical dystonia. *JAMA Neurol* 2014;71(4):490–494.
74. Hvizdosova L, Nevrlý M, Otruba P, Hlustik P, Kanovsky P, Zapletalova J. The prevalence of dystonic tremor and tremor associated with dystonia in patients with cervical dystonia. *Sci Rep* 2020;10(1):1436.
75. Deuschl G. Dystonic tremor. *Rev Neurol* 2003;159(10):900–905.
76. Rivest J, Marsden CD. Trunk and head tremor as isolated manifestations of dystonia. *Mov Disord* 1990;5(1):60–65.
77. Bhatia KP, Bain P, Bajaj N, et al. Consensus statement on the classification of tremors. From the task force on tremor of the International Parkinson and Movement Disorder Society. *Mov Disord* 2018;33(1):75–87.
78. Ferrazzano G, Belvisi D, De Bartolo MI, et al. Longitudinal evaluation of patients with isolated head tremor. *Parkinsonism Relat Disord* 2022;94:10–12.
79. Deuschl G, Bain P, Brin M. Consensus statement of the Movement Disorder Society on tremor. Ad hoc scientific committee. *Mov Disord* 1998;13(Suppl 3):2–23.
80. Louis ED, Dogu O. Isolated head tremor: part of the clinical spectrum of essential tremor? Data from population-based and clinic-based case samples. *Mov Disord* 2009;24(15):2281–2285.
81. Munchau A, Schrag A, Chuang C, et al. Arm tremor in cervical dystonia differs from essential tremor and can be classified by onset age and spread of symptoms. *Brain* 2001;124(Pt 9):1765–1776.
82. Lenka A, Jankovic J. Tremor syndromes: an updated review. *Front Neurol* 2021;12:684835.
83. Vu JP, Cisneros E, Zhao J, et al. From null to midline: changes in head posture do not predictably change head tremor in cervical dystonia. *Dystonia* 2022;1:1–6.
84. Masuhr F, Wissel J, Muller J, Scholz U, Poewe W. Quantification of sensory trick impact on tremor amplitude and frequency in 60 patients with head tremor. *Mov Disord* 2000;15(5):960–964.
85. Albanese A, Del Sorbo F. Dystonia and tremor: the clinical syndromes with isolated tremor. *Tremor Other Hyperkinet Mov* 2016;6:319.
86. Bressman SB. Dystonia update. *Clin Neuropharmacol* 2000;23(5):239–251.
87. Albanese A, Lalli S. Is this dystonia? *Mov Disord* 2009;24(12):1725–1731.
88. Stamelou M, Edwards MJ, Hallett M, Bhatia KP. The non-motor syndrome of primary dystonia: clinical and pathophysiological implications. *Brain* 2012;135(Pt 6):1668–1681.
89. Naik AG, Ezana D, Cannard G, et al. Exploring the presence of multiple abnormal non-motor features in patients with cervical dystonia. *J Clin Neurosci* 2021;94:315–320.
90. Albanese A, Asmus F, Bhatia KP, et al. EFNS guidelines on diagnosis and treatment of primary dystonias. *Eur J Neurol* 2011;18(1):5–18.
91. Simpson DM, Hallett M, Ashman EJ, et al. Practice guideline update summary: Botulinum neurotoxin for the treatment of blepharospasm, cervical dystonia, adult spasticity, and headache: report of the guideline development Subcommittee of the American Academy of neurology. *Neurology* 2016;86(19):1818–1826.
92. Munchau A, Filipovic SR, Oester-Barkey A, Quinn NP, Rothwell JC, Bhatia KP. Spontaneously changing muscular activation pattern in patients with cervical dystonia. *Mov Disord* 2001;16(6):1091–1097.
93. Uitti RJ, Maraganore DM. Adult onset familial cervical dystonia: report of a family including monozygotic twins. *Mov Disord* 1993;8(4):489–494.
94. Bentivoglio AR, Ialongo T, Contarino MF, Valente EM, Albanese A. Phenotypic characterization of DYT13 primary torsion dystonia. *Mov Disord* 2004;19(2):200–206.
95. Burke RE, Fahn S, Jankovic J, et al. Tardive dystonia: late-onset and persistent dystonia caused by antipsychotic drugs. *Neurology* 1982;32(12):1335–1346.
96. Kang UJ, Burke RE, Fahn S. Natural history and treatment of tardive dystonia. *Mov Disord* 1986;1(3):193–208.
97. Zeman W, Whitlock CC. Symptomatic dystonias. In: Vinken PJ, Bruyn GW, eds. *Diseases of the Basal Ganglia*. Amsterdam: North Holland; 1968:544–566.
98. Kostic VS, Stojanovic-Svetel M, Kacar A. Symptomatic dystonias associated with structural brain lesions: report of 16 cases. *Can J Neurol Sci* 1996;23(1):53–56.
99. Baklizi N, Raswoli M, Burges M, Moreira DC, Qaddoumi I. Torticollis as a presenting symptom of pediatric CNS tumors: a systematic review. *Semin Oncol* 2022;49(5):419–425.
100. Molho ES, Feustel PJ, Factor SA. Clinical comparison of tardive and idiopathic cervical dystonia. *Mov Disord* 1998;13(3):486–489.
101. Per H, Canpolat M, Tunturk A, et al. Different etiologies of acquired torticollis in childhood. *Childs Nerv Syst* 2014;30(3):431–440.

## Supporting Data

Additional Supporting Information may be found in the online version of this article at the publisher's web-site.