




# Allergic contact dermatitis to clostridiopeptidase A with a nummular eczema-like spread

Caterina Foti  | Gianluca Caliano | Silvia Mazzotta | Fabrizio Guarneri  | Paolo Romita 

<sup>1</sup>Department of Biomedical Science and Human Oncology, Dermatological Clinic, University of Bari, Bari, Italy

<sup>2</sup>Department of Clinical and Experimental Medicine, University of Messina, Messina, Italy

## Correspondence

Professor Caterina Foti, Unit of Dermatology, Department of Biomedical Science and Human Oncology, University of Bari, Policlinico, Piazza Giulio Cesare, 11 I-70124 Bari, Italy.

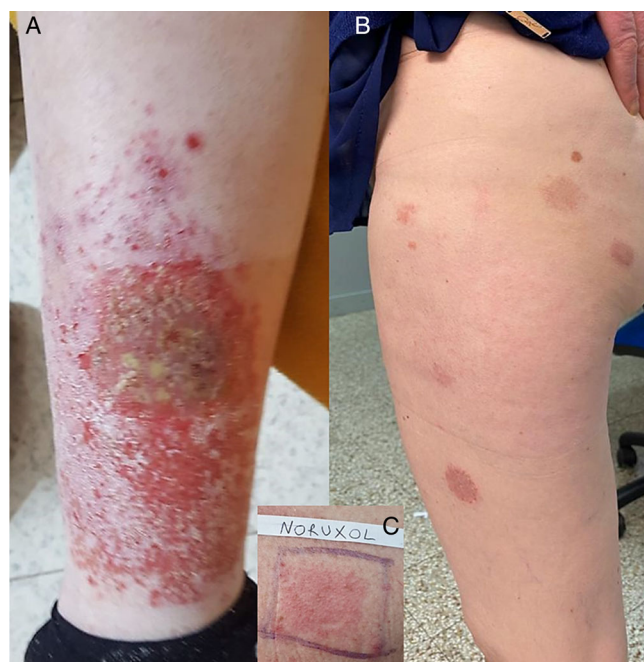Email: caterina.foti@uniba.it

**KEYWORDS:** allergic contact dermatitis, case report, chloramphenicol, clostridiopeptidase A, collagenase I, leg ulcers, nummular eczema

Topical medications used for the treatment of venous leg ulcers are a well-known cause of allergic contact dermatitis (ACD).<sup>1</sup> Among these, topical drugs containing proteolytic enzymes (used for wound debridement) are rarely involved.<sup>2,3</sup> We herein report a case of severe ACD caused by clostridiopeptidase A, also known as collagenase I.

## CASE REPORT

A nonatopic 64-year-old woman presented to our attention for the onset of a diffuse crusted eczematous dermatitis with nummular aspects (Figure 1). The patient reported that the eruption had started to appear about 2 weeks after the application of a topical ointment containing chloramphenicol 1% and clostridiopeptidase A 60 U.I. (Iruxol, Smith & Nephew GmbH, Hamburg, Germany) under occlusion with a zinc oxide bandage, prescribed by her physician to treat a venous ulcer on her left leg. The skin lesions appeared around the leg ulcer and then spread within 3 weeks to both lower limbs, the upper limbs, and trunk, with nummular eczema-like aspects. Her physician already prescribed oral therapy with amoxicillin-clavulanate (875 + 125 mg twice daily) for 6 days; however, there was no improvement of the skin lesions. Use of the topical ointment was immediately discontinued, and topical application of mometasone furoate once daily resulted in healing of the eczematous lesions in 2 weeks. Four weeks after the resolution of the dermatitis, patch tests were performed with the SIDAPA (Società Italiana di Dermatologia Allergologica Professionale e Ambientale) baseline series (FIRMADiagent, Florence, Italy), a piece of the zinc oxide bandage, and the ointment used by the patient. Patch tests were applied on the back and left under occlusion for 2 days with Haye's Test Chambers (Haye's Service B.V., Alphen aan den Rijn, The Netherlands) on Soffix tape (Artsana, Grandate, Italy). Readings were performed on day (D) 2 and D4 according to guidelines,<sup>4</sup> and showed a positive reaction to parphenylenediamine (++, past relevance) and Iruxol ointment (++). Subsequently, patch tests were performed with chloramphenicol 5% pet. and Noruxol (containing clostridiopeptidase A, liquid



**FIGURE 1** (A) Eczematous lesions around the leg ulcer and (B) nummular eczema-like spreading; (C) positive patch test to Noruxol “as is” on day 4

paraffin, and white petrolatum; Smith & Nephew GmbH, Hamburg, Germany), liquid paraffin, and white petrolatum, yielding positivity only to Noruxol (++; Figure 1). Based on these findings, we diagnosed ACD to clostridiopeptidase A. Ten healthy individuals were patch tested with Iruxol and Noruxol with negative results.

## DISCUSSION

ACD caused by topical medications is a well-known, but probably underestimated and misdiagnosed complication.<sup>5</sup> We herein reported a case of severe ACD caused by clostridiopeptidase A, a proteolytic

enzyme widely used in wound and ulcer care. While chloramphenicol is a well-known sensitizer,<sup>6</sup> clostridiopeptidase A has rarely been reported as the culprit of ACD.<sup>2,3</sup> Nummular eczema is usually a manifestation of atopic dermatitis, but contact allergy has also been demonstrated to be associated with nummular eczema-like aspects.<sup>7</sup> To our knowledge, this is the first case of ACD to clostridiopeptidase A with a nummular eczema-like spread.

We speculate that the application of the medication under occlusion could have favoured contact sensitization and lymphatic and/or hematogenous dissemination, which are proposed mechanisms for ACD spreading.<sup>8</sup>

Beyond the peculiar clinical manifestations, our case highlights that contact sensitization to topical medications containing clostridiopeptidase A, although rare, should be always borne in mind by physicians.

#### ACKNOWLEDGEMENTS

Open Access Funding provided by Universita degli Studi di Bari Aldo Moro within the CRUI-CARE Agreement. [Correction added on 25 May 2022, after first online publication: CRUI funding statement has been added.]

#### CONFLICTS OF INTEREST

All the authors have no conflict of interest to declare.

#### AUTHOR CONTRIBUTIONS

**Caterina Foti:** Conceptualization (equal); data curation (equal); supervision (equal); writing – review and editing (equal). **Gianluca Calianno:** Conceptualization (equal); data curation (equal). **Silvia Mazzotta:** Data curation (equal); formal analysis (equal). **Fabrizio Guarneri:** Data curation (equal); formal analysis (equal); supervision (equal). **Paolo Romita:** Conceptualization (equal); data curation (equal); formal analysis (equal); supervision (equal); validation (equal); writing – review and editing (equal).

#### ORCID

Caterina Foti  <https://orcid.org/0000-0001-6196-9788>

Fabrizio Guarneri  <https://orcid.org/0000-0003-0805-8496>

Paolo Romita  <https://orcid.org/0000-0002-5559-9722>

#### REFERENCES

- Raudonis T, Vankeviciute RA, Lideikaite A, Grigaityte AG, Grigaitiene J. Contact sensitization in patients with chronic leg ulcers: results of a 5-year retrospective analysis. *Adv Skin Wound Care*. 2019;32(12):558-562.
- Foti C, Conserva A, Casulli C, Scrimieri V, Pepe ML, Quaranta D. Contact dermatitis with clostridiopeptidase a contained in Noruxol ointment. *Contact Dermatitis*. 2007;56(6):361-362.
- Lisi P, Brunelli L. Extensive allergic contact dermatitis from a topical enzymatic preparation (Noruxol). *Contact Dermatitis*. 2001;45(3):186-187.
- Stingeni L, Bianchi L, Hansel K, et al. Italian guidelines in patch testing - adapted from the European Society of Contact Dermatitis (ESCD). *G Ital Dermatol Venereol*. 2019;154(3):227-253.
- Garval E, Plee J, Lesage C, Grange-Prunier A, Bernard P, Perceau G. Frequency of contact sensitization to modern dressings used to treat chronic leg ulcer. *Ann Dermatol Venereol*. 2018;145(5):339-346.
- Romita P, Stingeni L, Hansel K, et al. Allergic contact dermatitis caused by chloramphenicol with prurigo nodularis-like spreading. *Contact Dermatitis*. 2019;80(4):251-252.
- Bonamonte D, Foti C, Vestita M, Ranieri LD, Angelini G. Nummular eczema and contact allergy: a retrospective study. *Dermatitis*. 2012;23(4):153-157.
- Lachapelle JM. Allergic contact dermatitis: clinical aspects. *Rev Environ Health*. 2014;29(3):185-194.

**How to cite this article:** Foti C, Calianno G, Mazzotta S, Guarneri F, Romita P. Allergic contact dermatitis to clostridiopeptidase A with a nummular eczema-like spread. *Contact Dermatitis*. 2022;86(2):122-123. doi: 10.1111/cod.13982

# Mepolizumab for treating systemic allergic dermatitis with hypereosinophilia likely secondary to a nickel/cobalt-containing coronary artery stent

Paul Faybusovich<sup>1</sup>  | Jordan Lim<sup>2</sup> | Michael D. Ioffreda<sup>2</sup> | Taha Al-Shaikhly<sup>1</sup>

<sup>1</sup>Section of Allergy, Asthma & Immunology, Department of Medicine, Penn State College of Medicine, Hershey, Pennsylvania, USA

<sup>2</sup>Department of Dermatology, Penn State College of Medicine, Hershey, Pennsylvania, USA

#### Correspondence

Dr Paul Faybusovich, Penn State College of Medicine, 500 University Drive, PO Box 850, Hershey, PA 17033, USA.  
Email: pfaybuso@nyit.edu

**KEY WORDS:** case report, cobalt, drug-eluting stent, hypereosinophilia, interleukin 5 (IL-5), medical device, mepolizumab, nickel, systemic allergic dermatitis

Systemic allergic dermatitis (SAD) from endovascular devices is not uncommon.<sup>1</sup> We present a patient with SAD and hypereosinophilia likely

secondary to an unretrievable nickel/cobalt-containing drug-eluting coronary artery stent, who responded to anti-interleukin (IL)-5 therapy.